

XLIX Reunión anual
SOCIEDAD ESPAÑOLA
DE NEURORRADIOLÓGIA

TOLEDO
21 - 23 octubre 2021
Palacio de Congresos

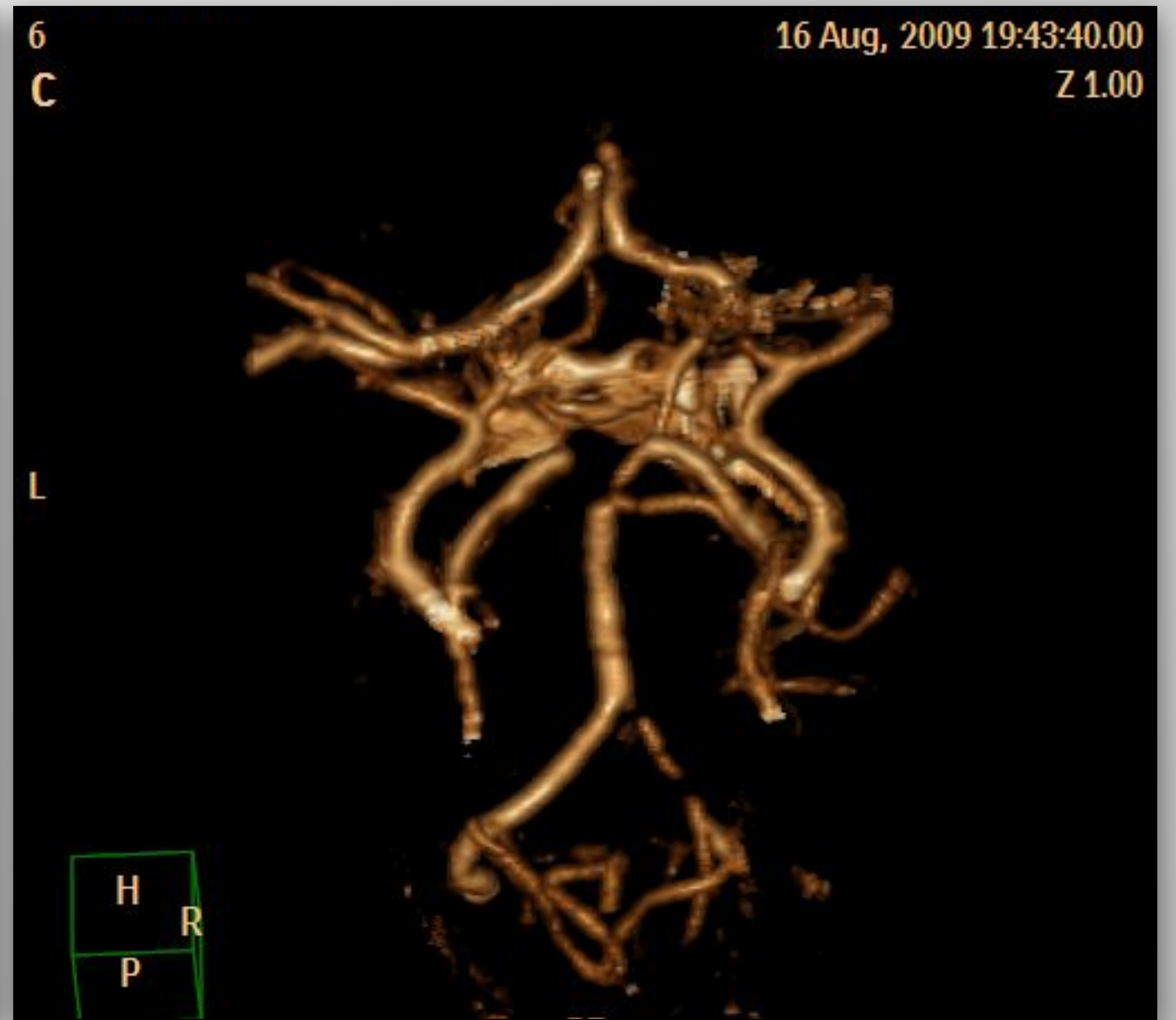
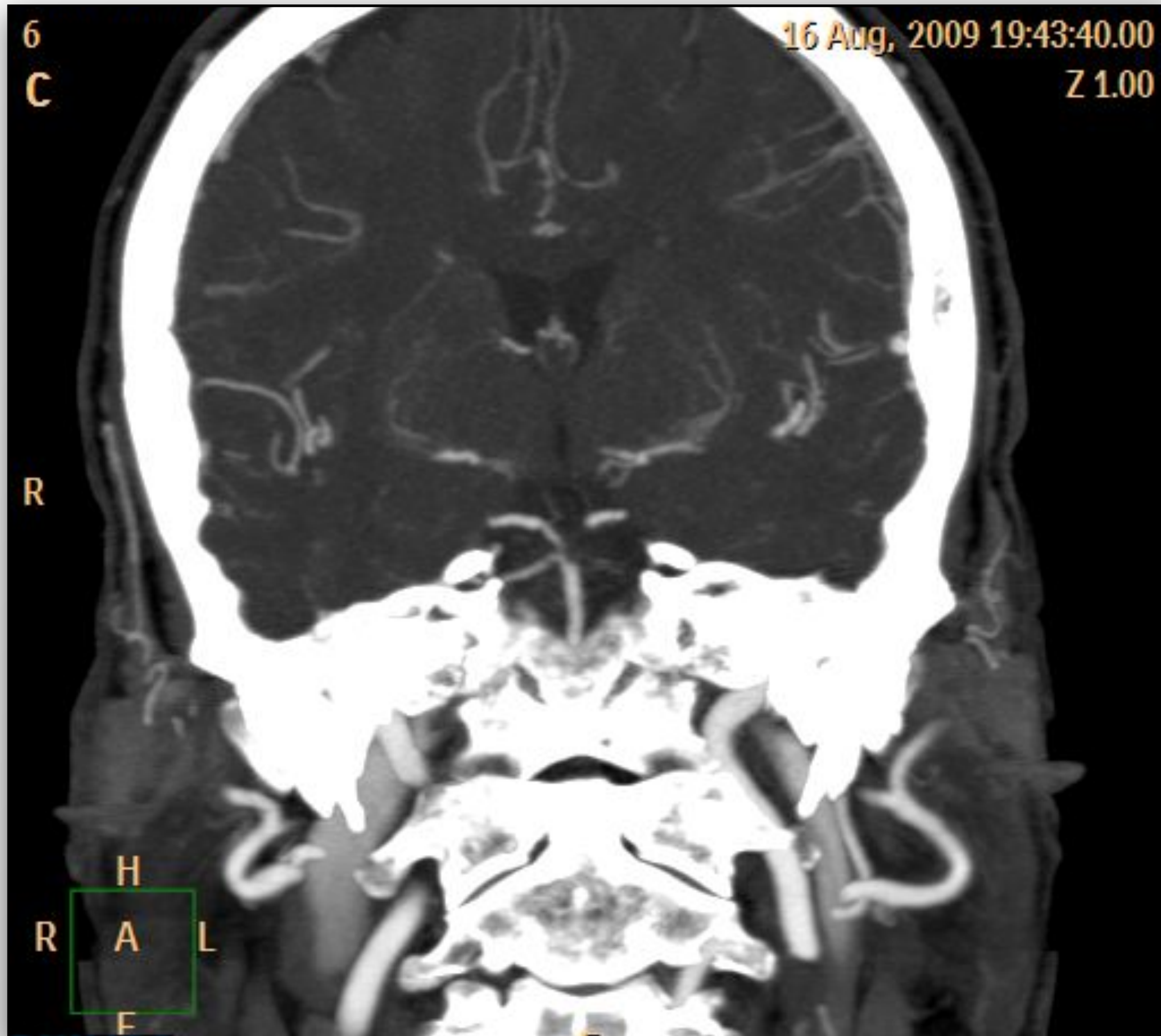


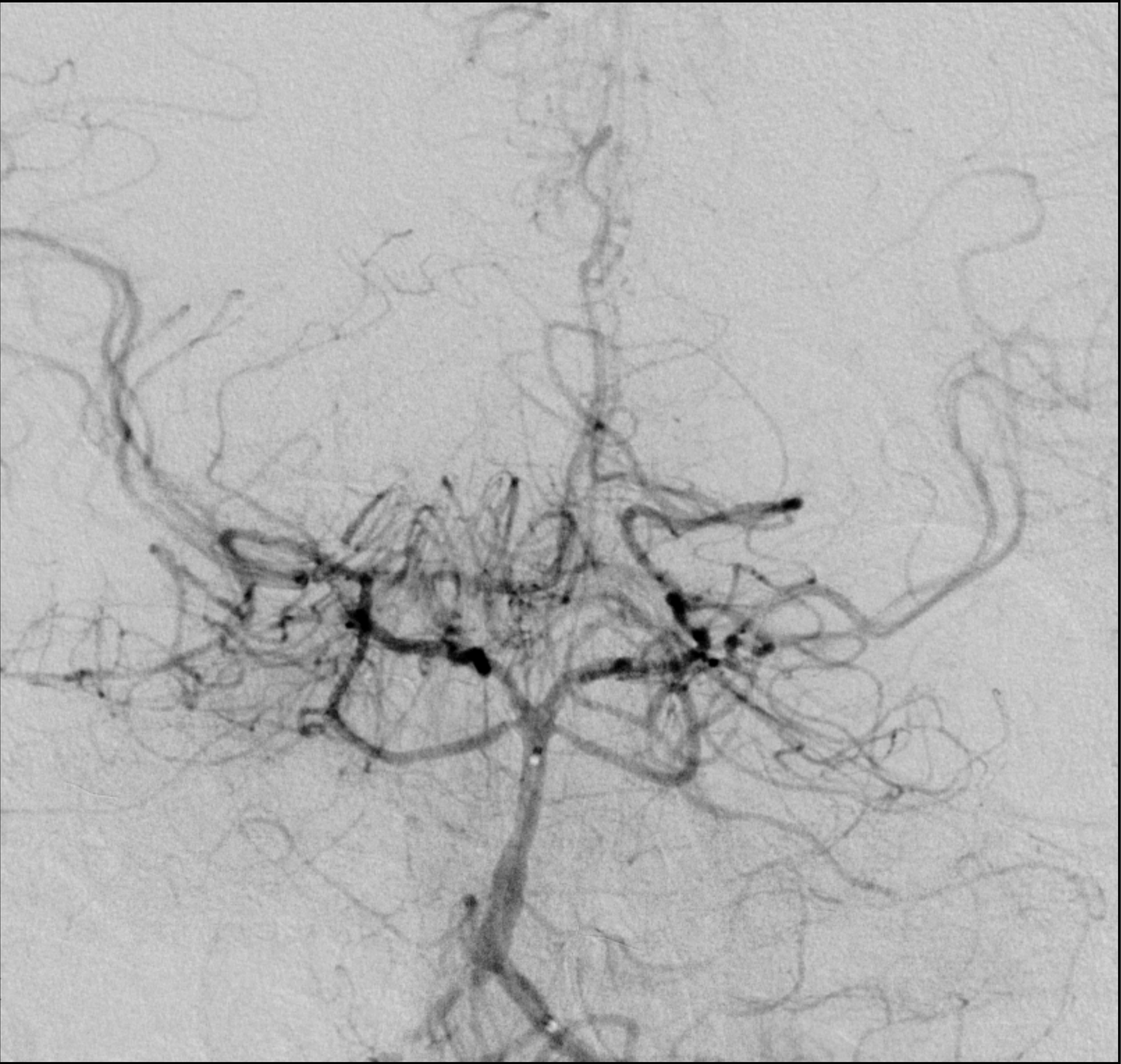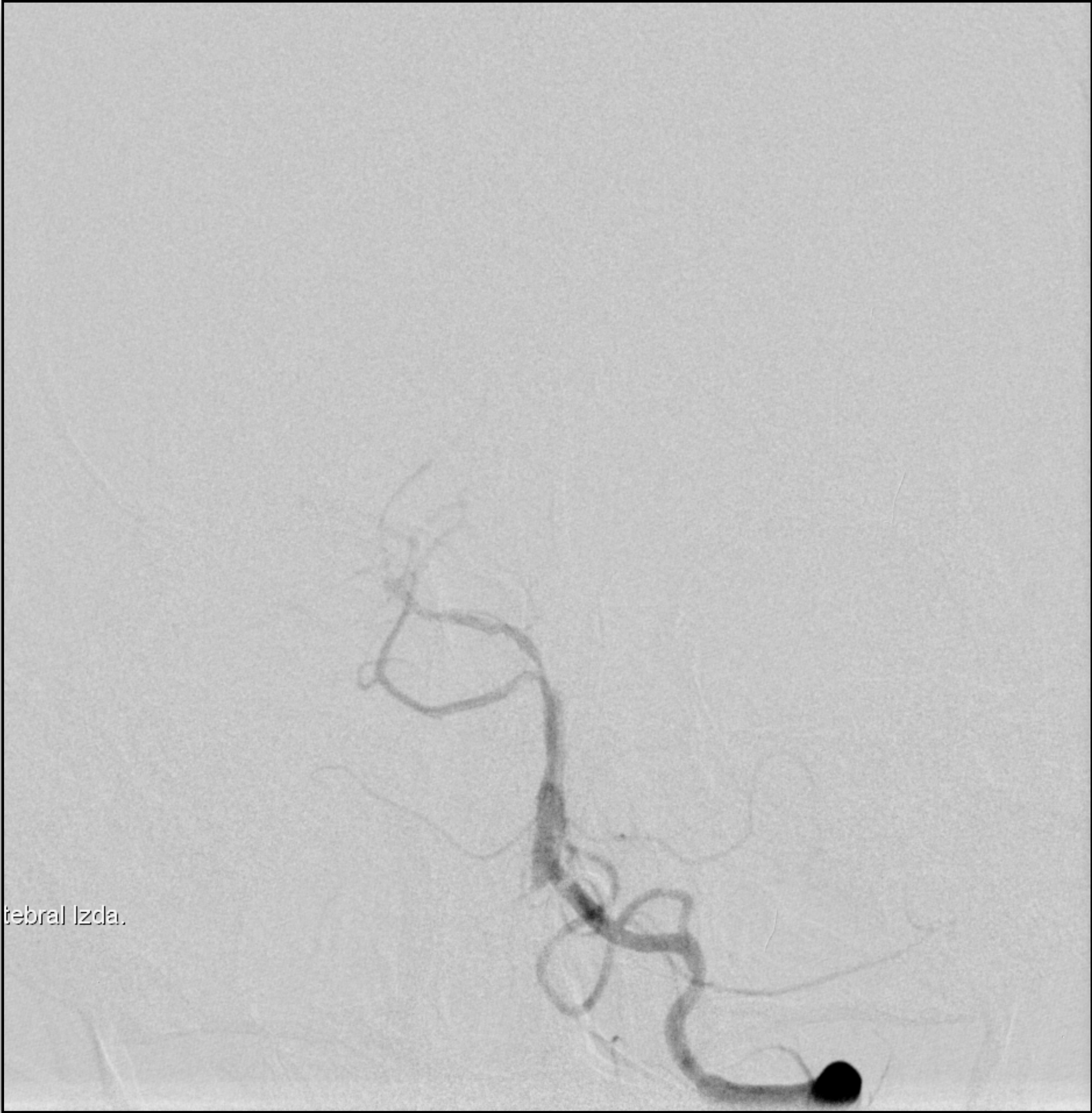Técnicas avanzadas en el tratamiento del ICTUS: Revisión de casos problema

Dr. Pedro Navia

Hospital Universitario La Paz, Madrid

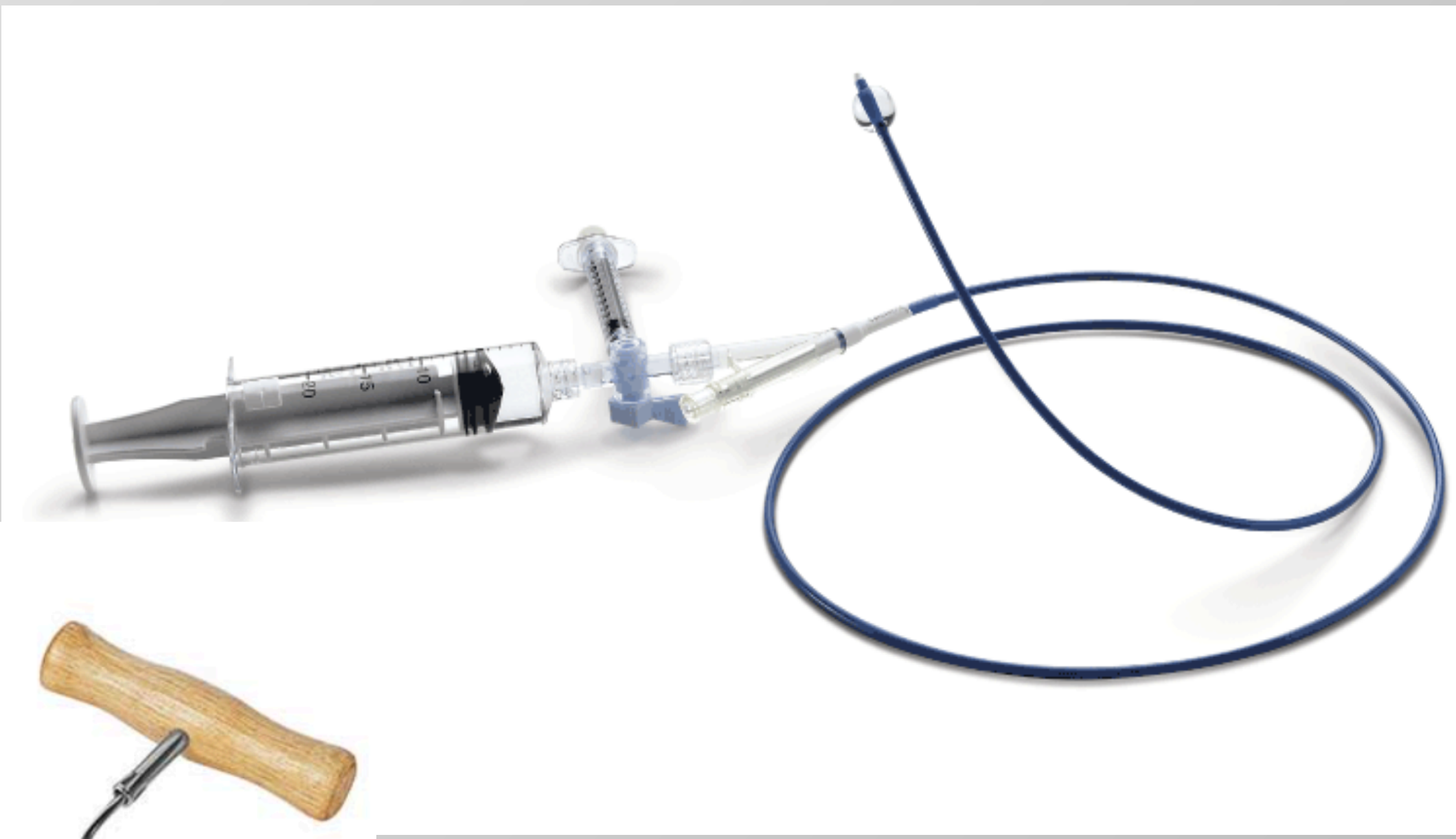








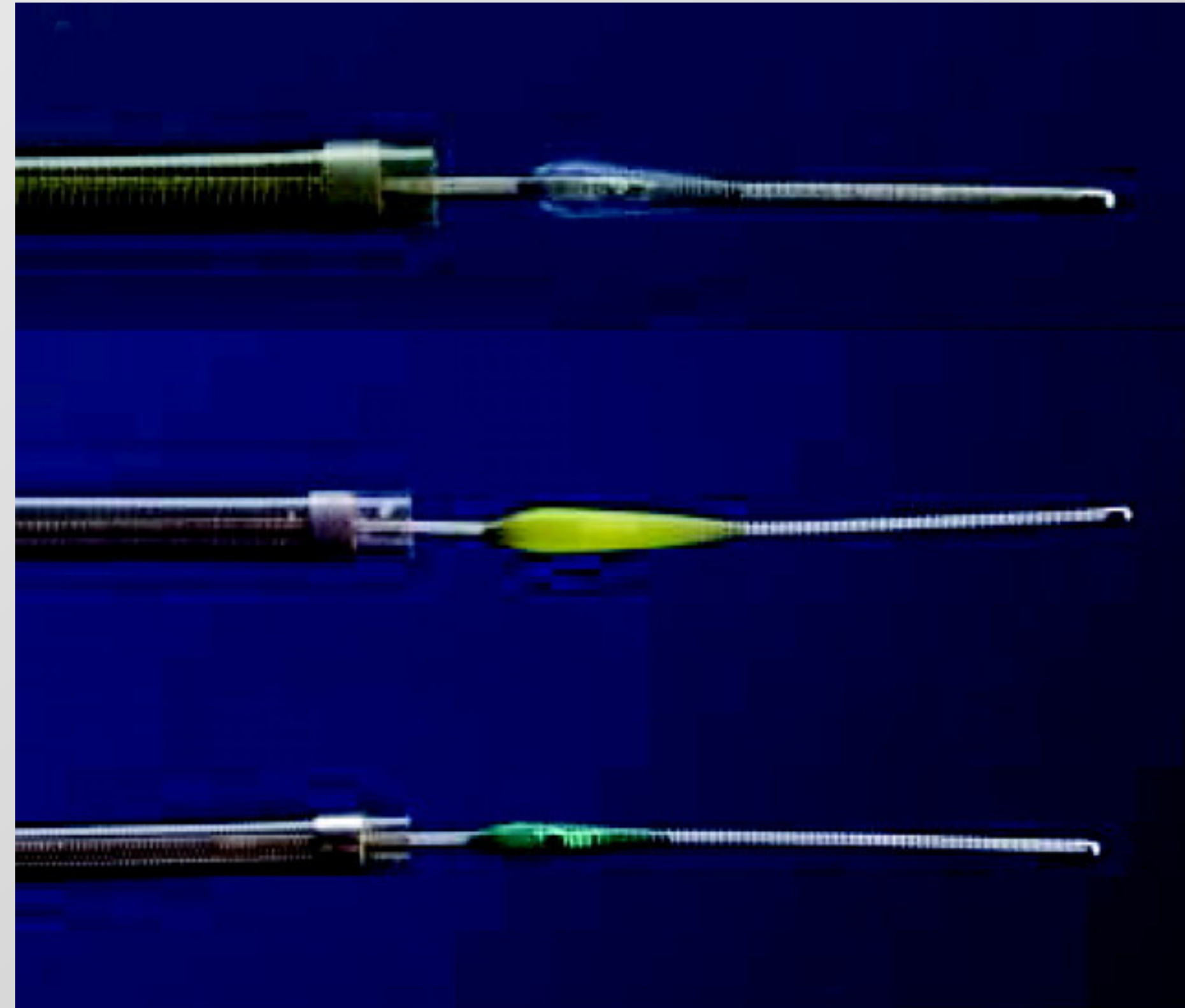corkscrew



The Penumbra Pivotal Stroke Trial

Safety and Effectiveness of a New Generation of Mechanical Devices for Clot Removal in Intracranial Large Vessel Occlusive Disease

The Penumbra Pivotal Stroke Trial Investigators



Stroke. 2009;40:2761-2768.)

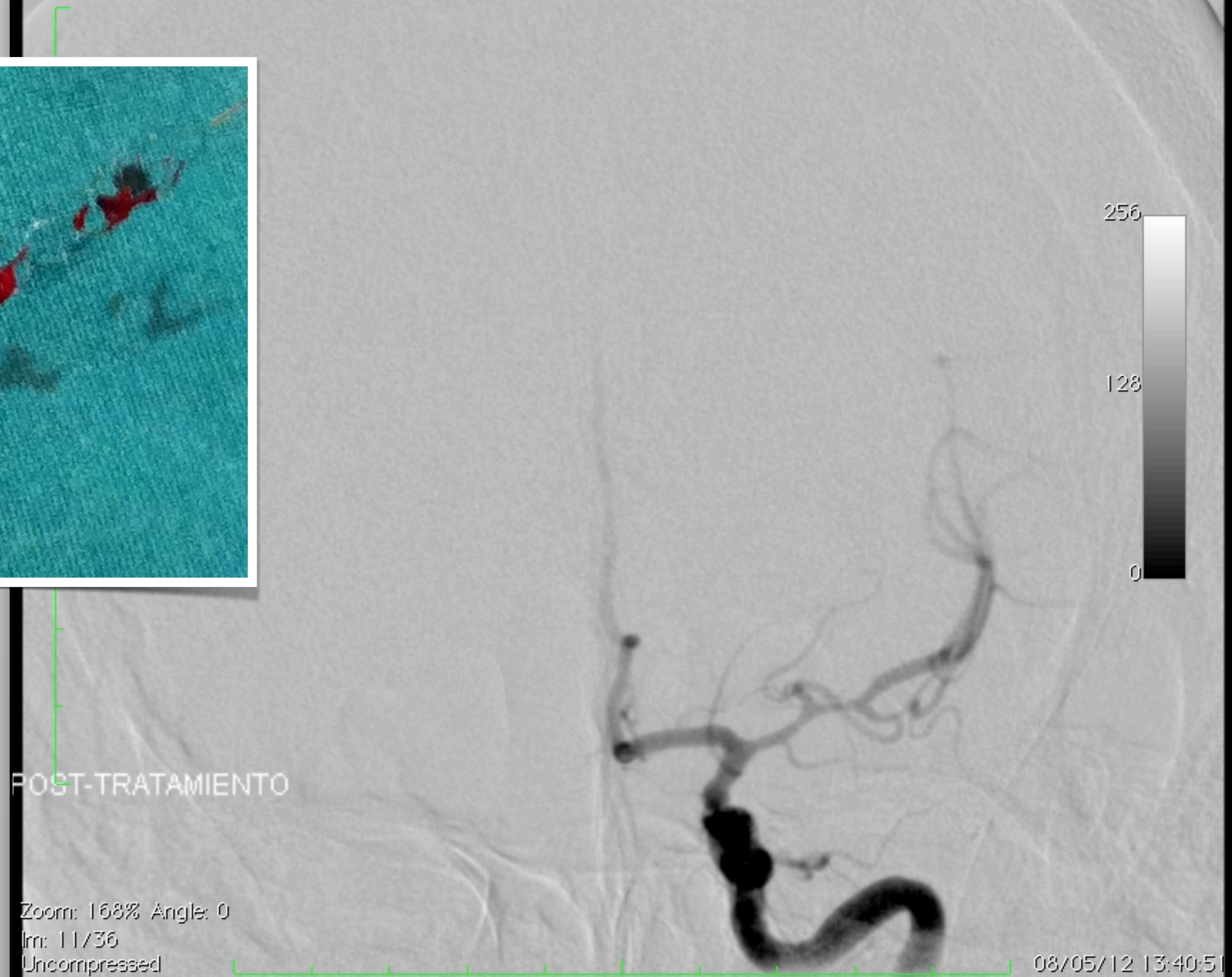
Image size: 512 x 512
View size: 858 x 858
WL: 128 WW: 255

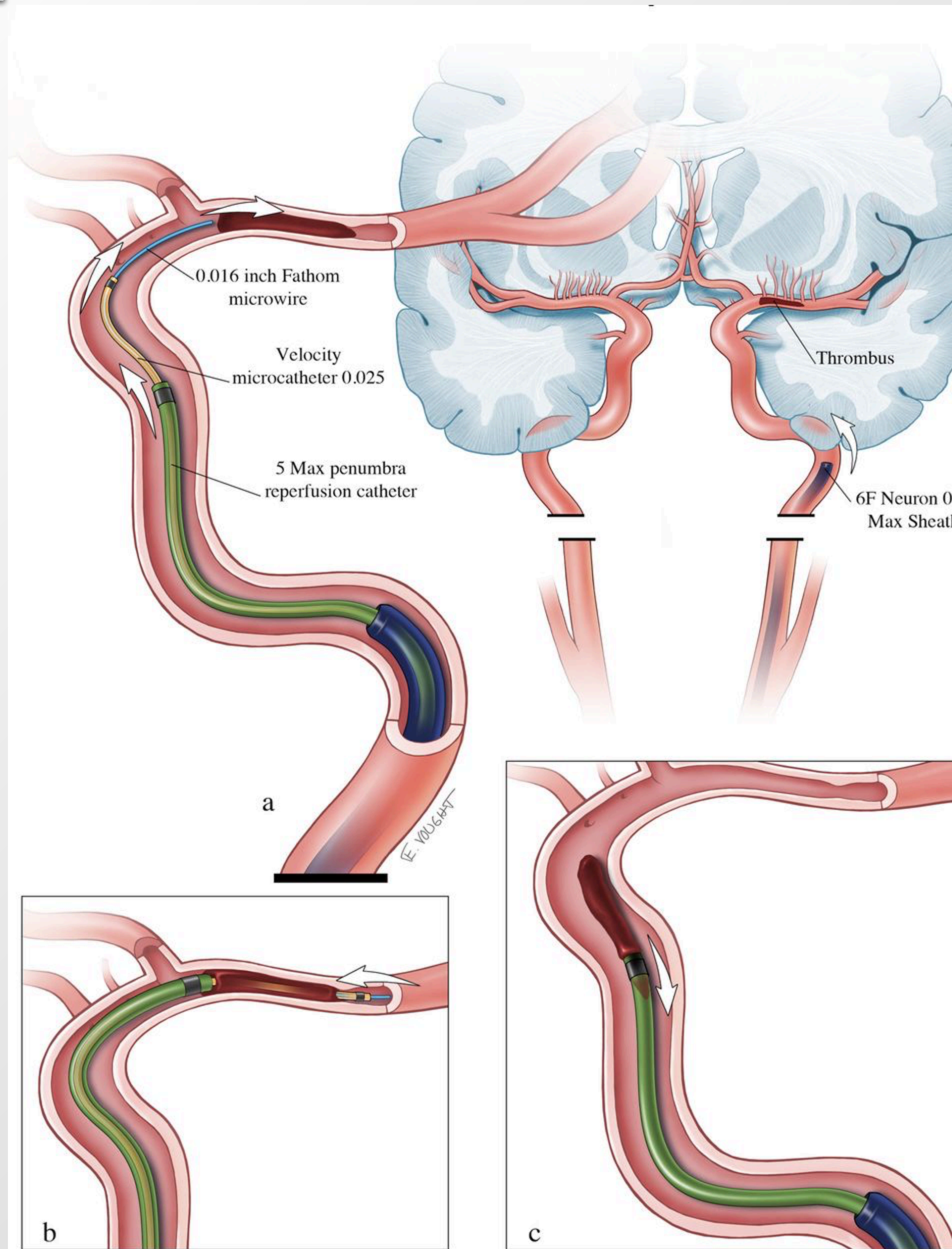
4801752 (40 y , 40 y)
Carotida — Carotida

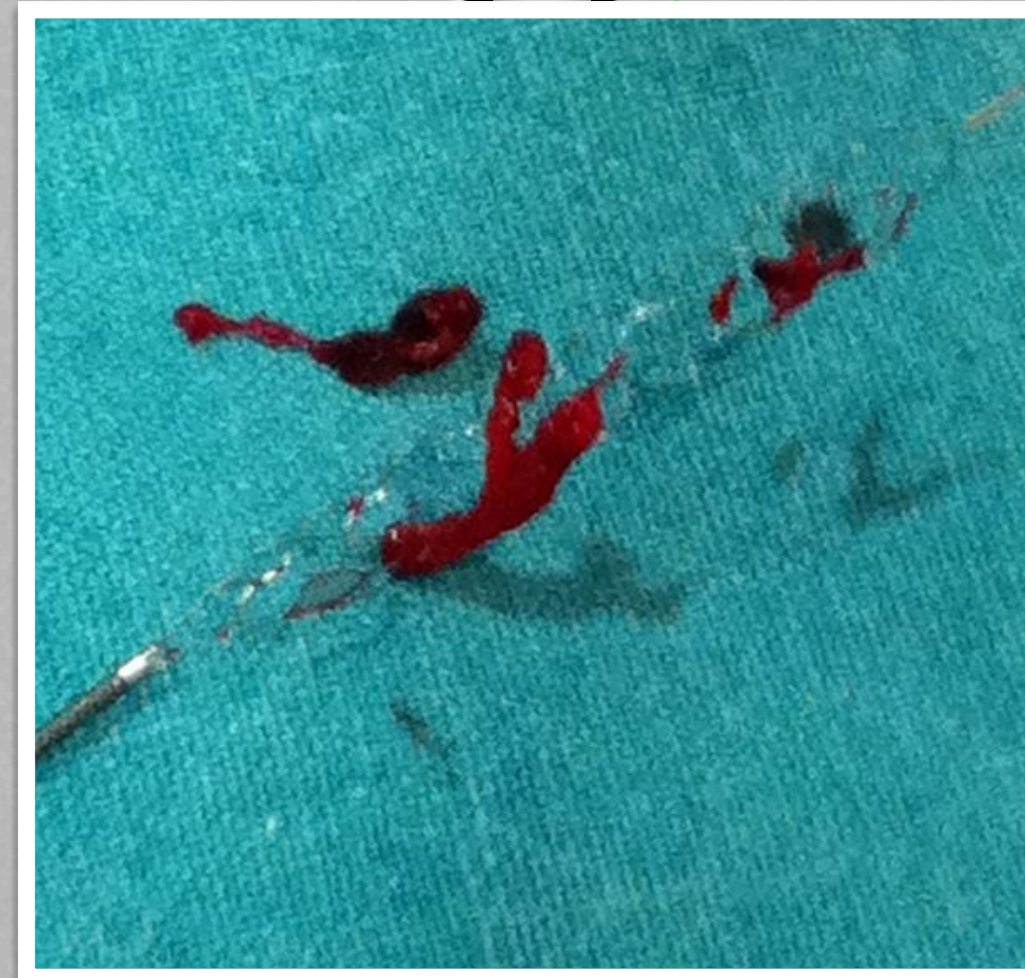
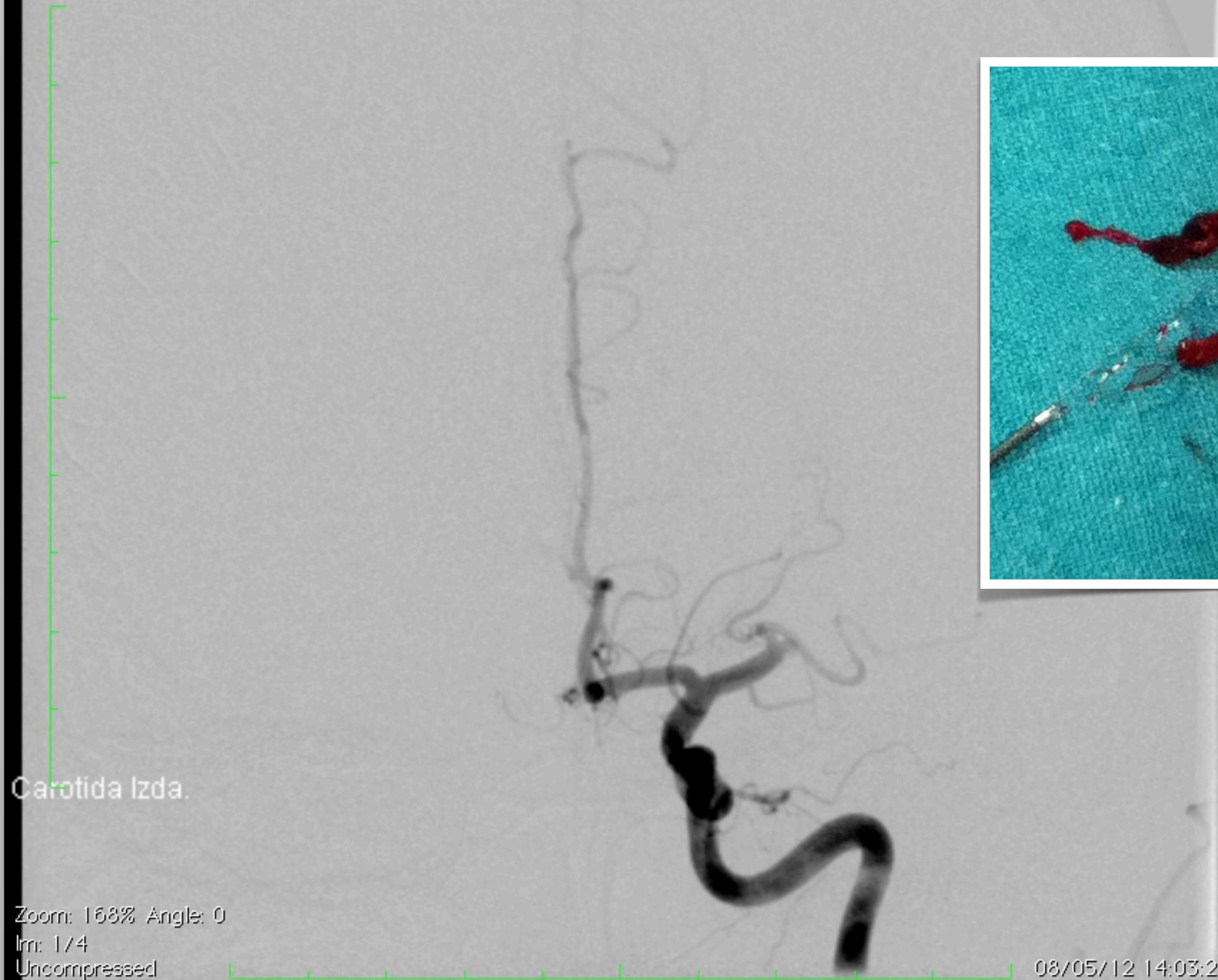
Image size: 512 x 512
View size: 858 x 858
WL: 128 WW: 255

4801752 (40 y , 40 y)
Carotida — Carotida





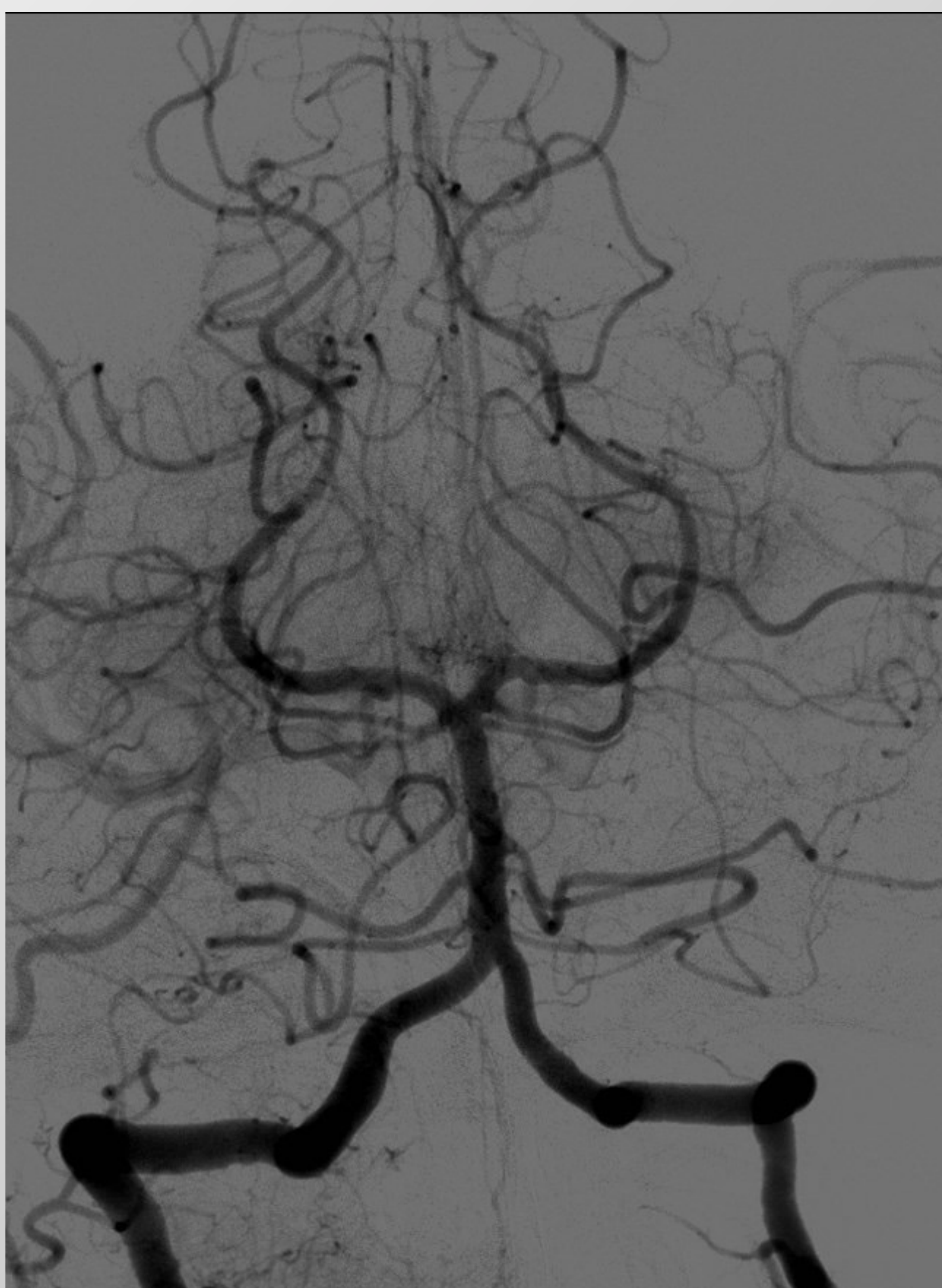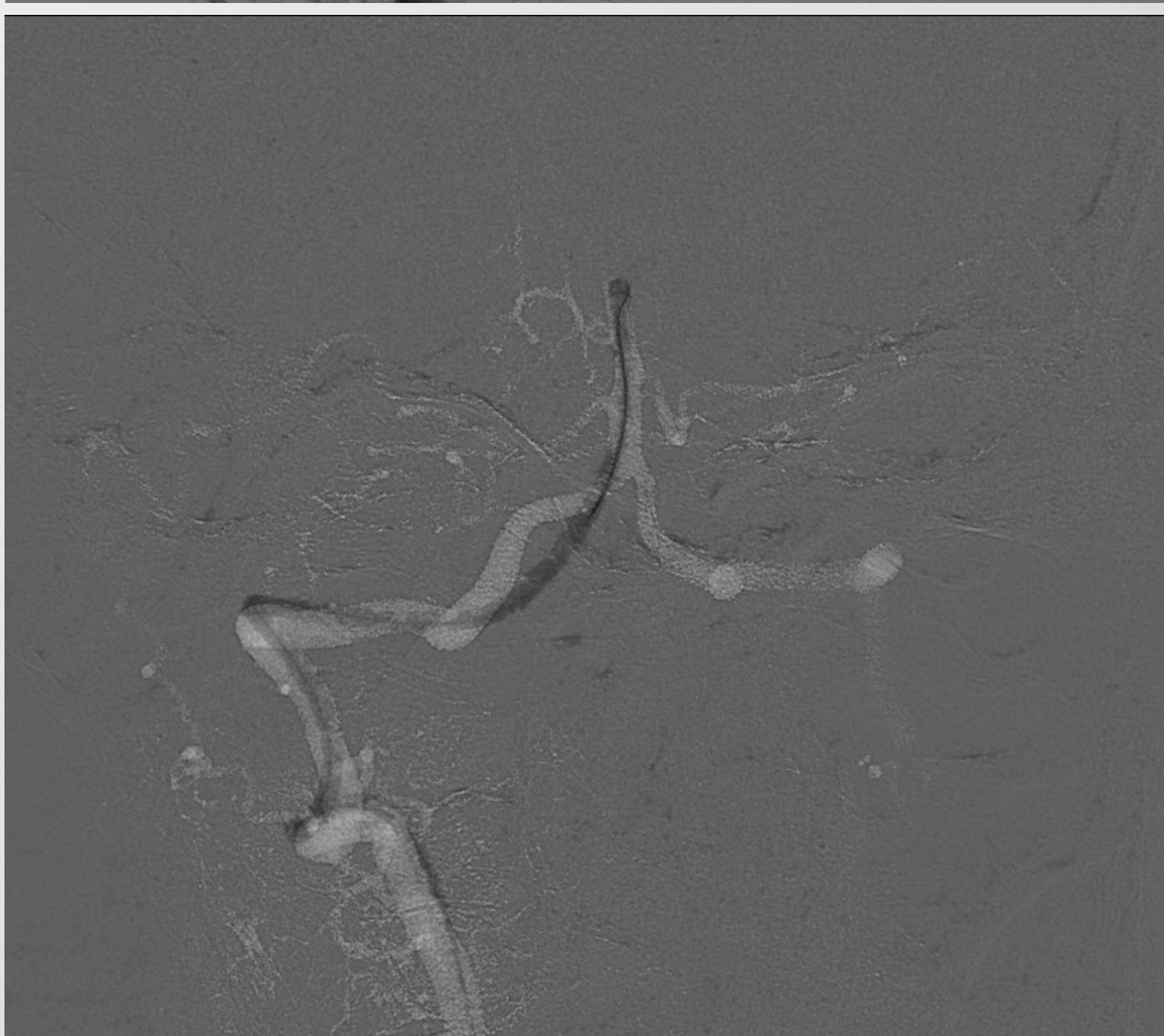
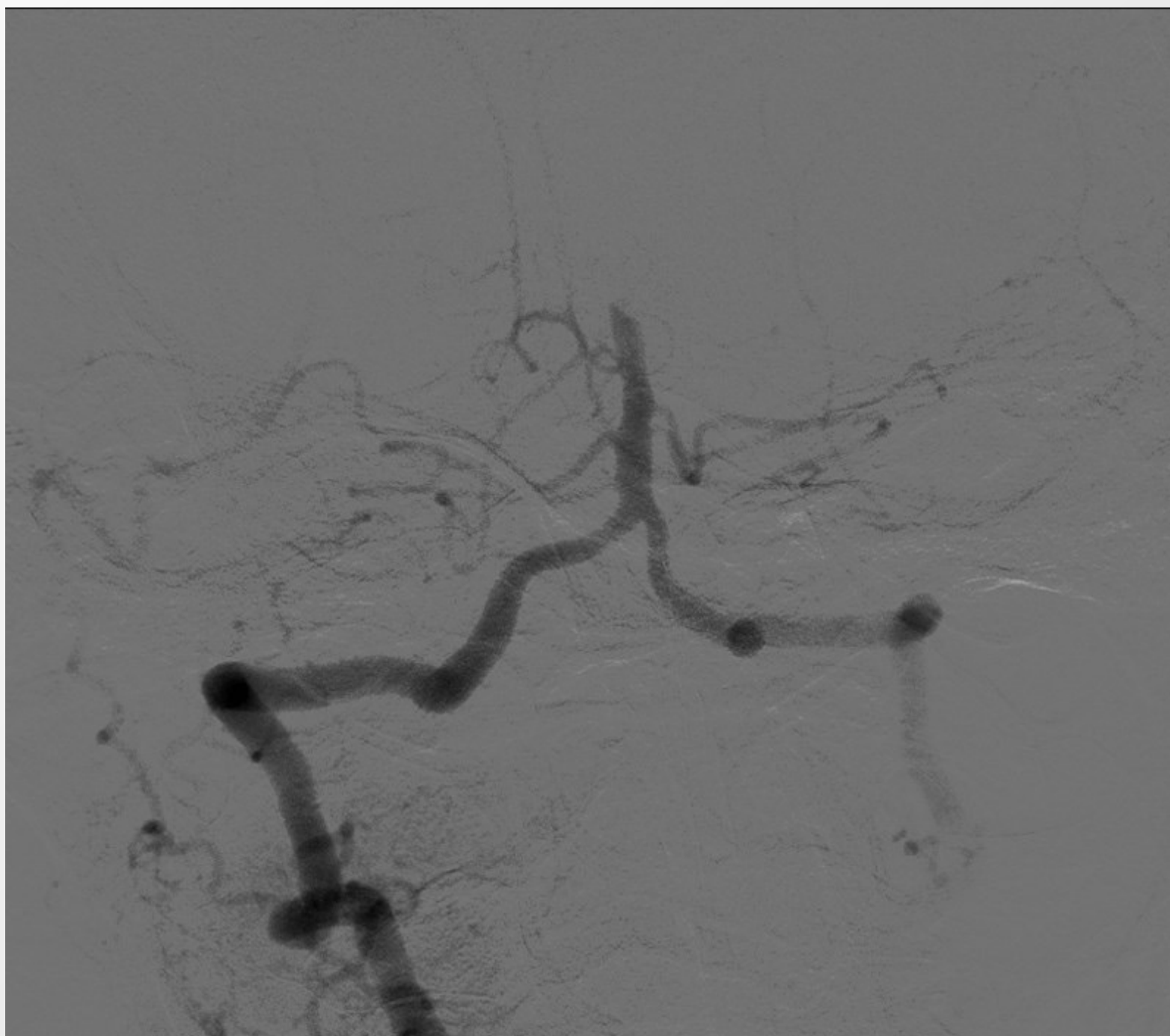
Initial clinical experience with the ADAPT technique: A direct aspiration first pass technique for stroke thrombectomy

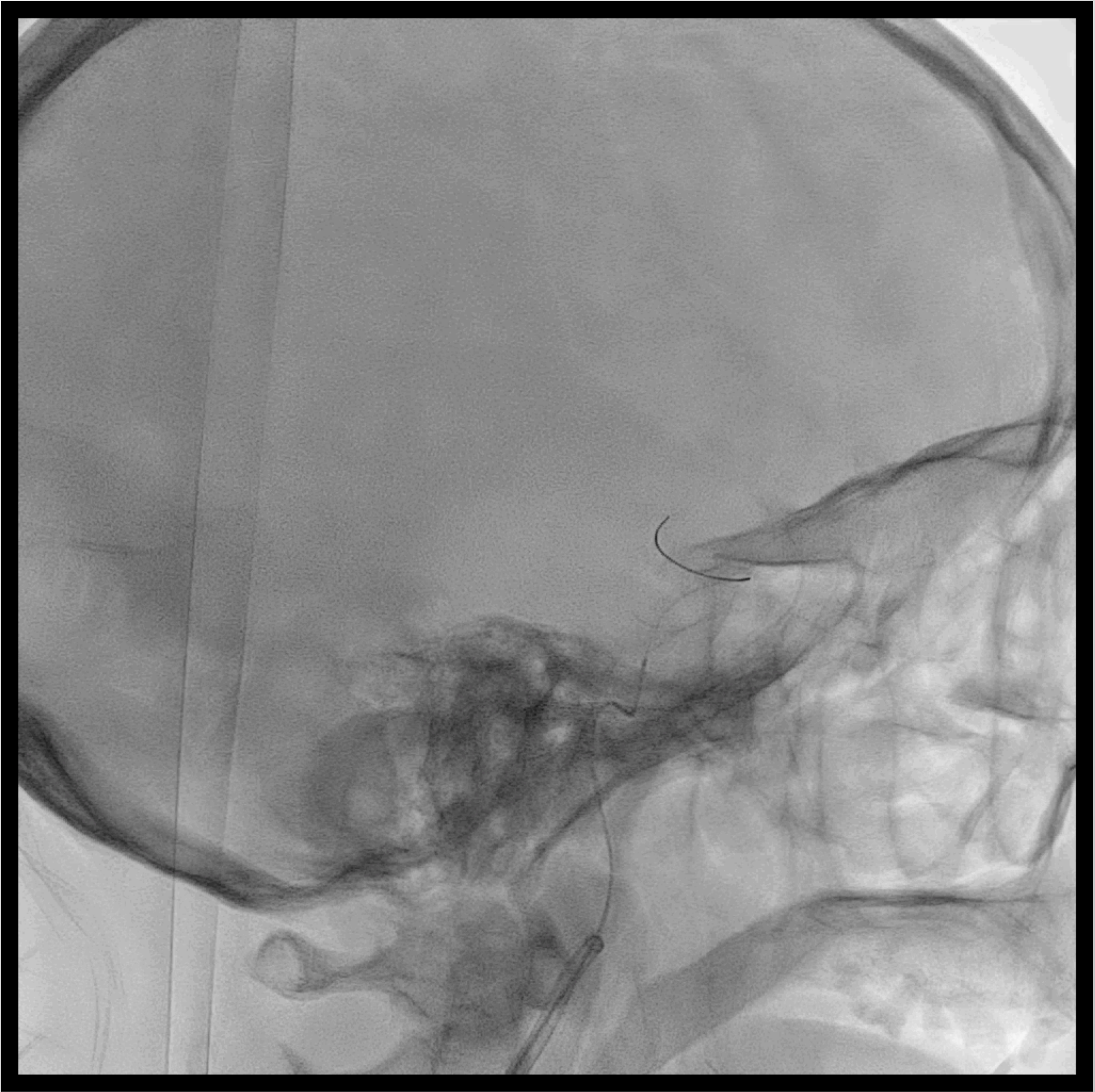Turk AS, Spiotta A, Frei D, et al. Initial clinical experience with the ADAPT technique: A direct aspiration first pass technique for stroke thrombectomy. Journal of NeuroInterventional Surgery 2014;6:231-237.

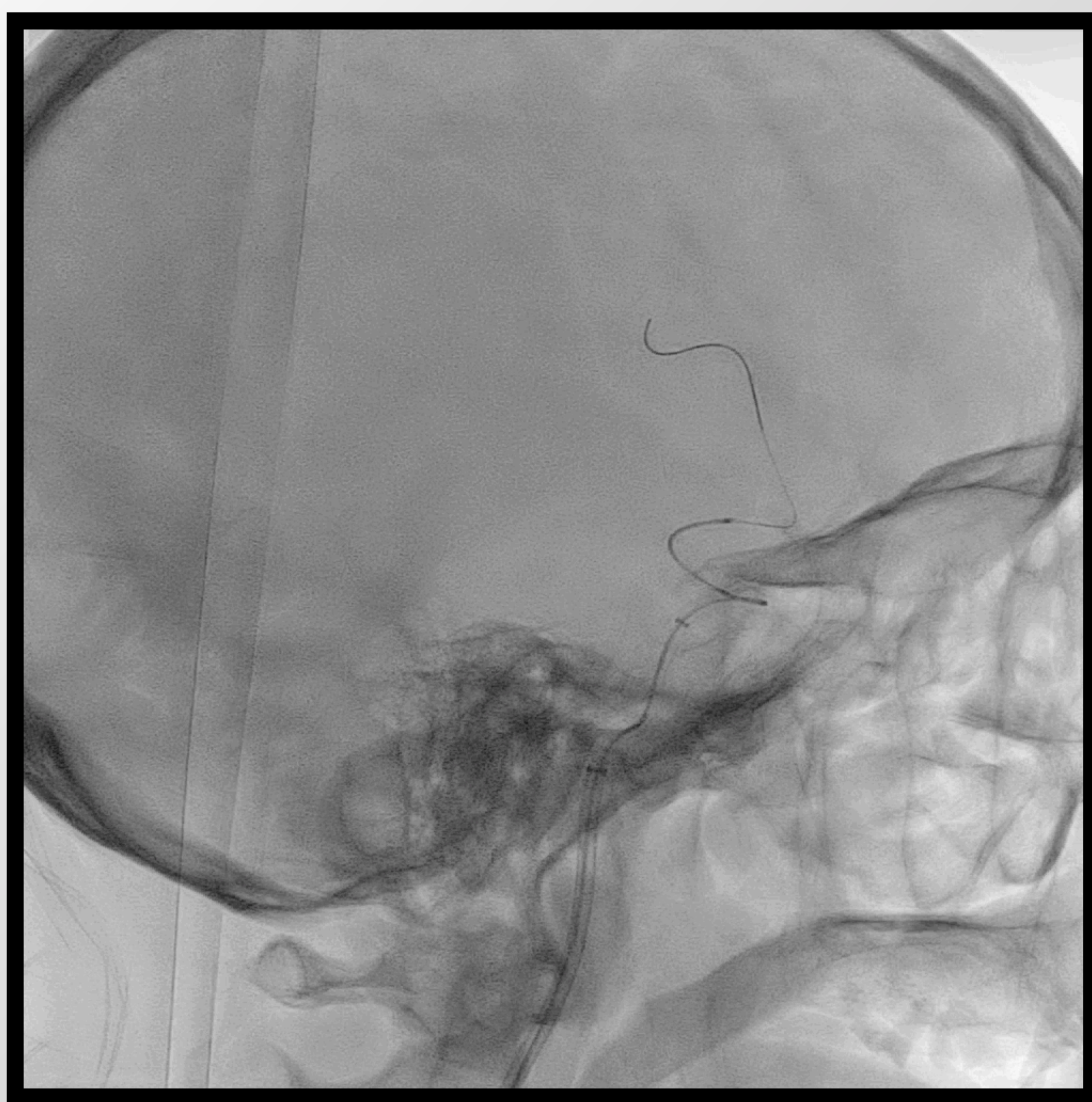ADAPT FAST study: a direct aspiration first pass technique for acute stroke thrombectomy

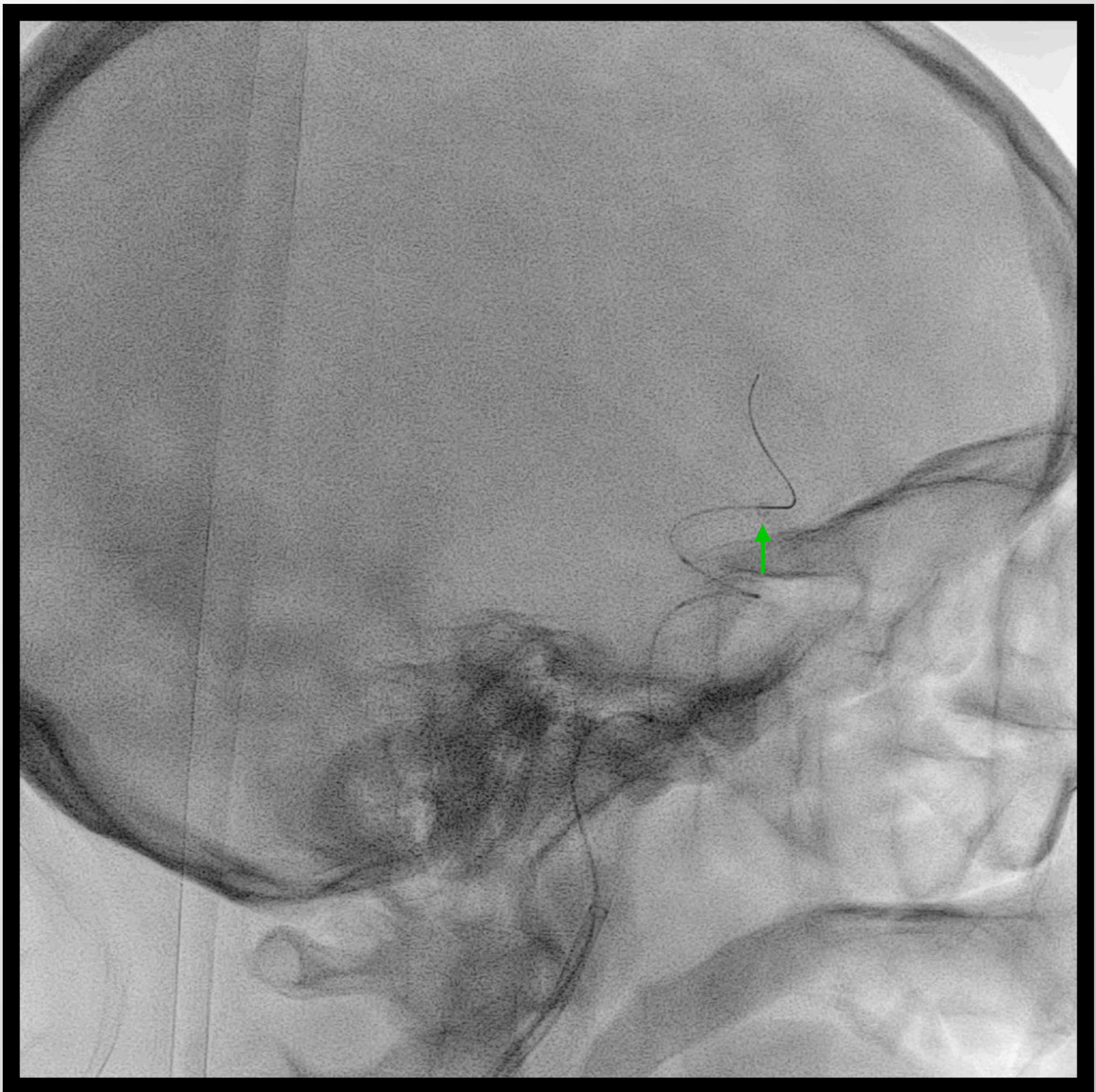Turk AS, Frei D, Fiorella D, et al. J NeuroIntervent Surg 2014;6:260-264.

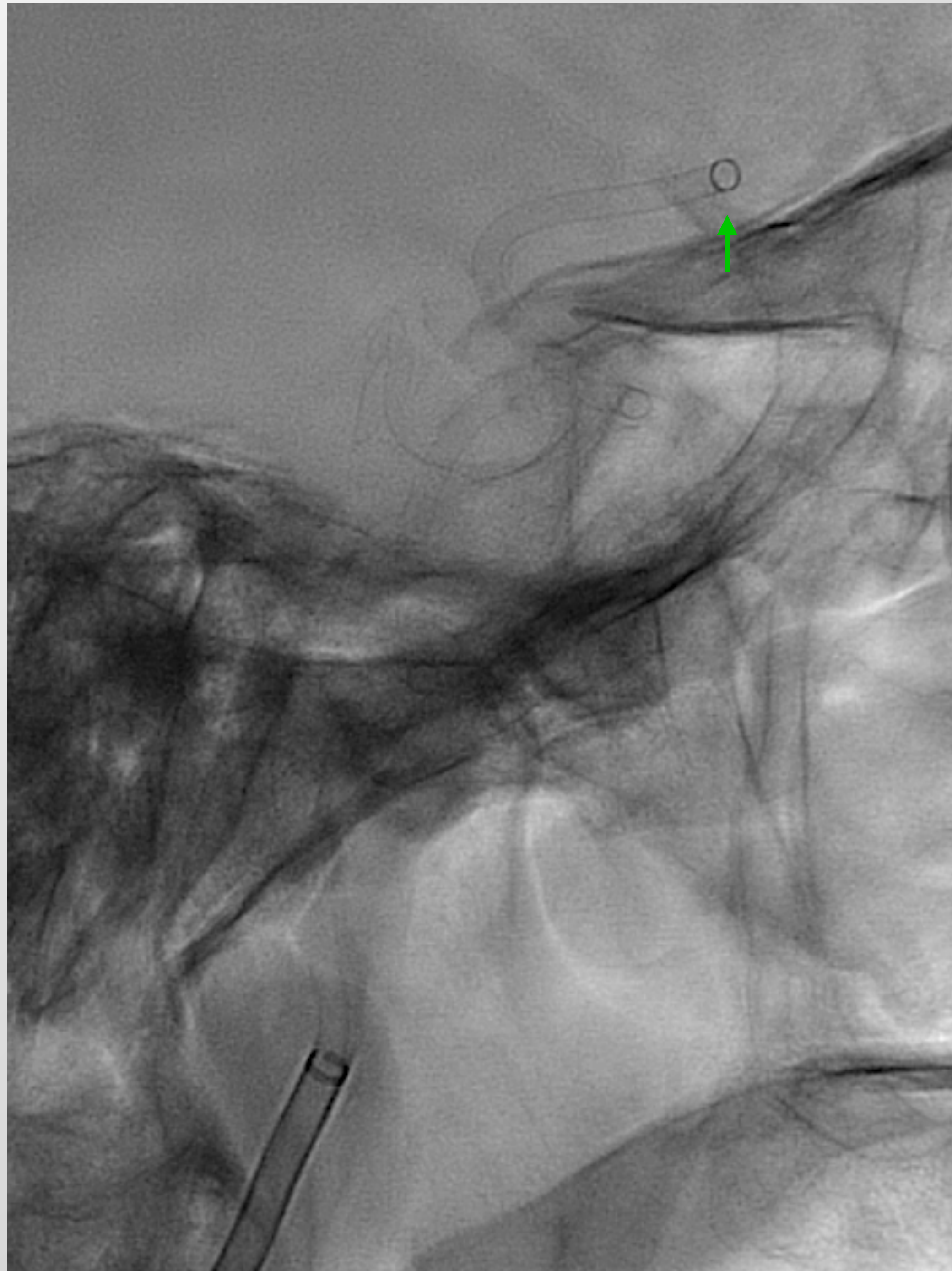



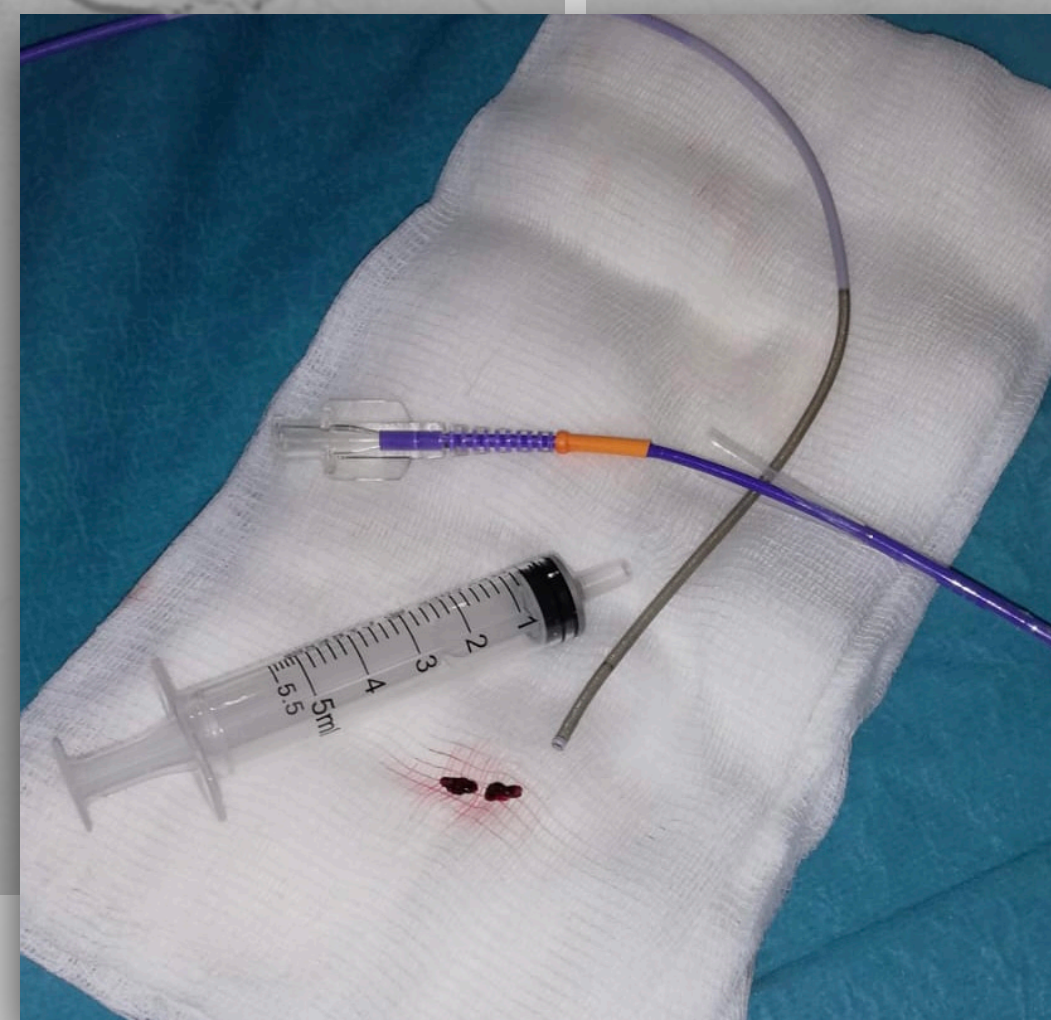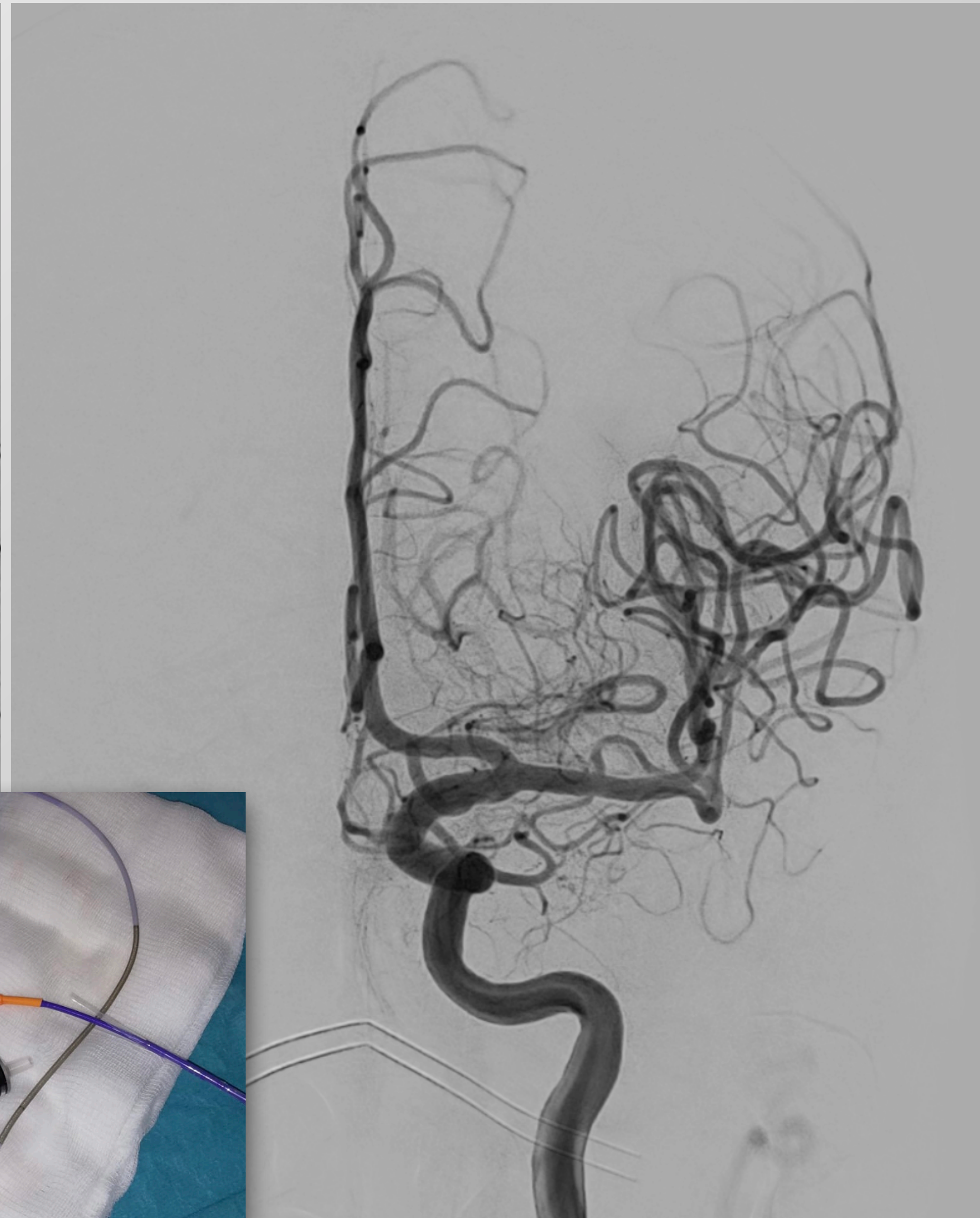


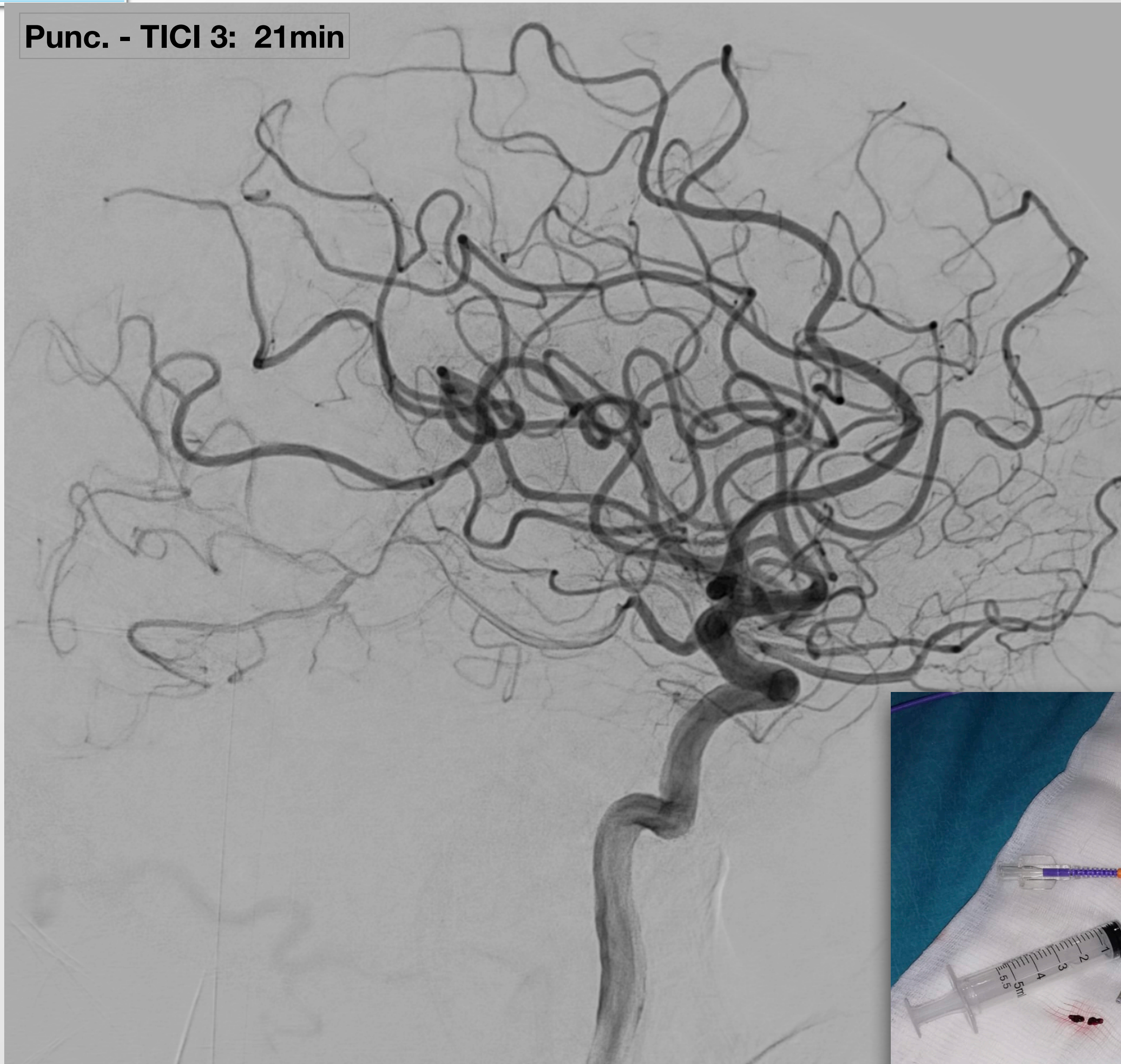




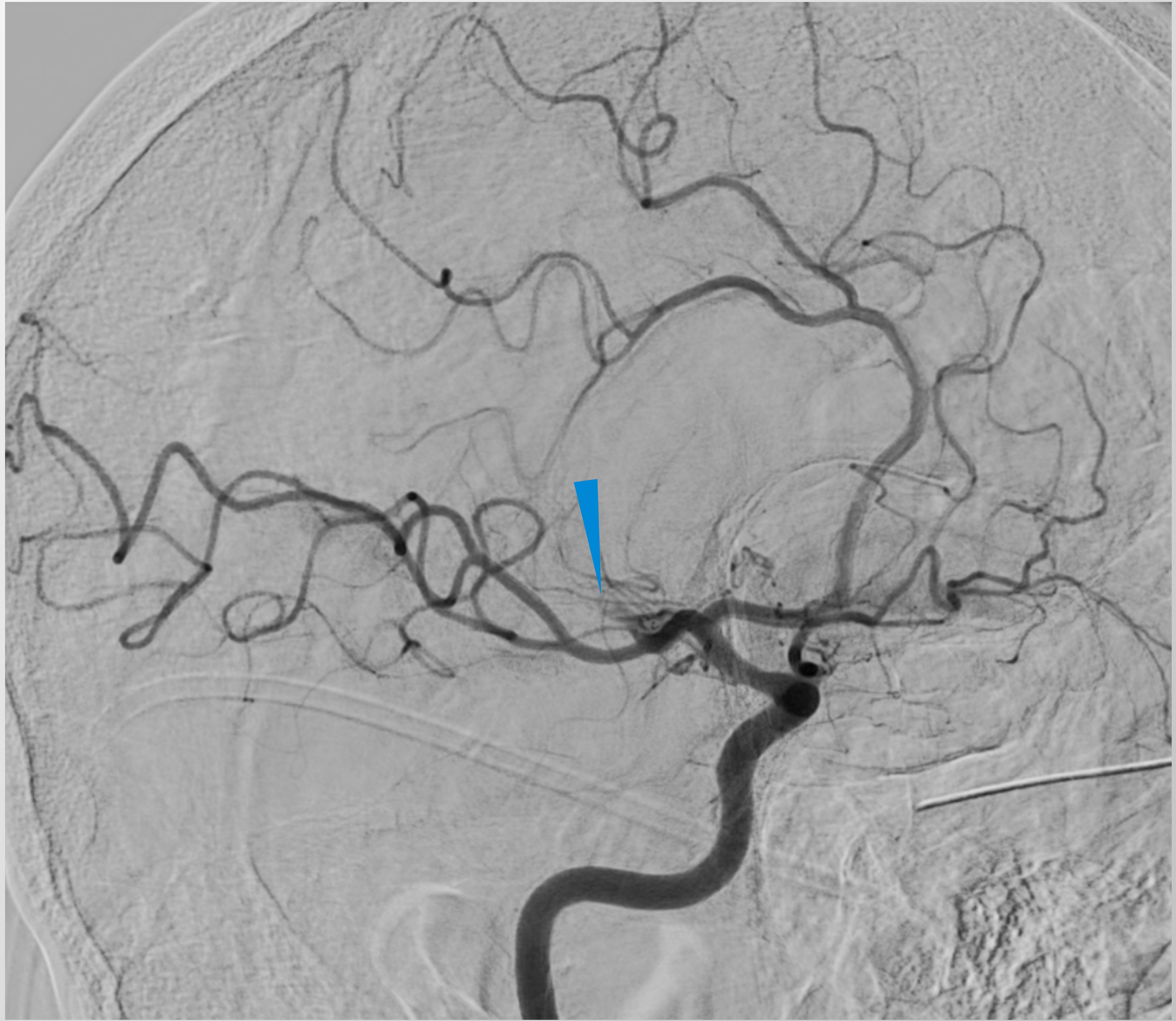
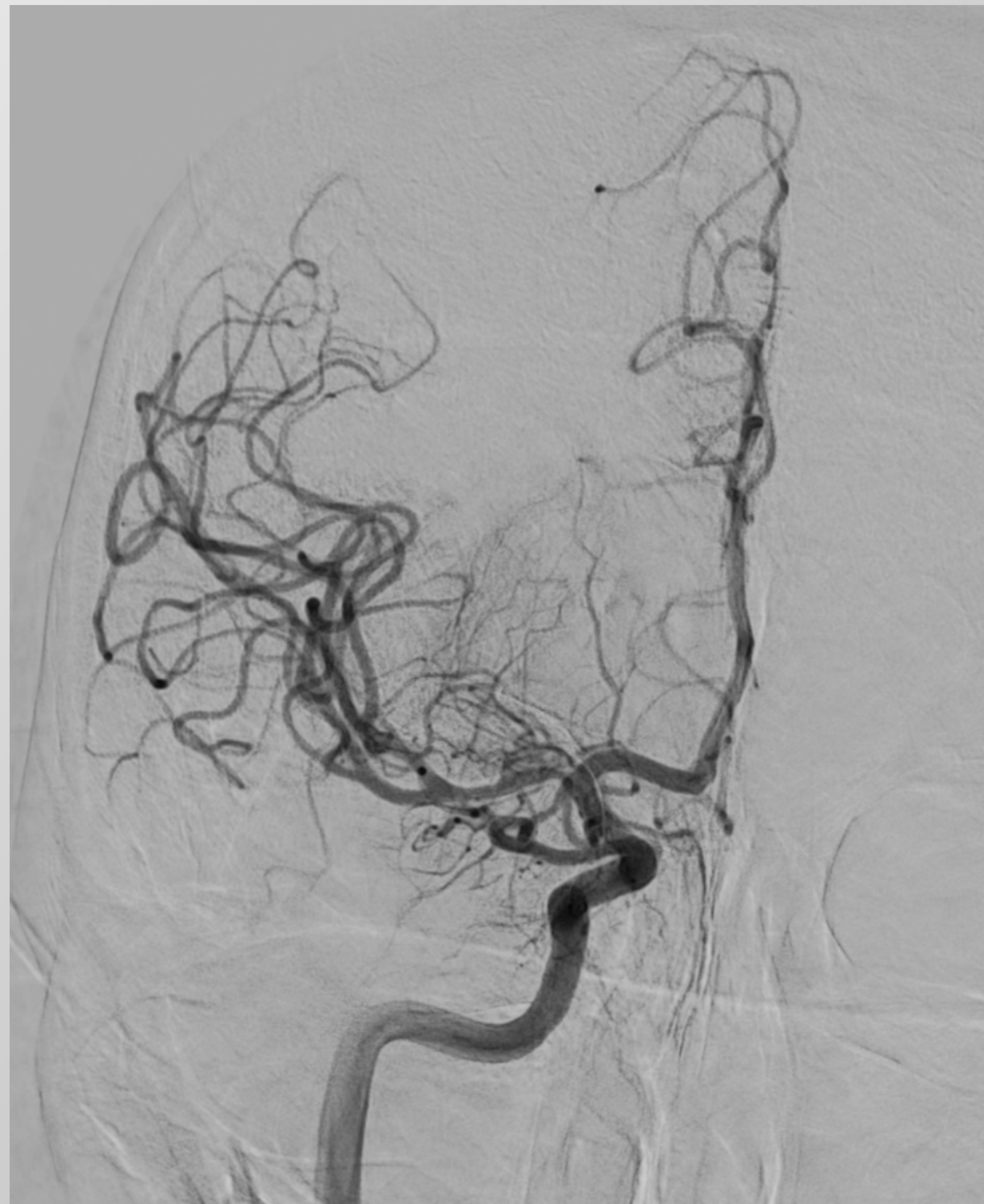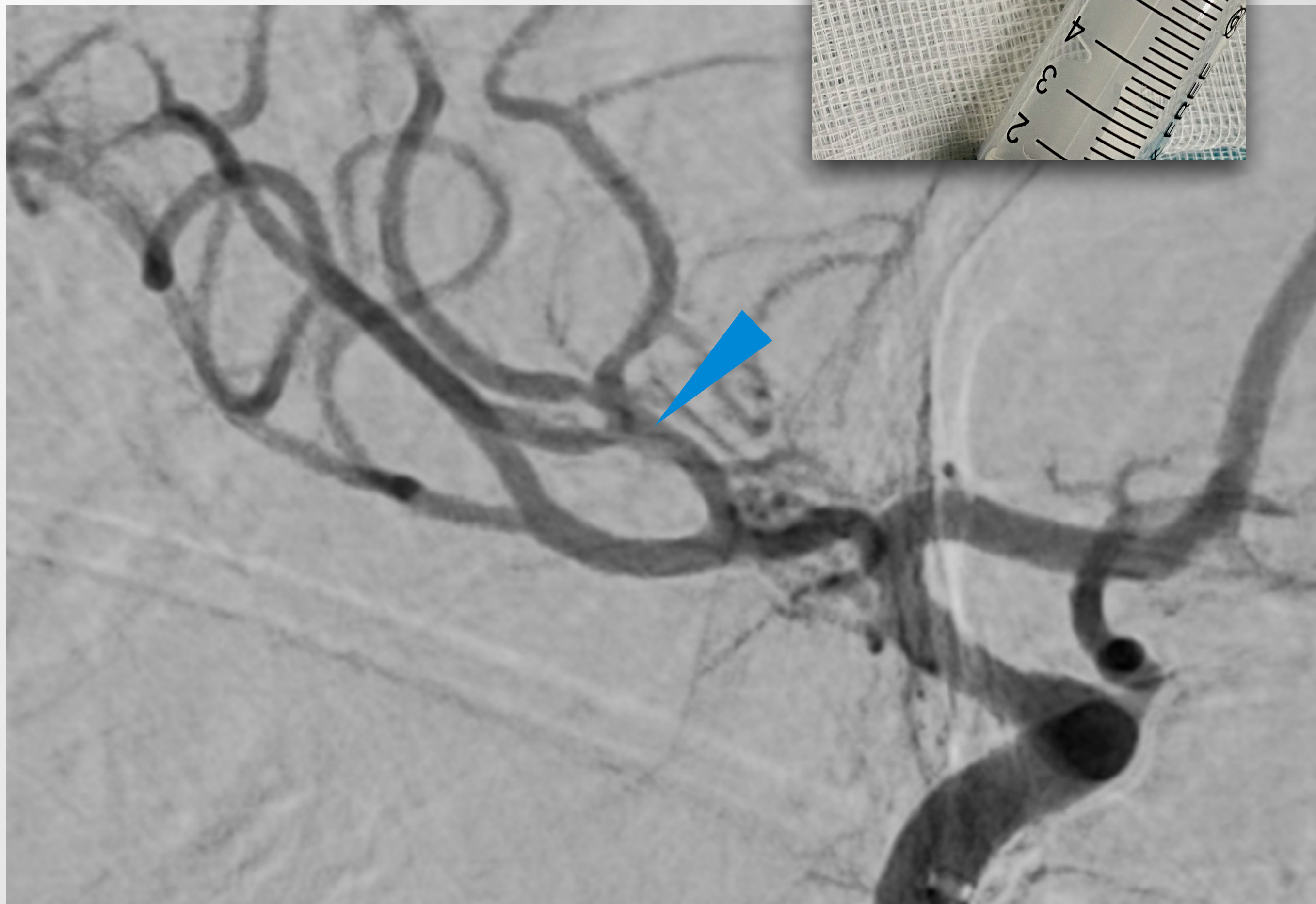
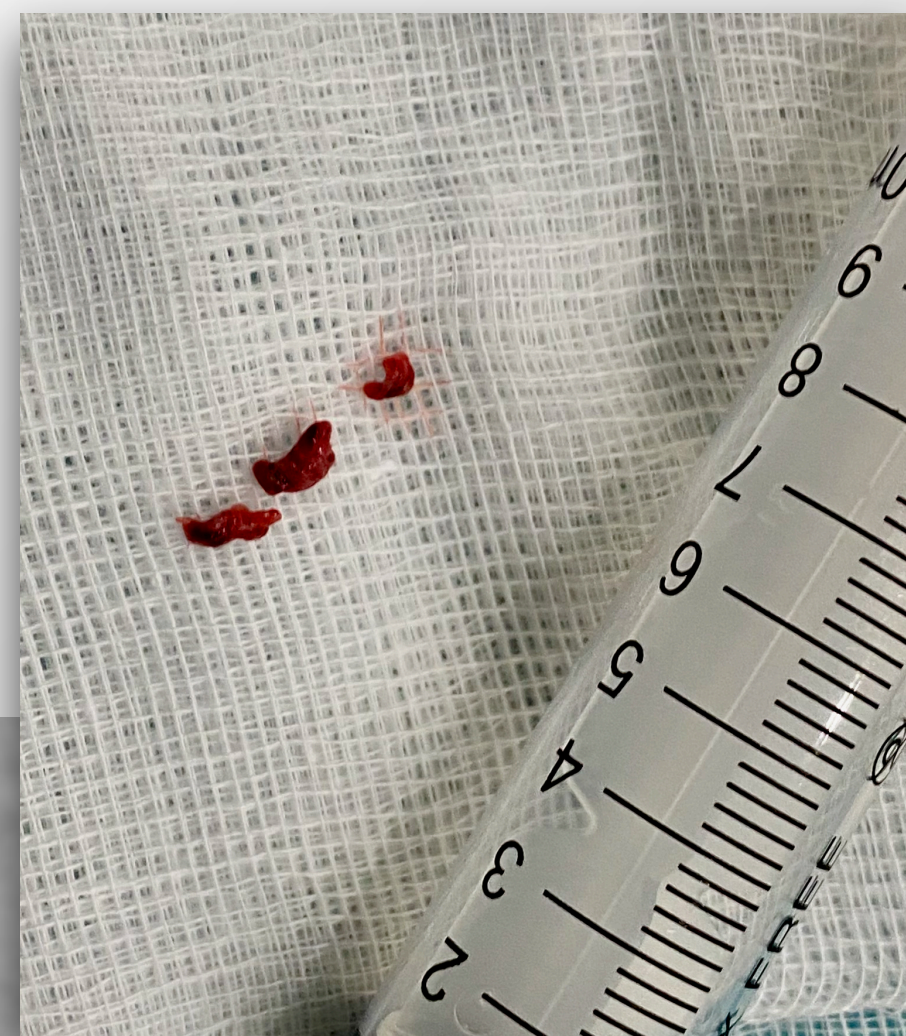Punc. - TICl 3: 21min

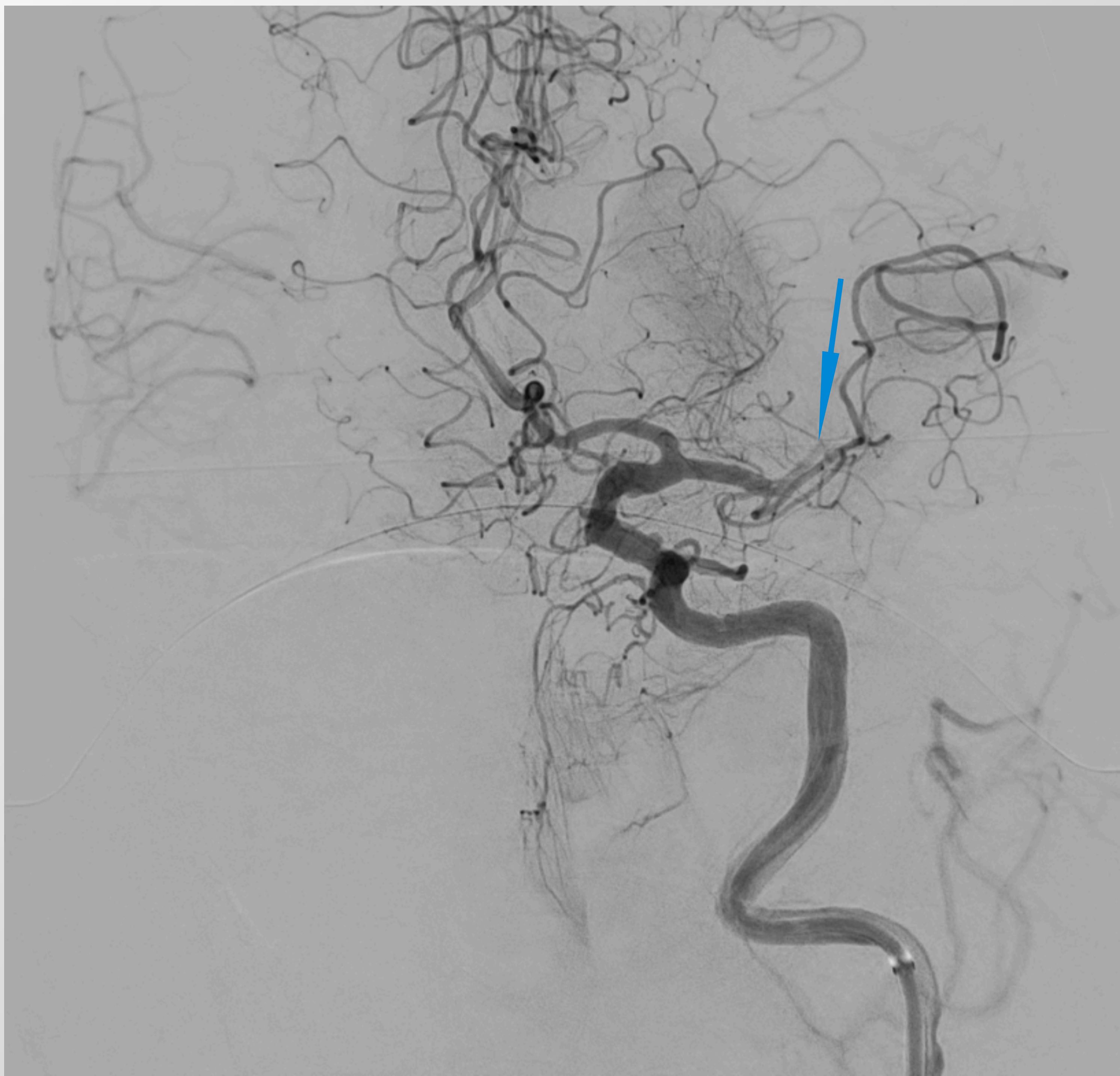

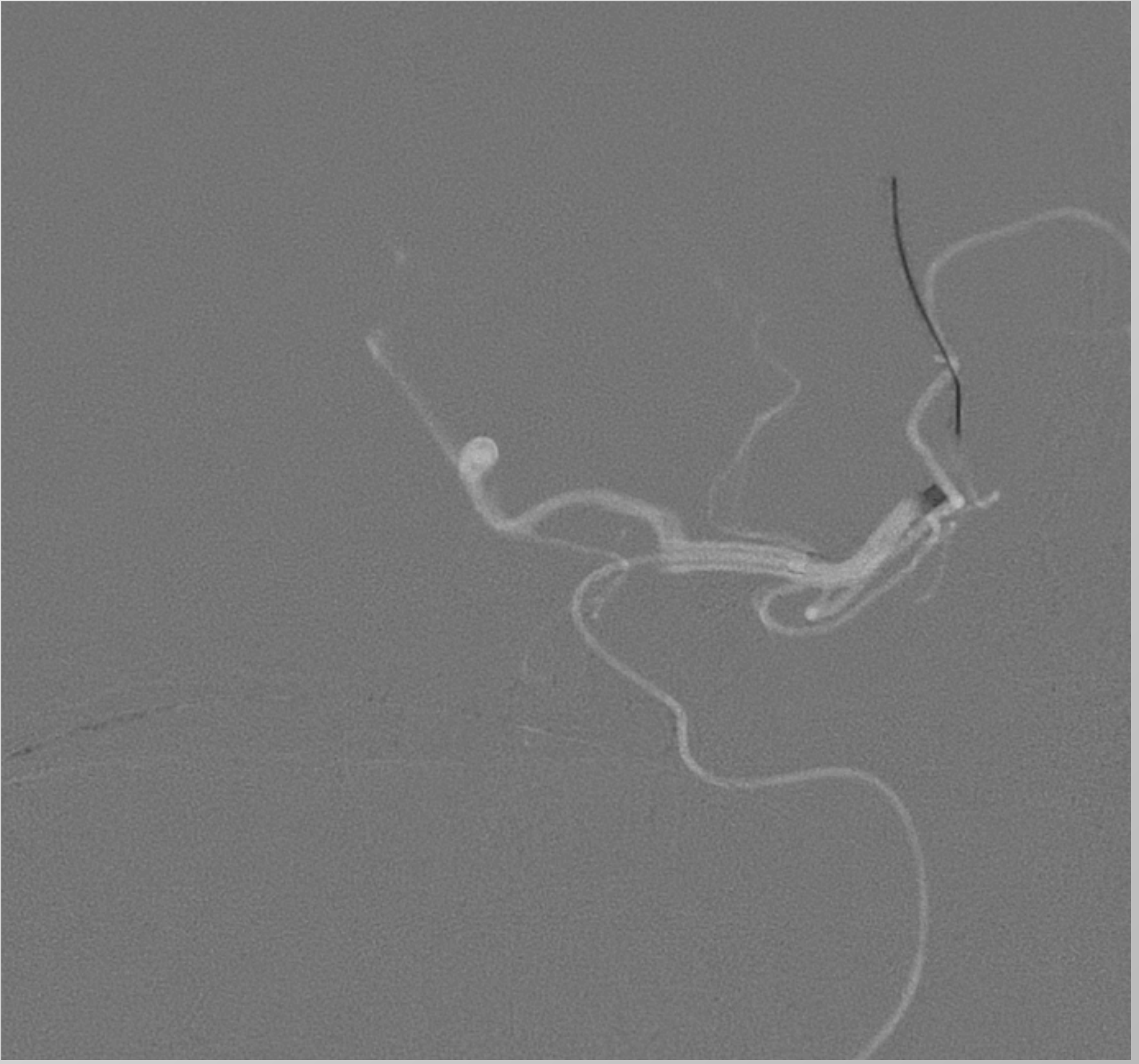
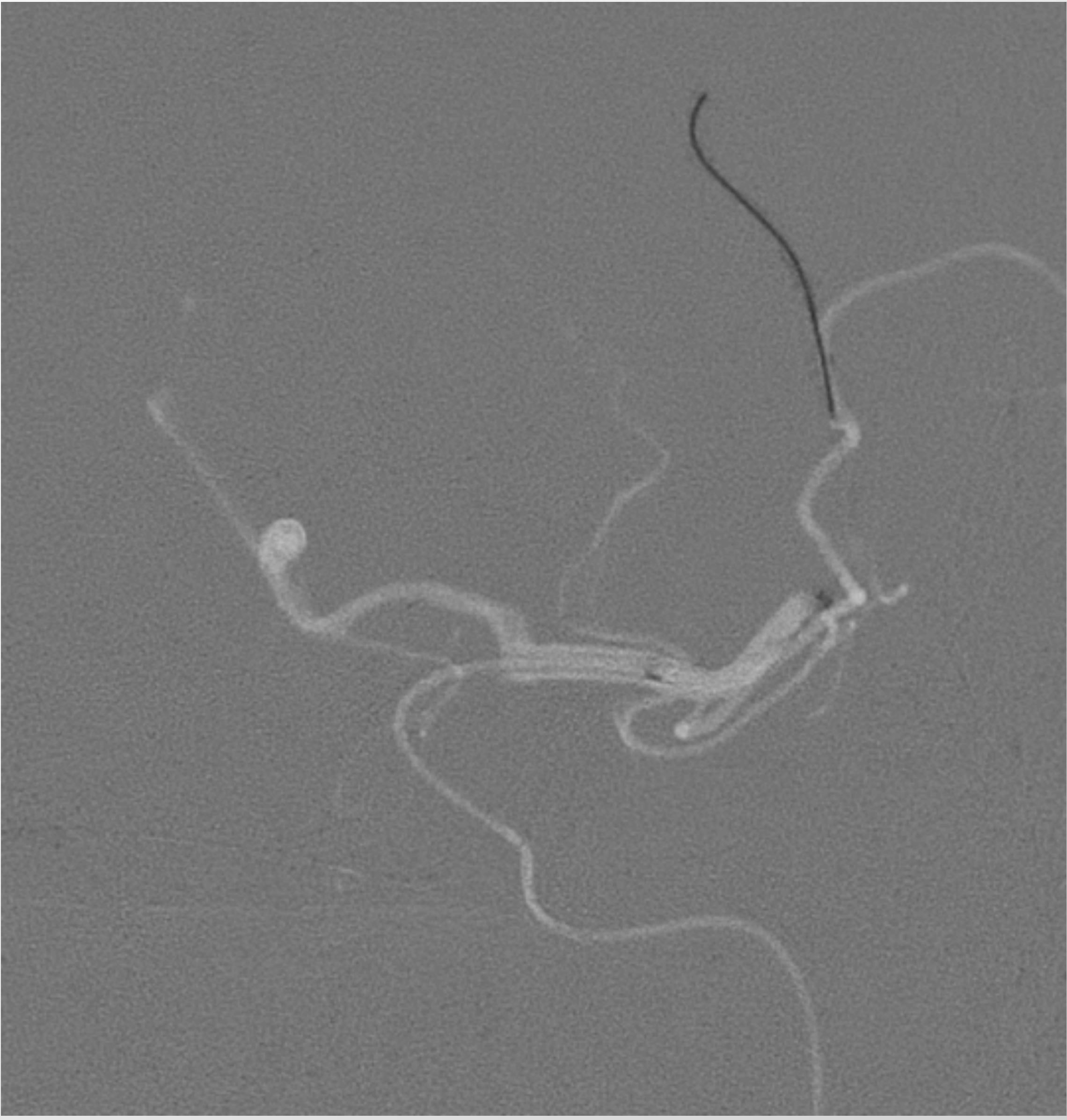
- 59 y/o
- NIHSS 12
- ASPECTS 5
- 14:20h.
- P.: 17:36h.

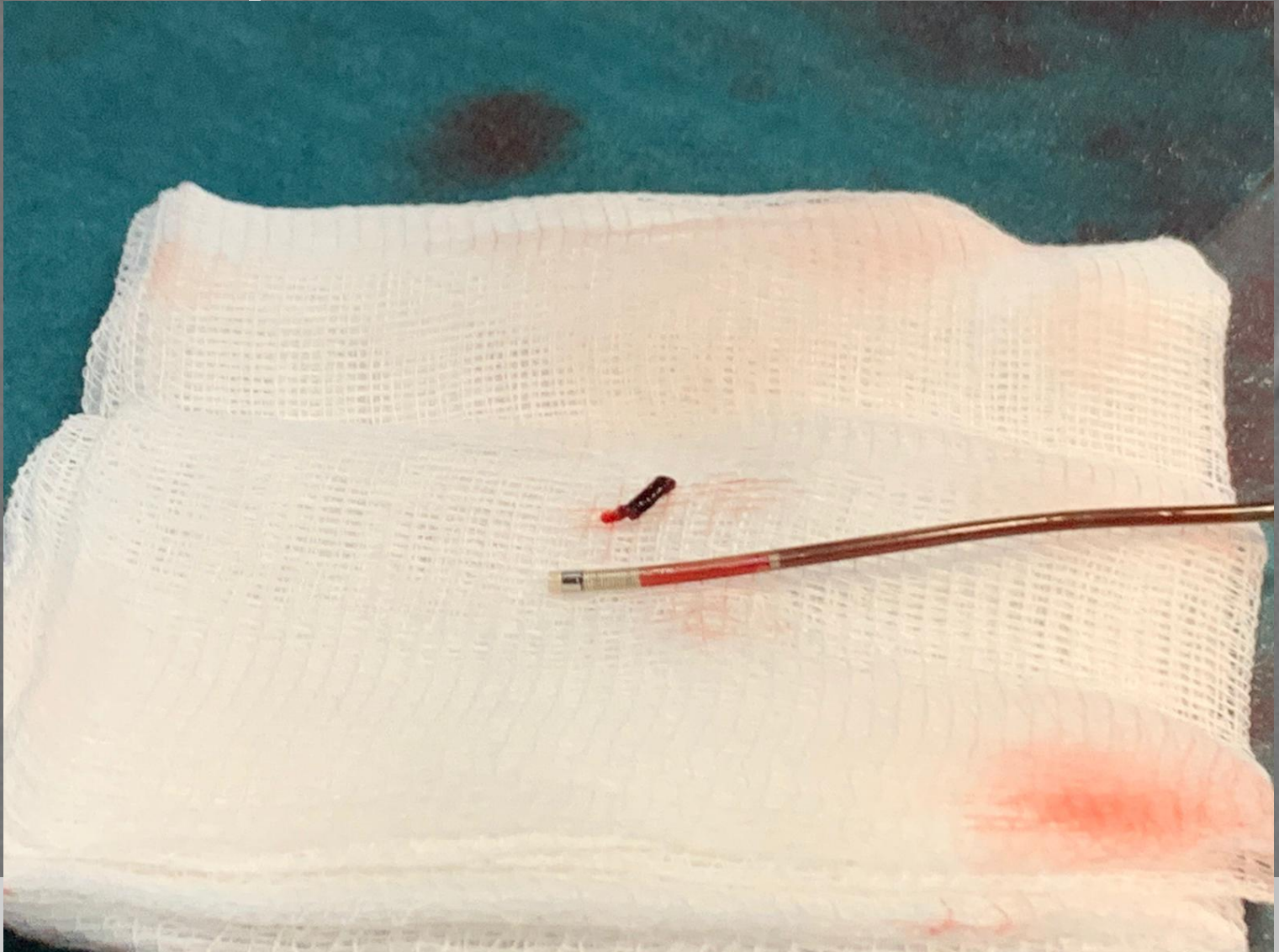
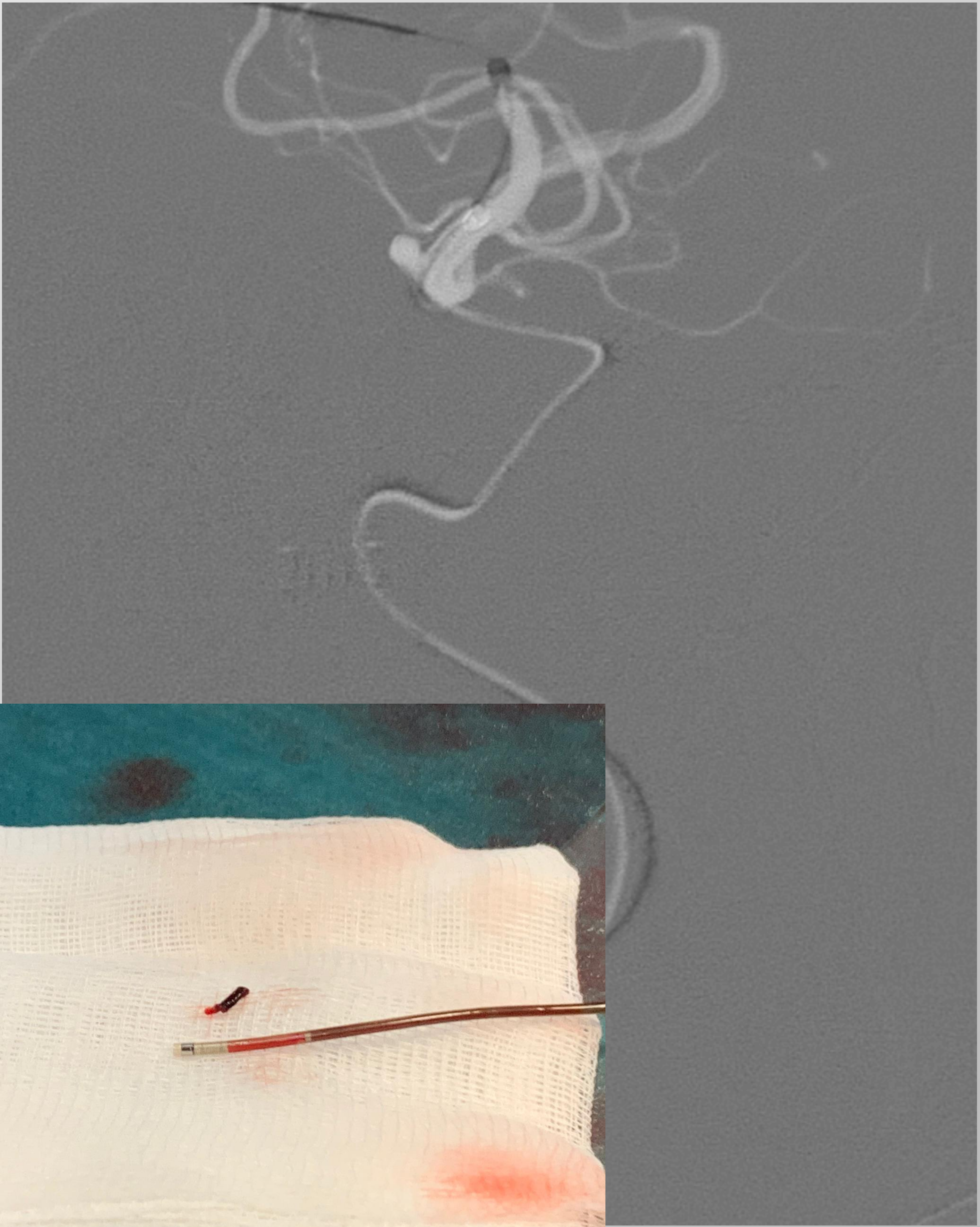
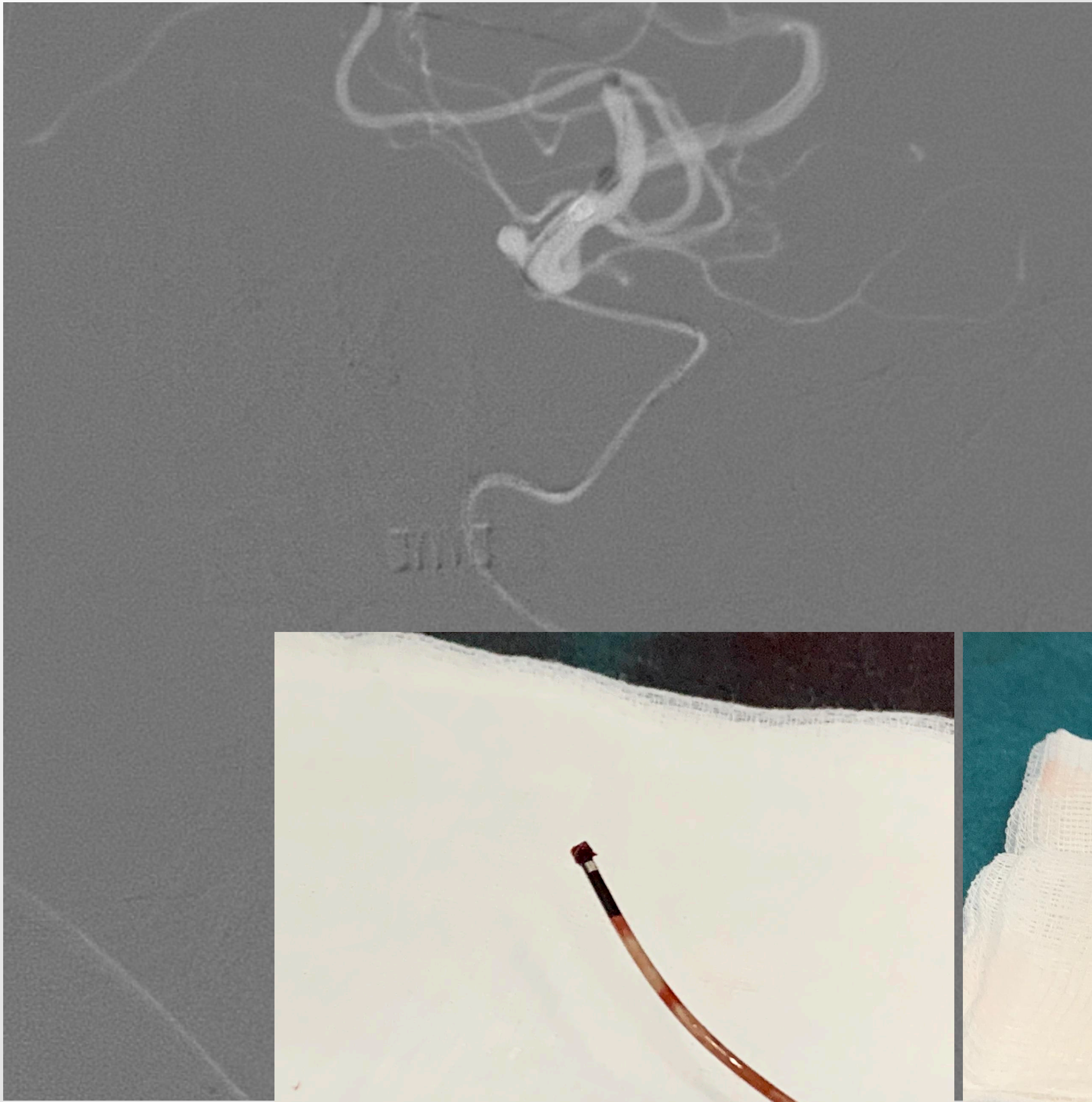- TICI 3: 17:51h.
- P-R: 15min.
- NIHSS 24h: 2

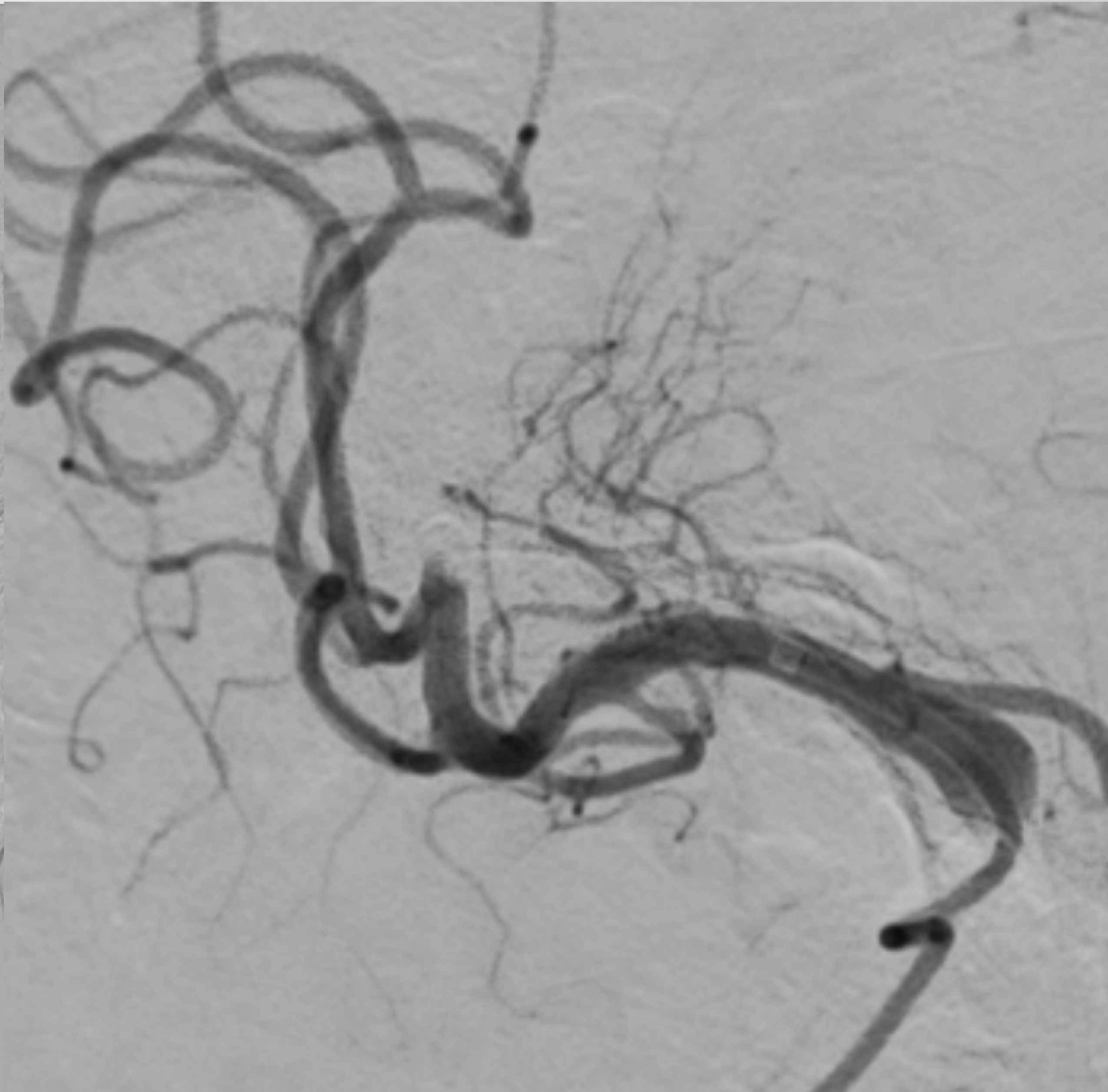
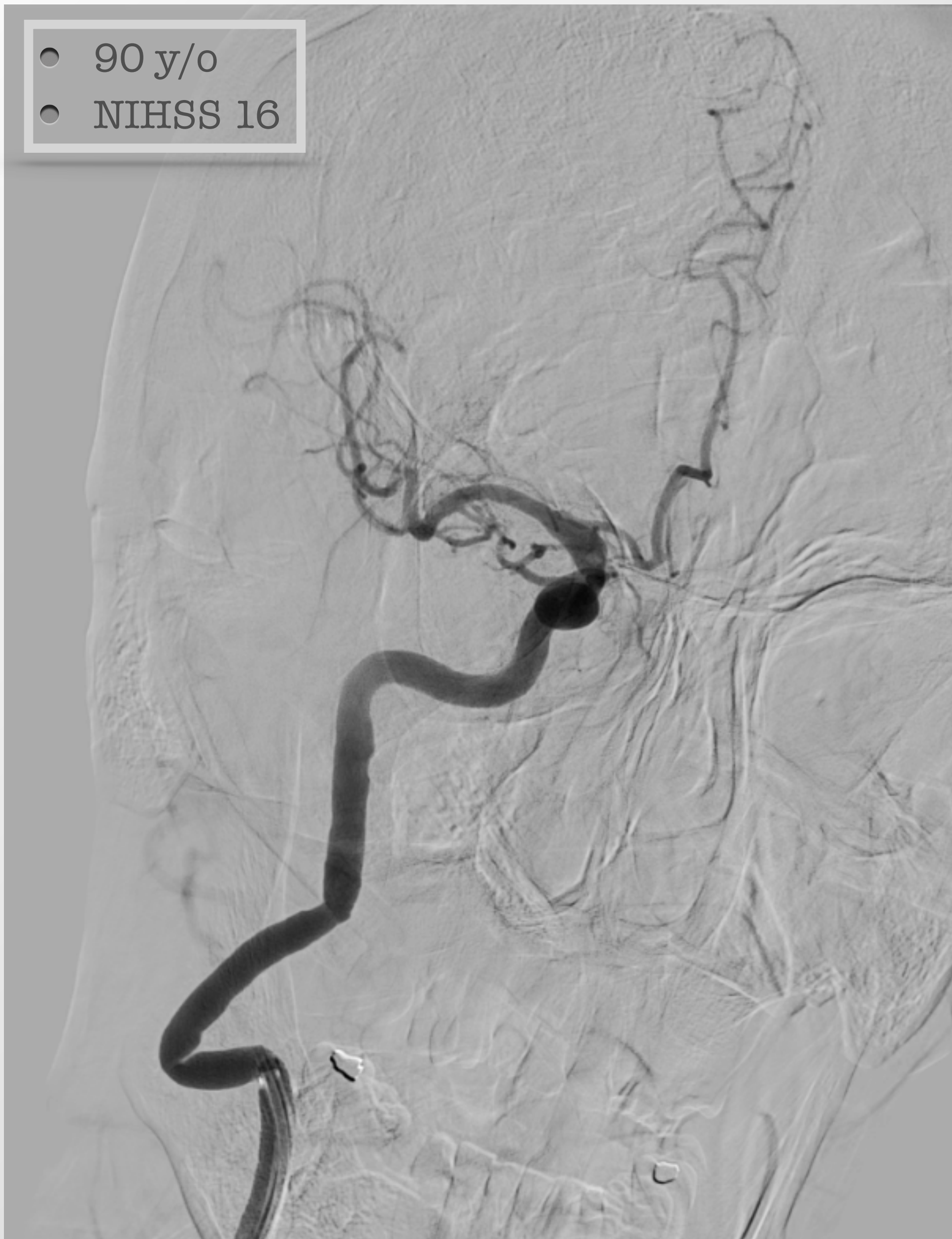


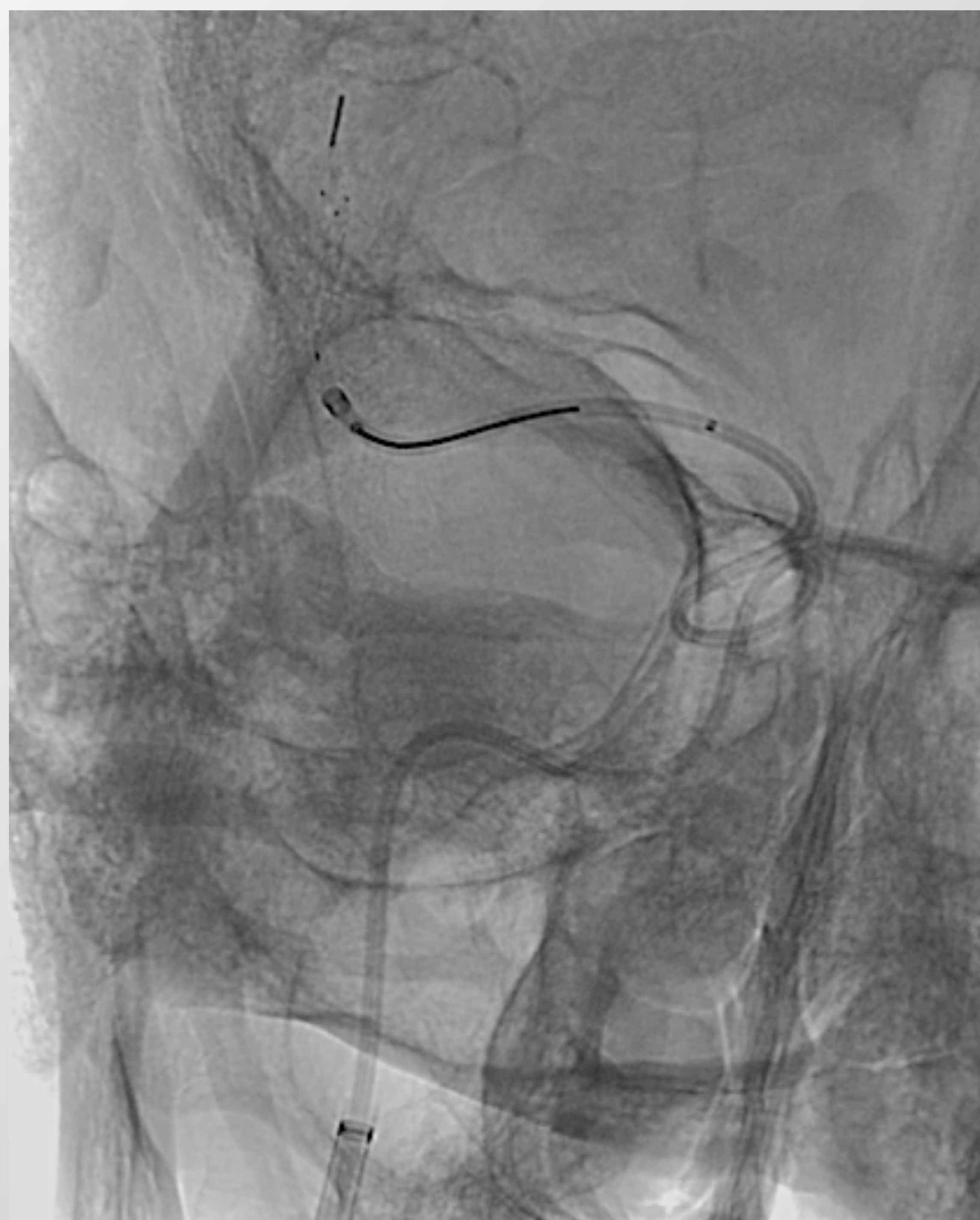




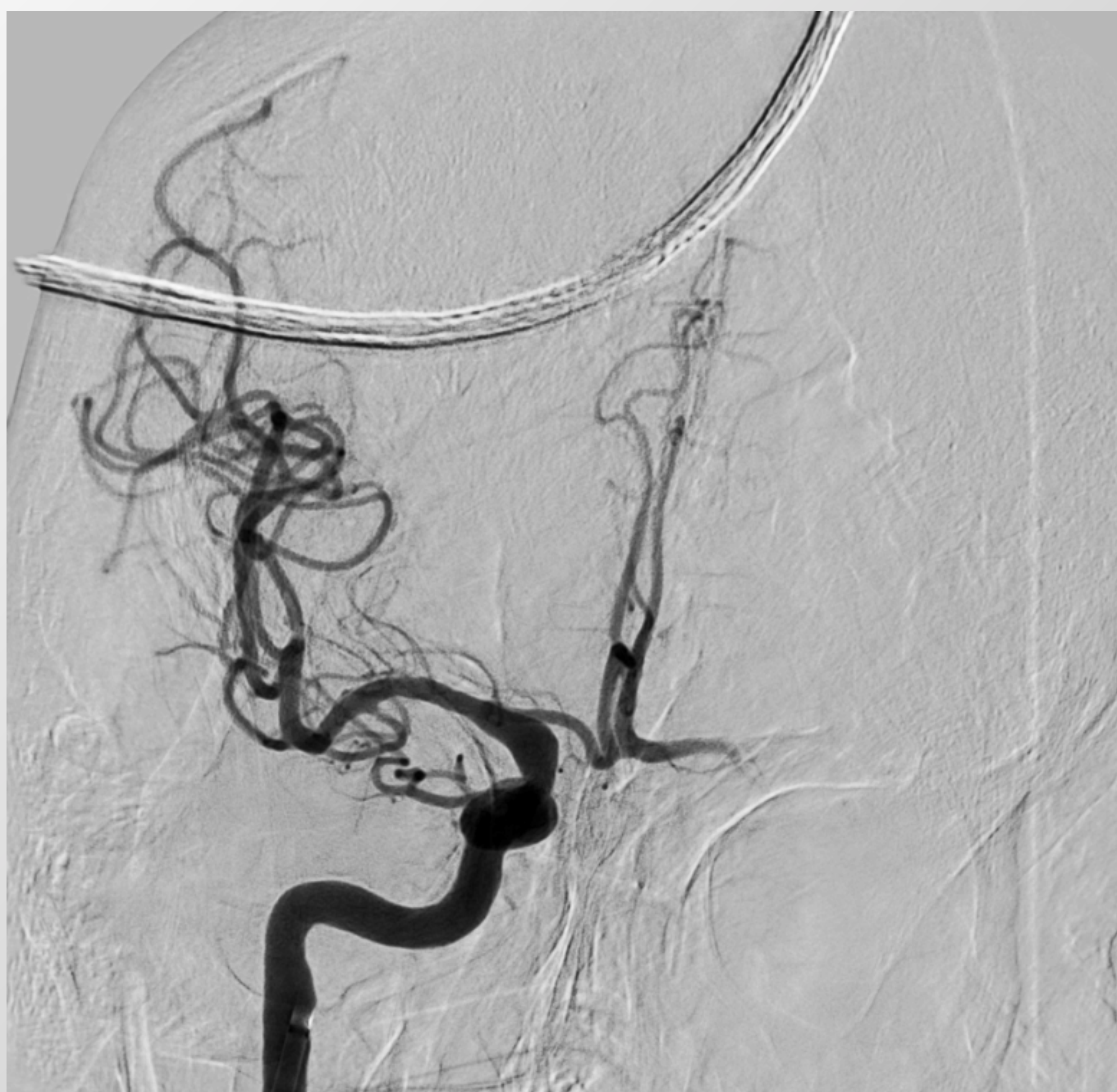- 90 y/o
- NIHSS 16

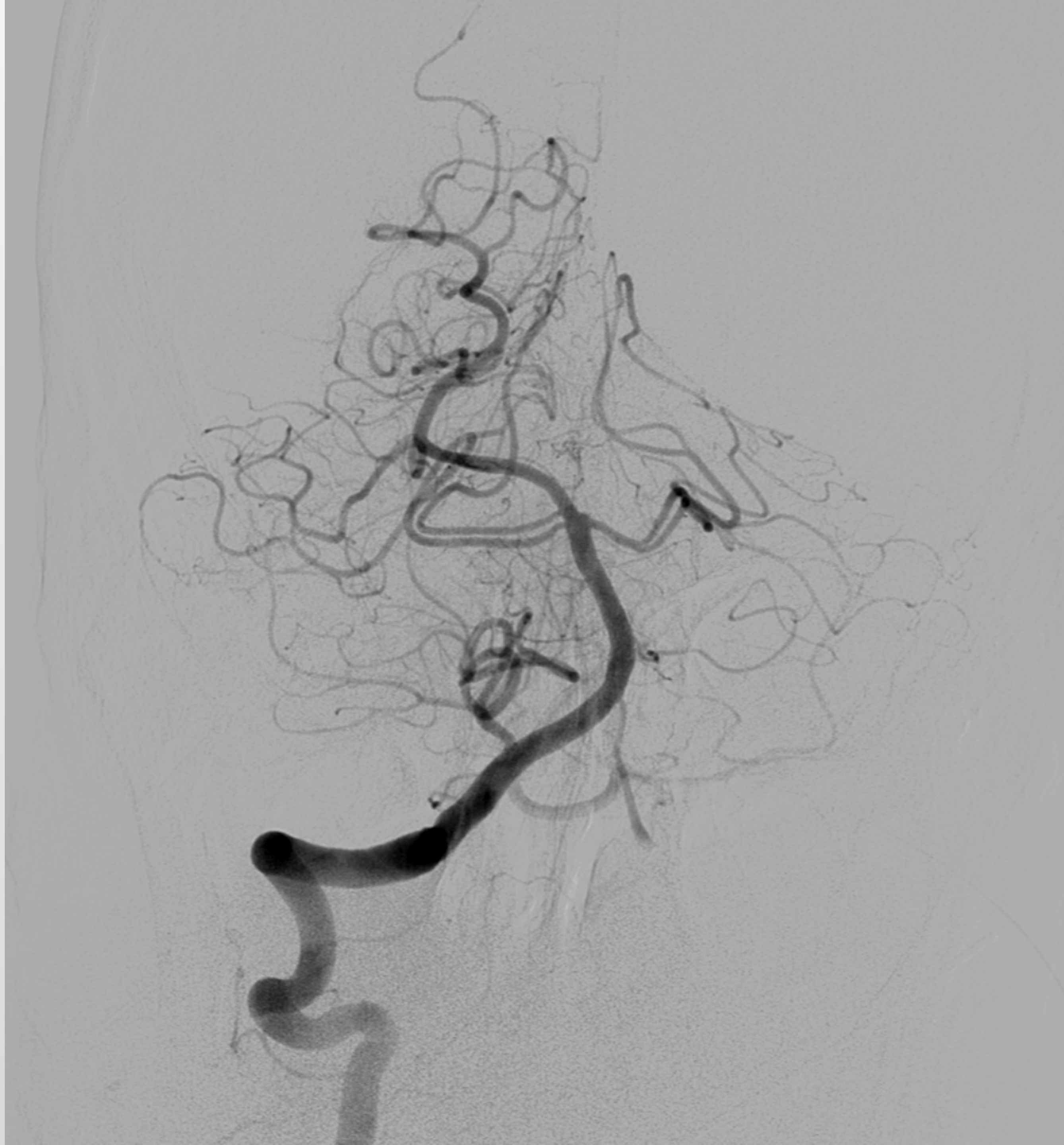

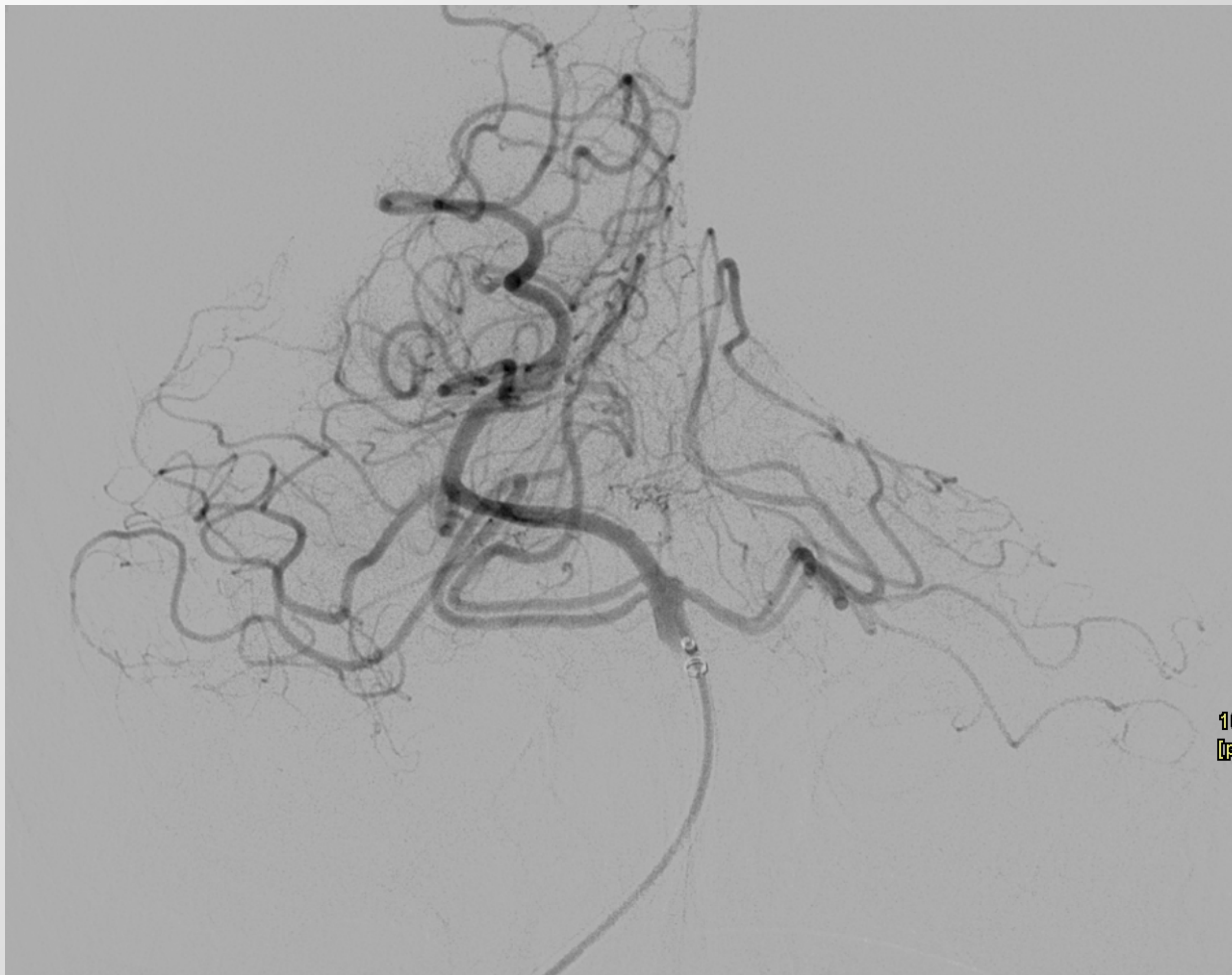


- P: 0:13h.
- TICI 3: 1:10h.
- NIHSS 24h: 7

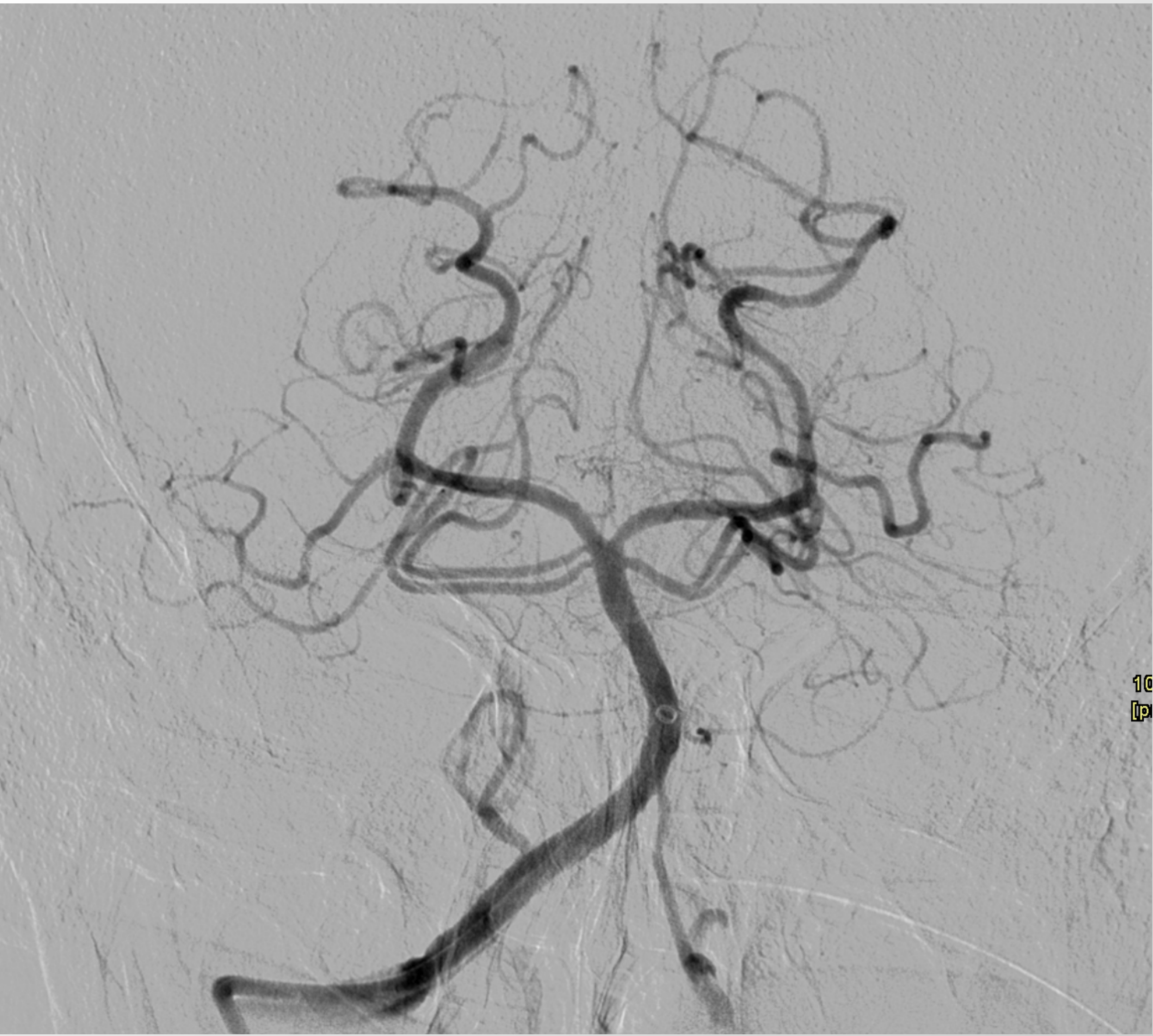

- 80 y/o
- NIHSS 11
- Wake up
- P.- 11:51h.

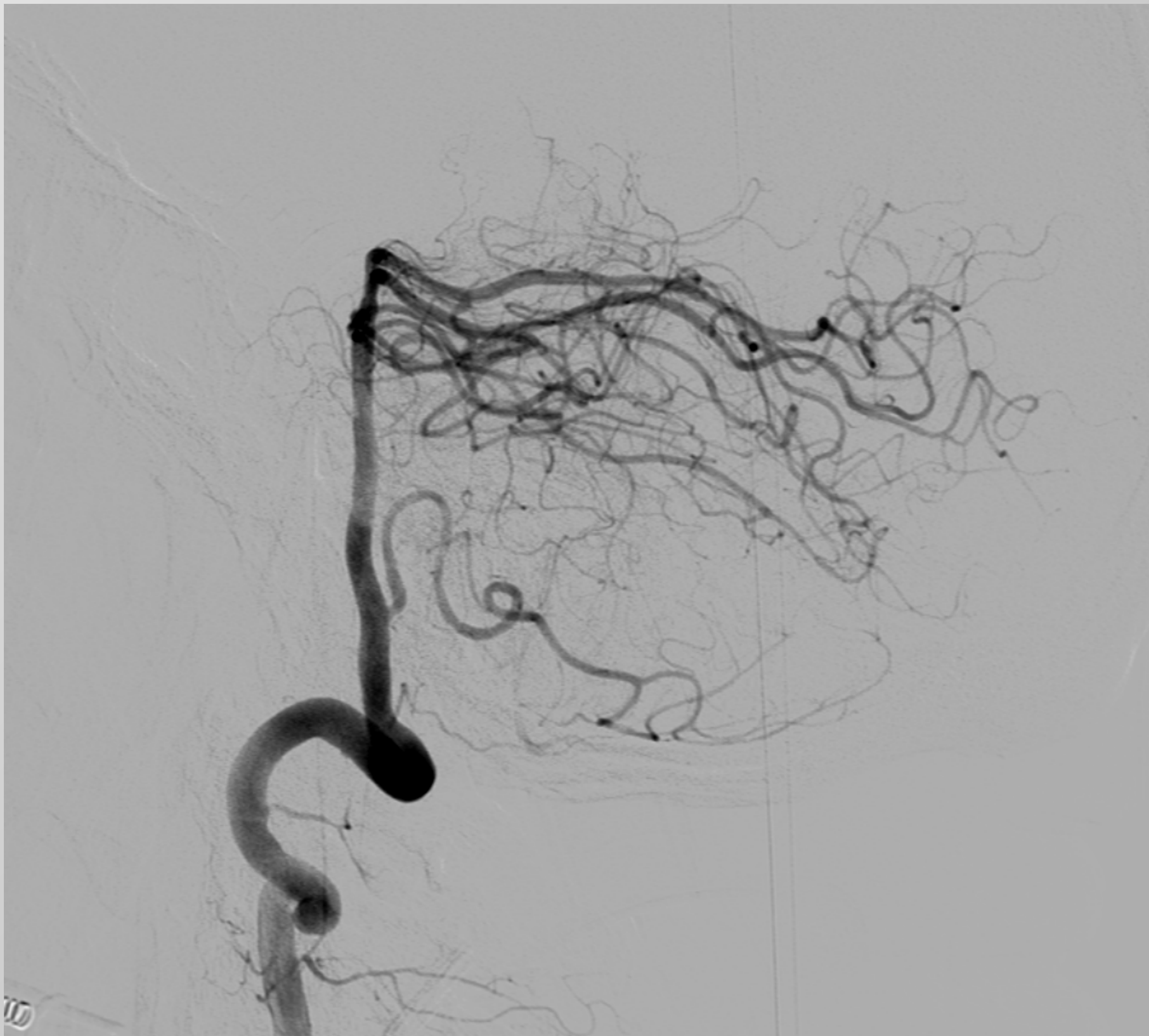




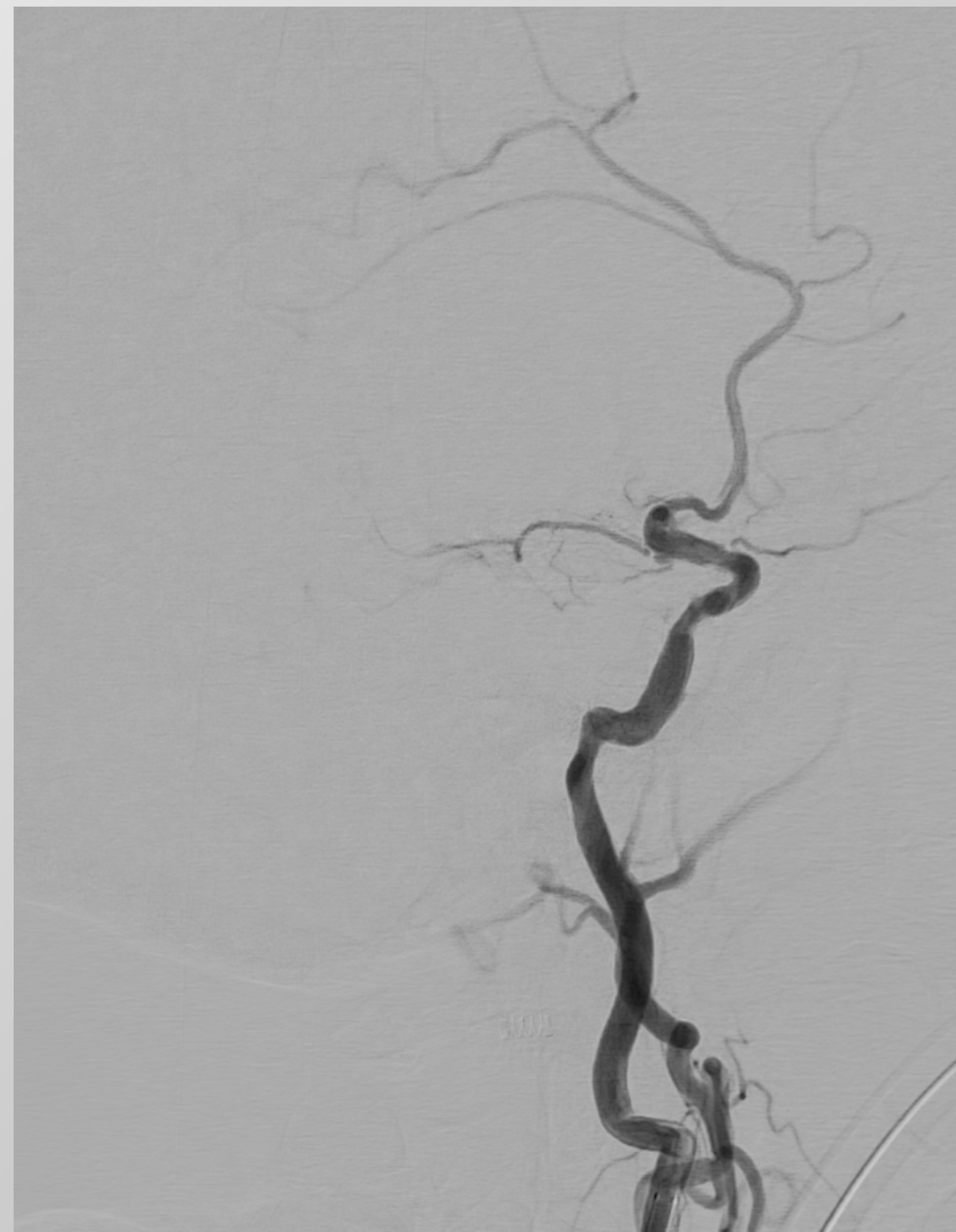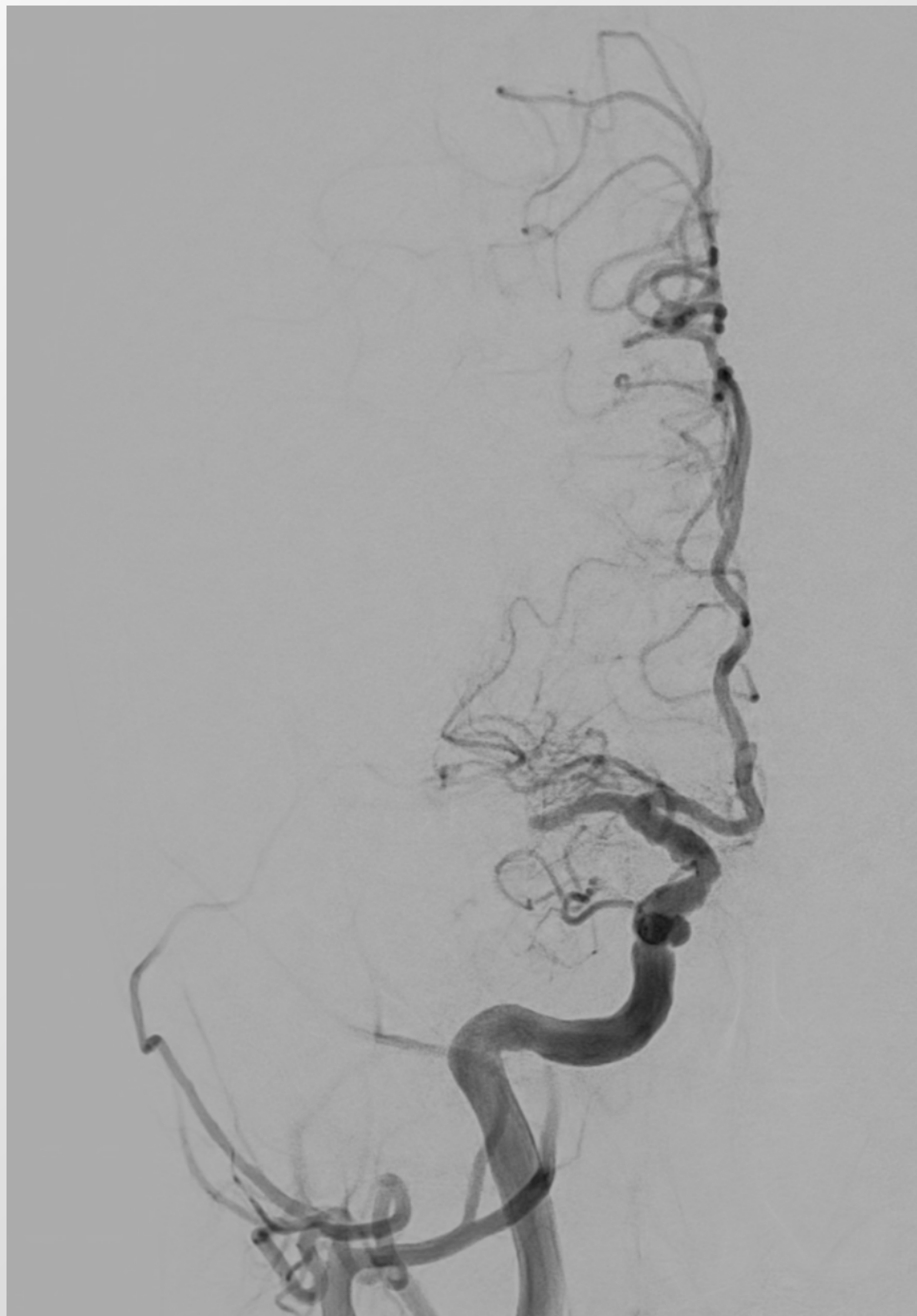
10
[p]



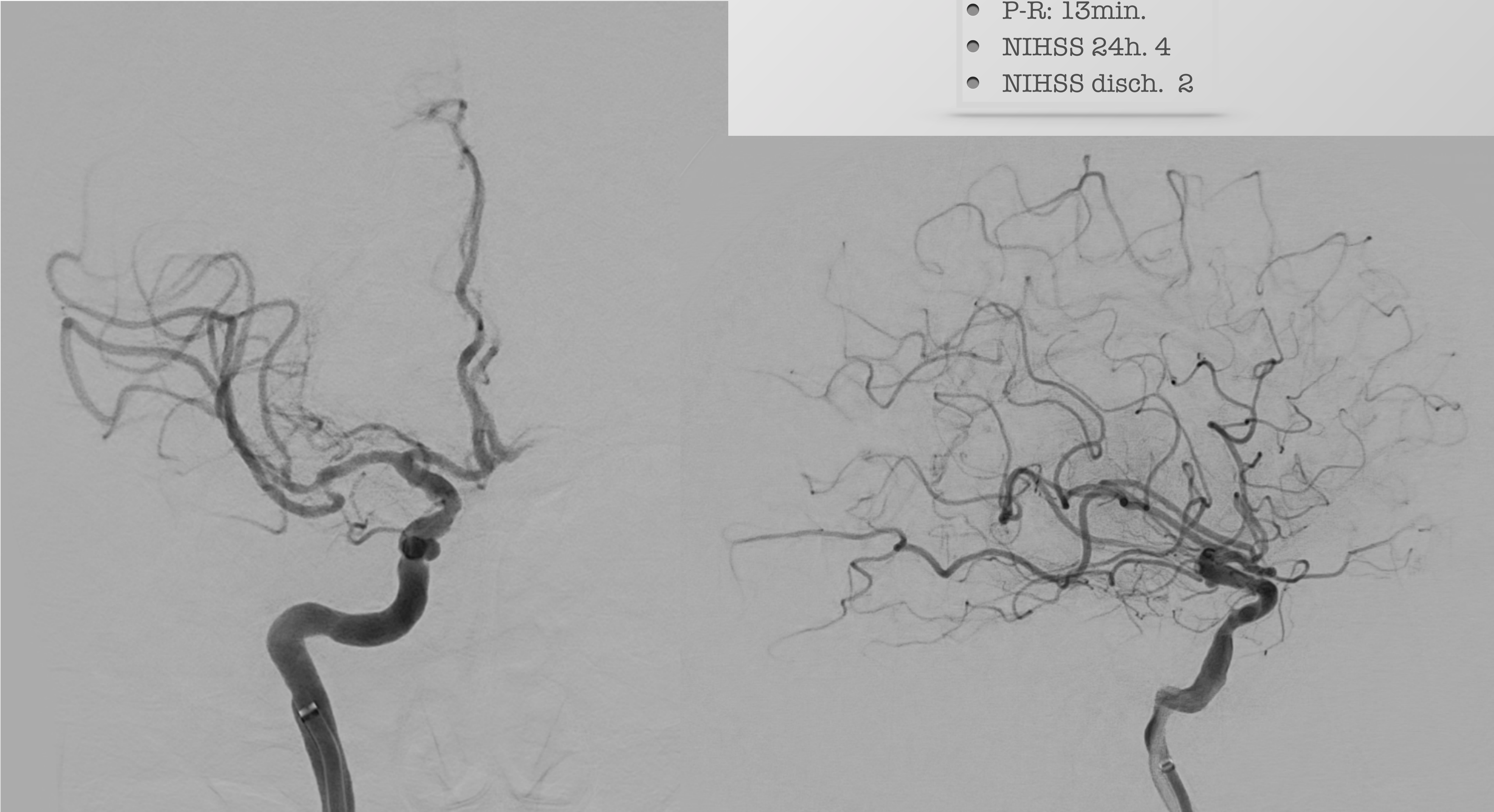
- TICI 3: 12:17h.
- NIHSS 24h. 4
- NIHSS disch. 0

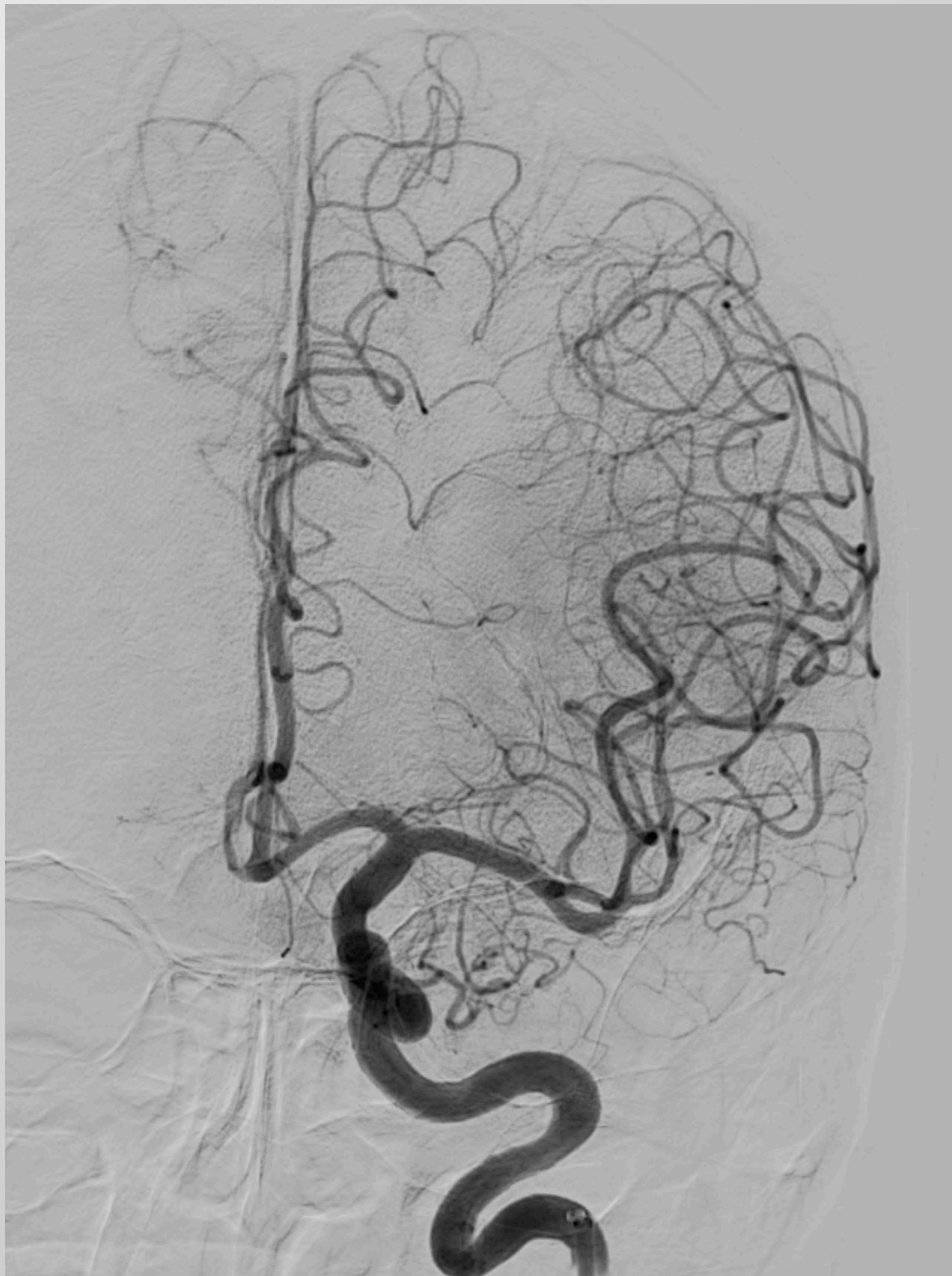
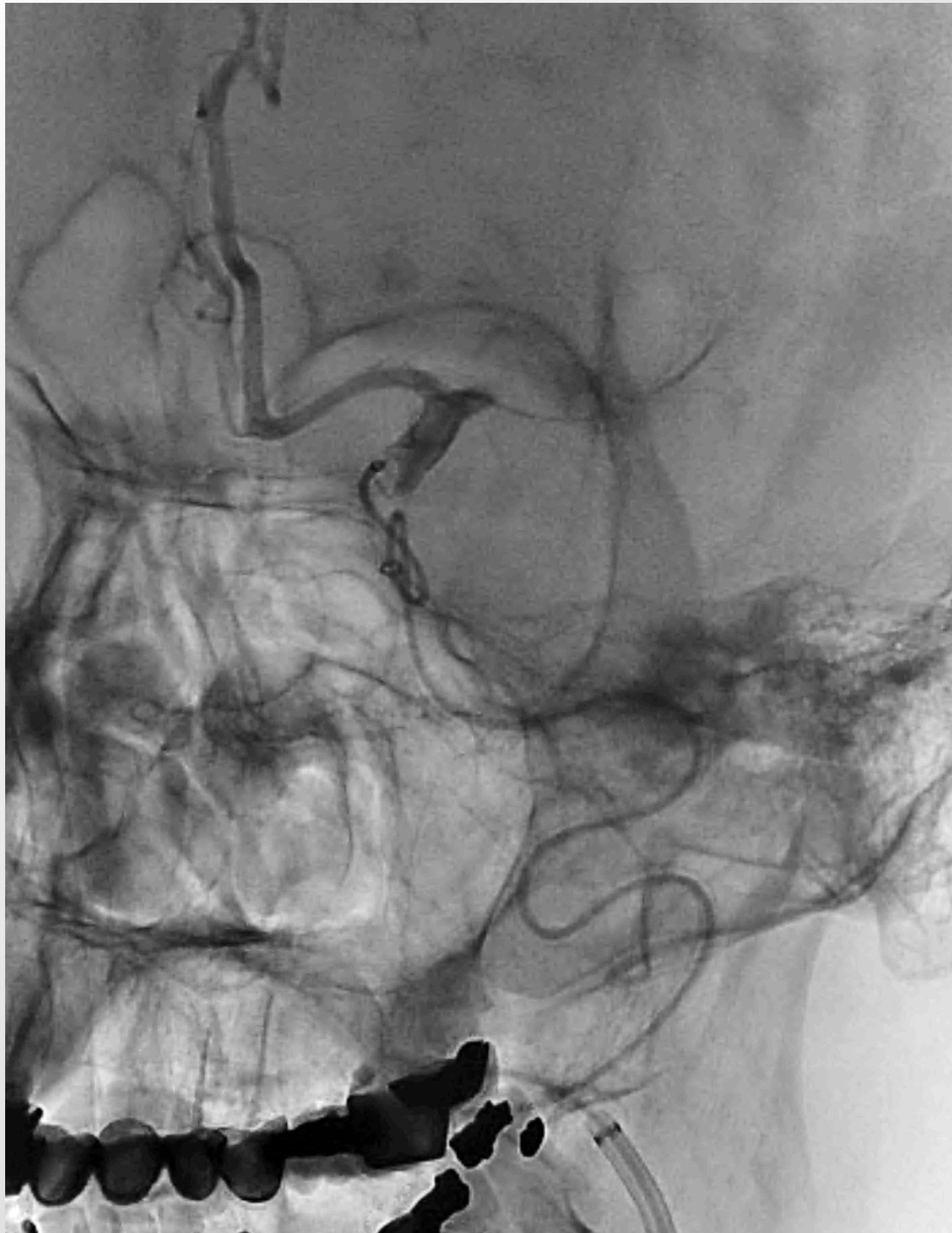
- 90 y/o
- NIHSS 8
- 18:00
- ASPECTS 8
- P.- 23:04h.

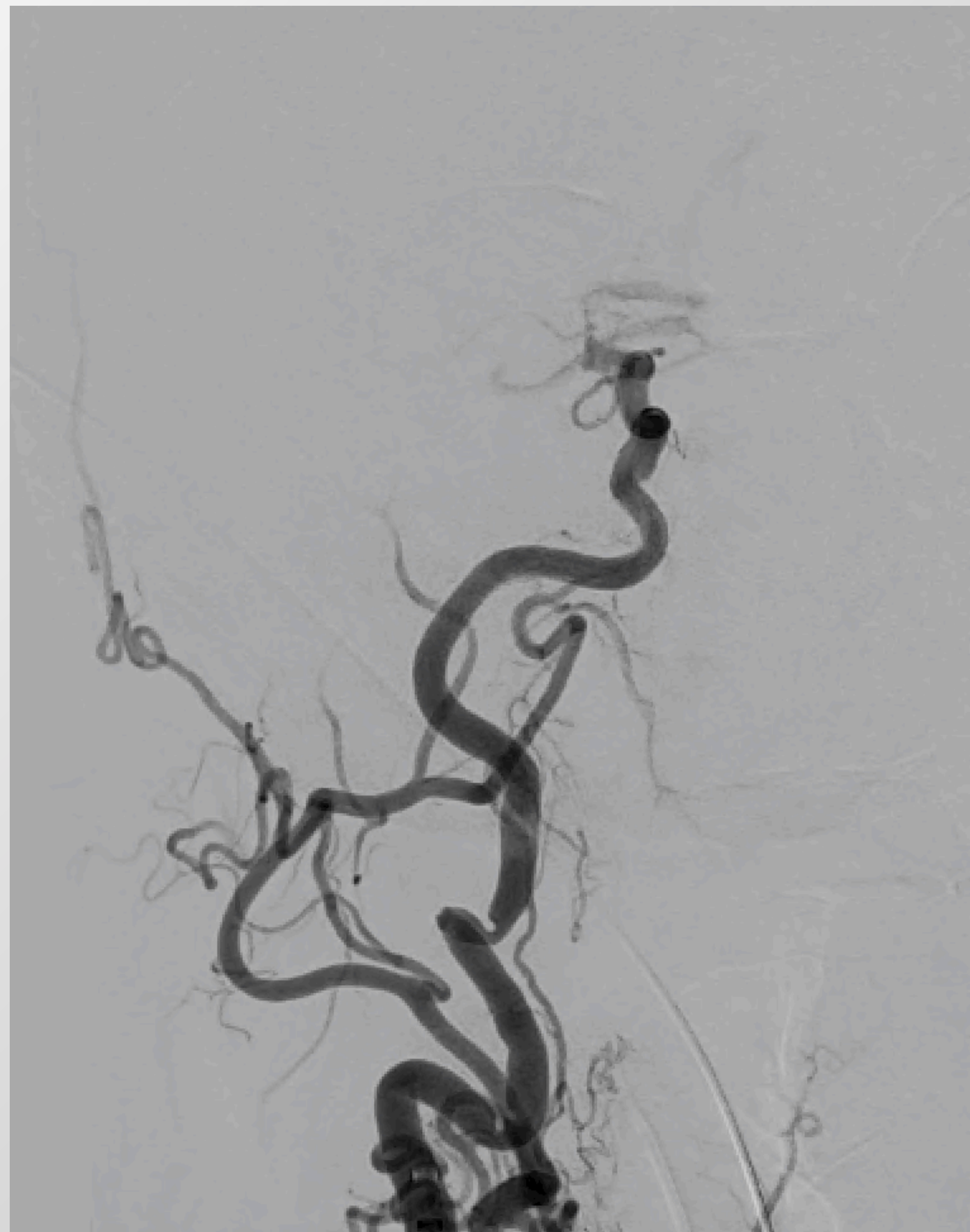


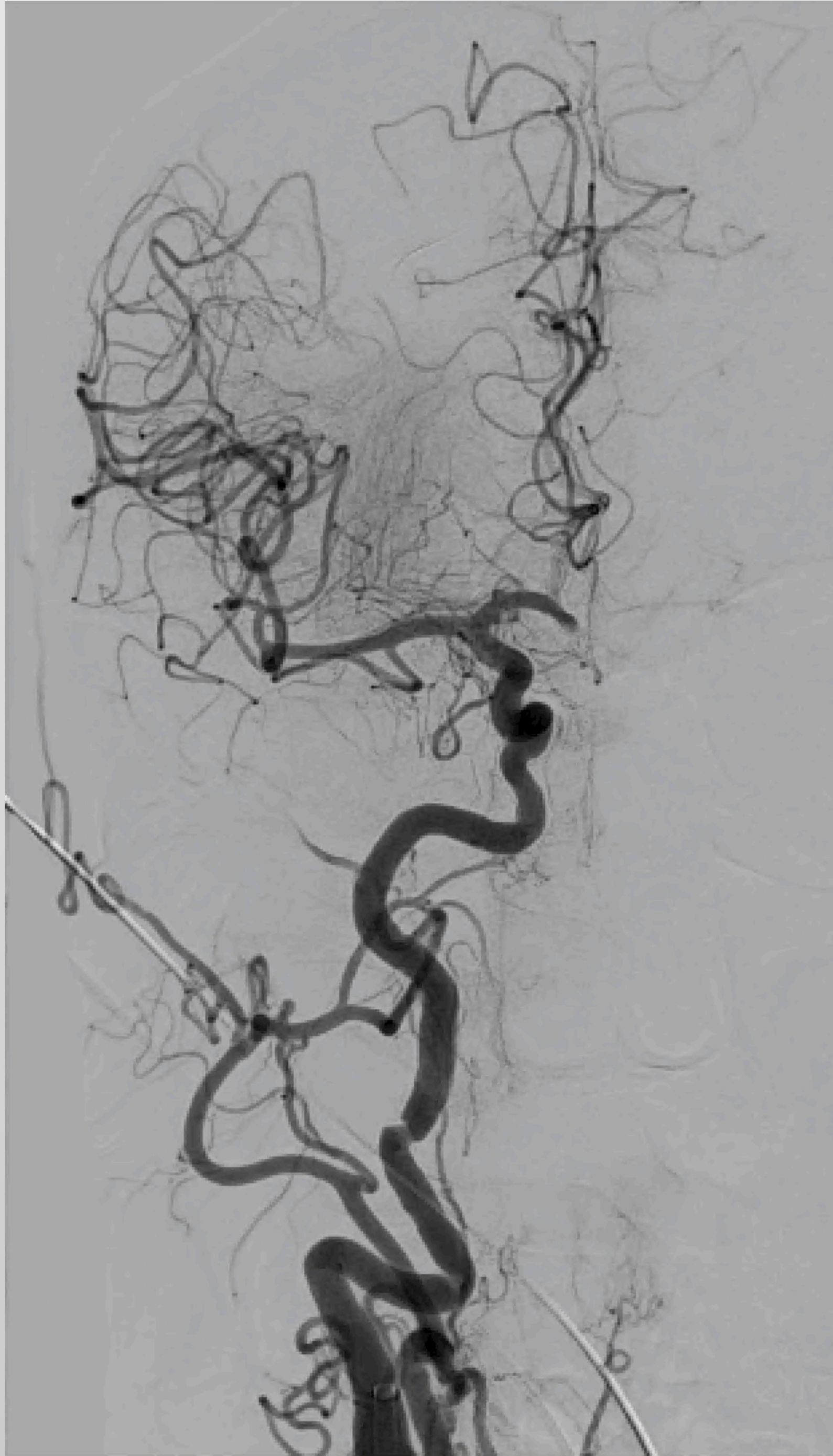
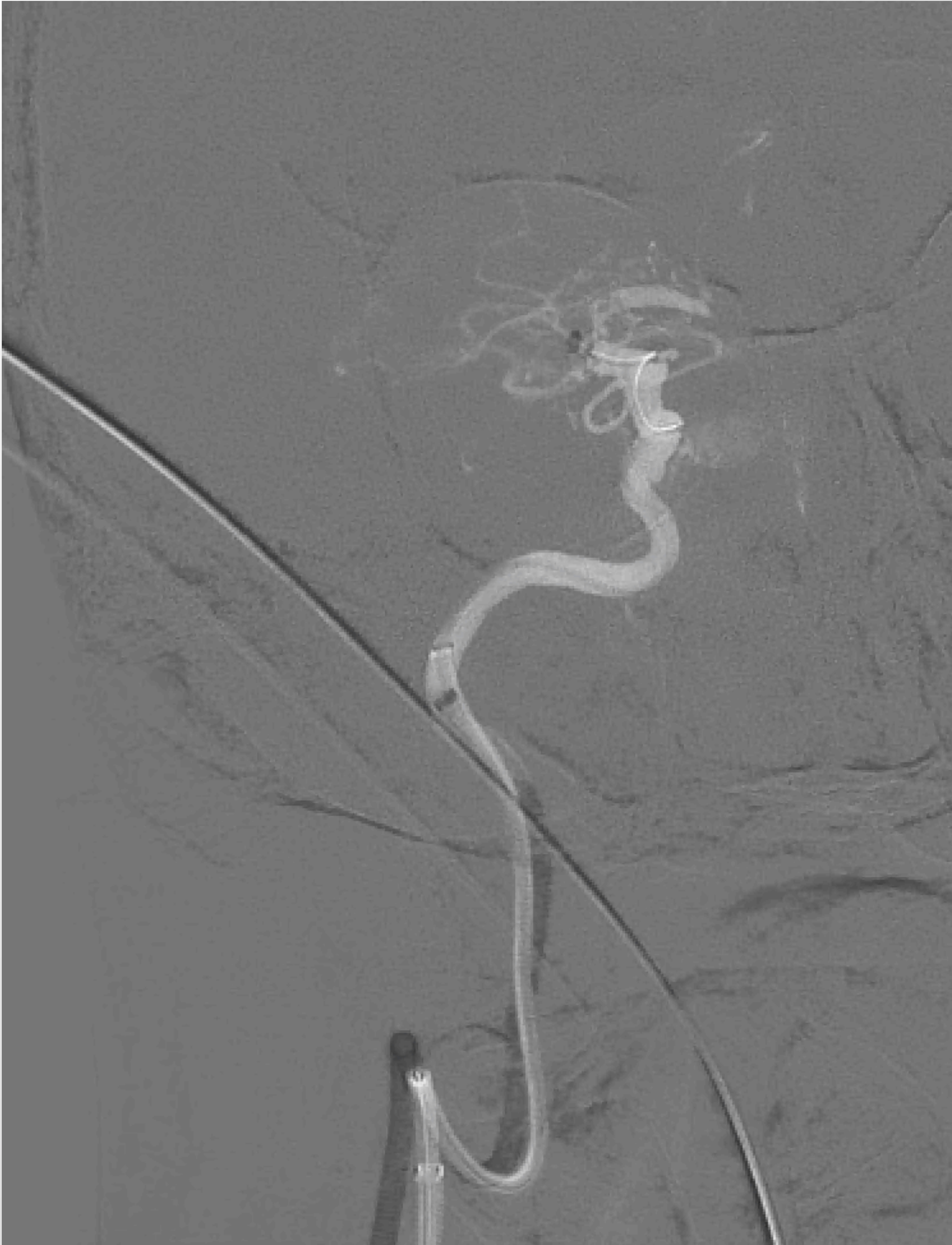- TICI 3: 23:17h.
- P-R: 13min.
- NIHSS 24h. 4
- NIHSS disch. 2

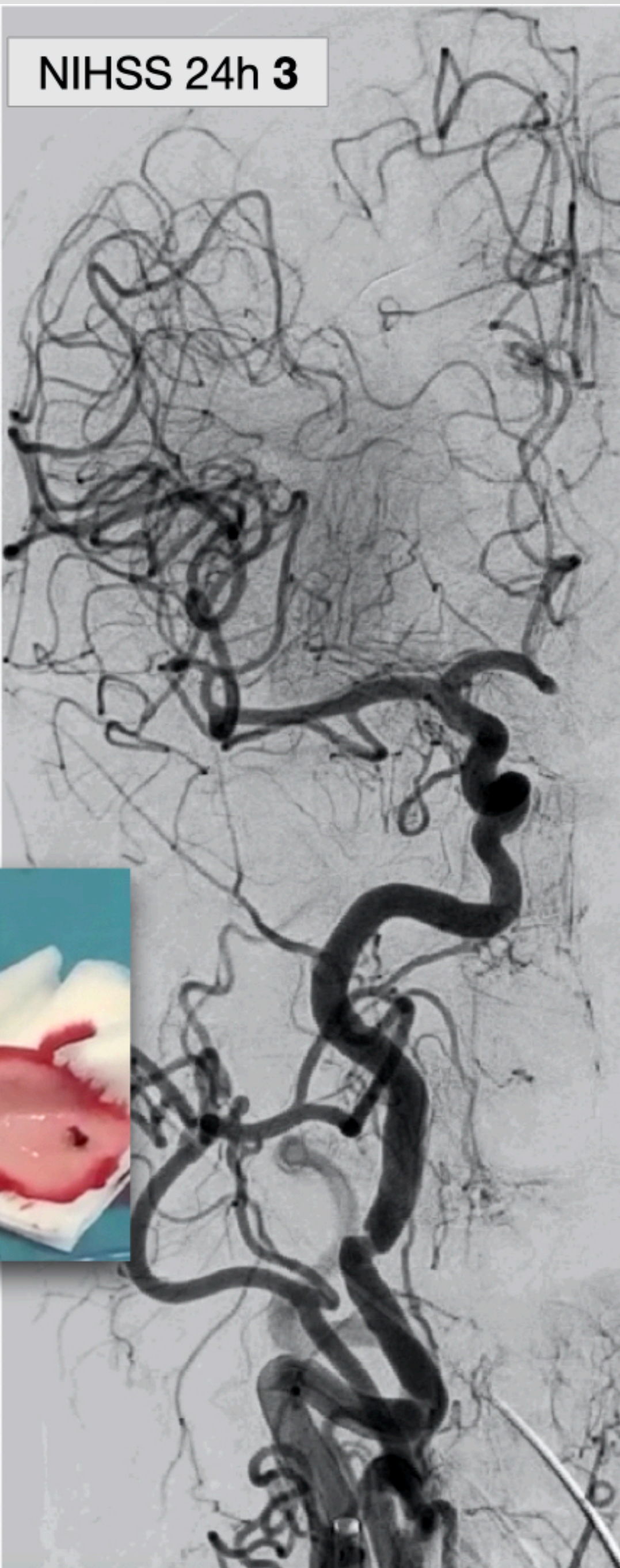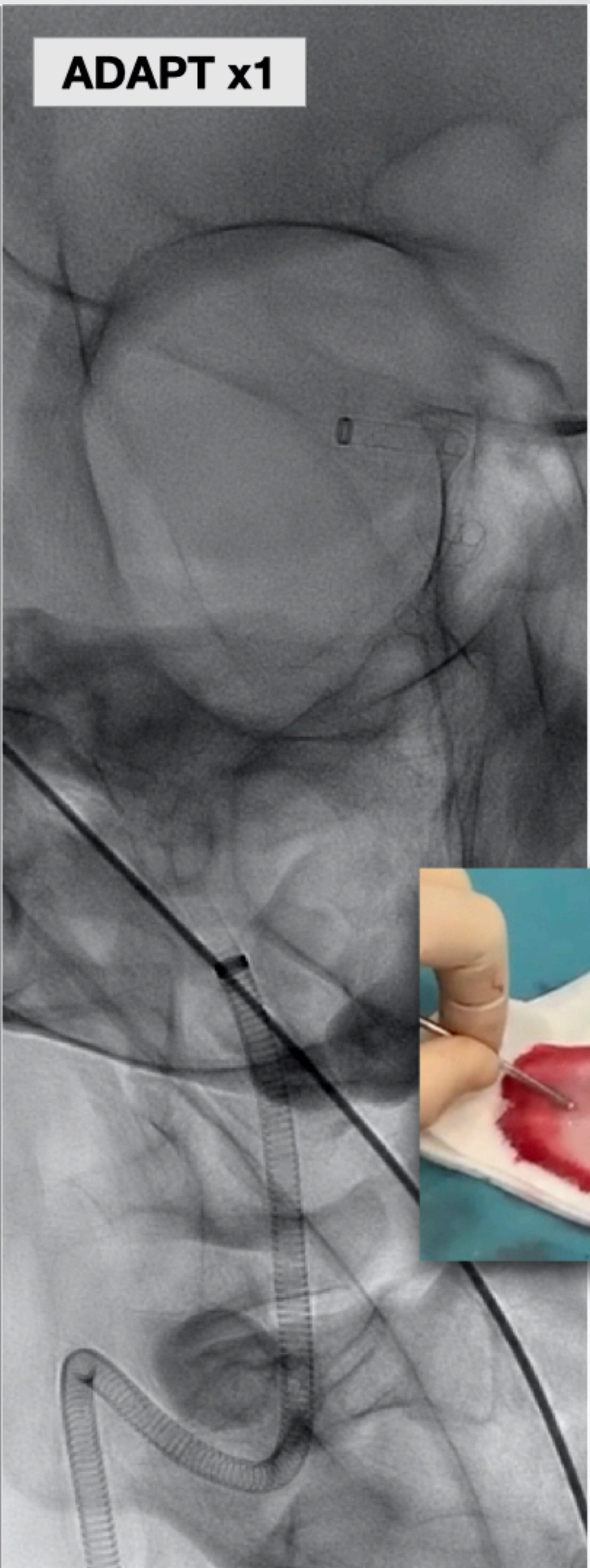
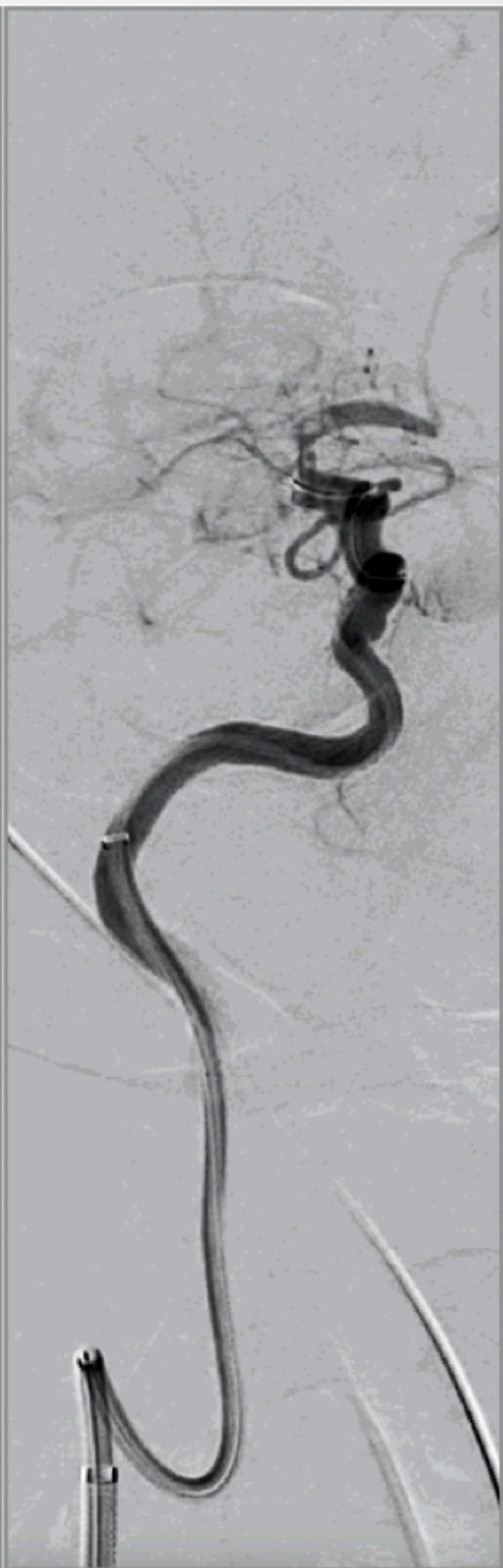
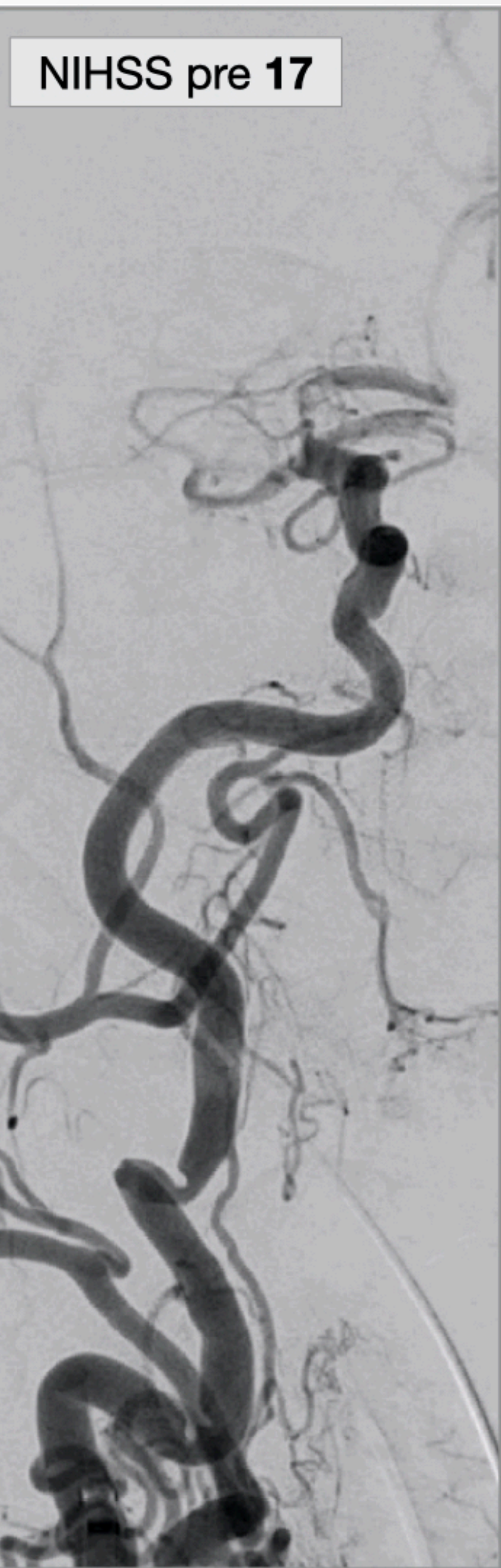




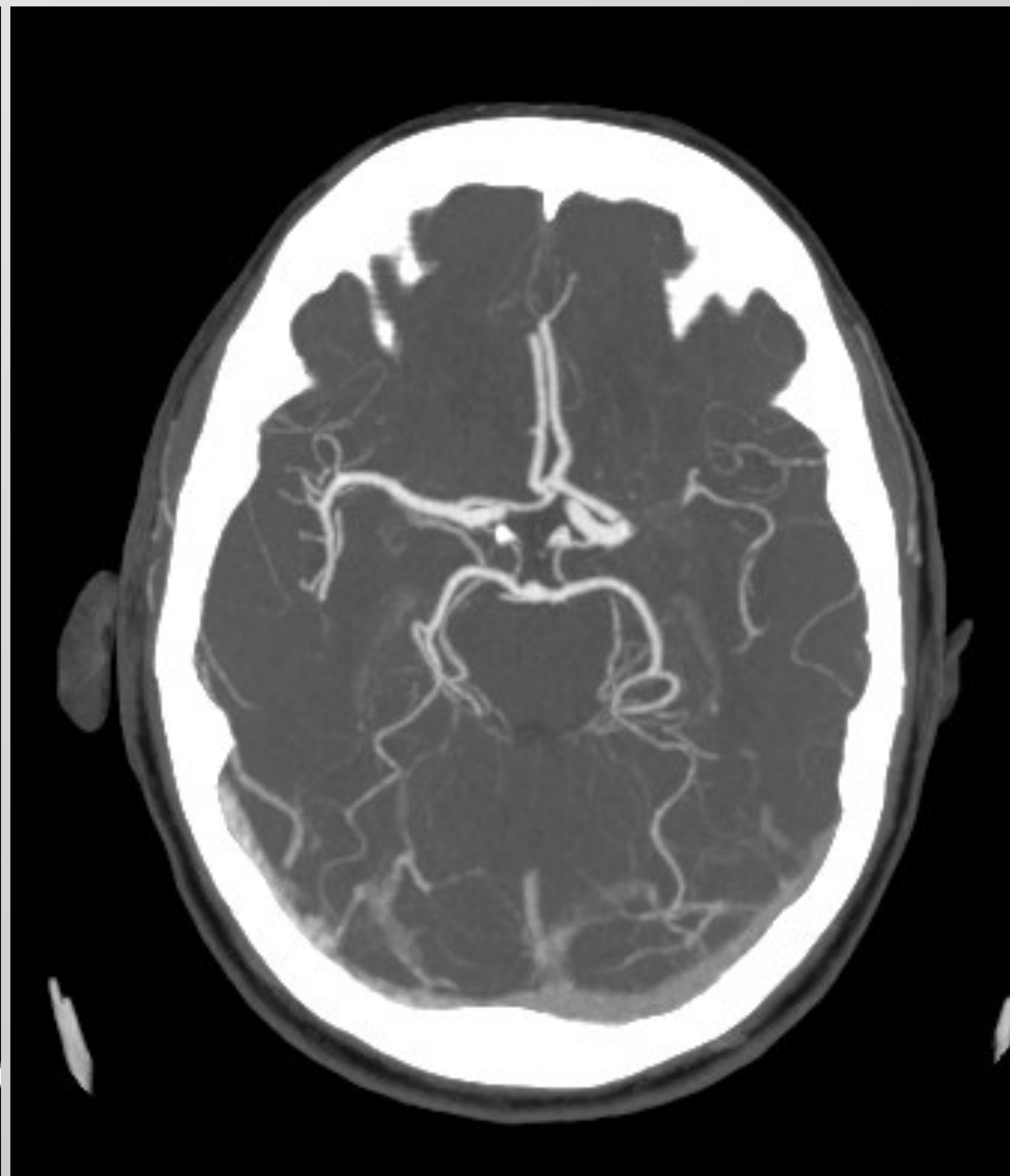
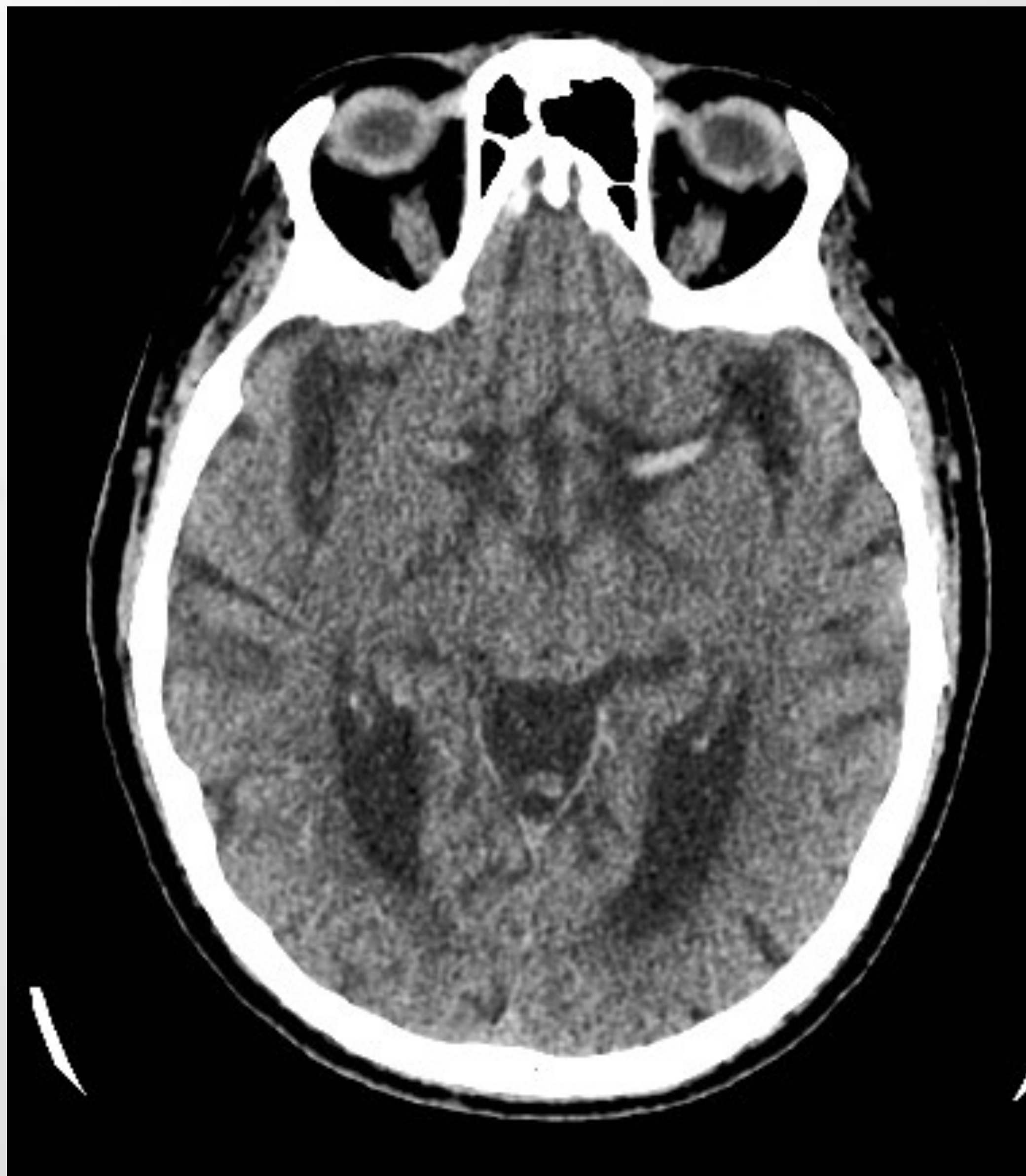- 69 y/o
- NIHSS 17
- 19:00
- ASPECTS 7
- P.- 23:15h.

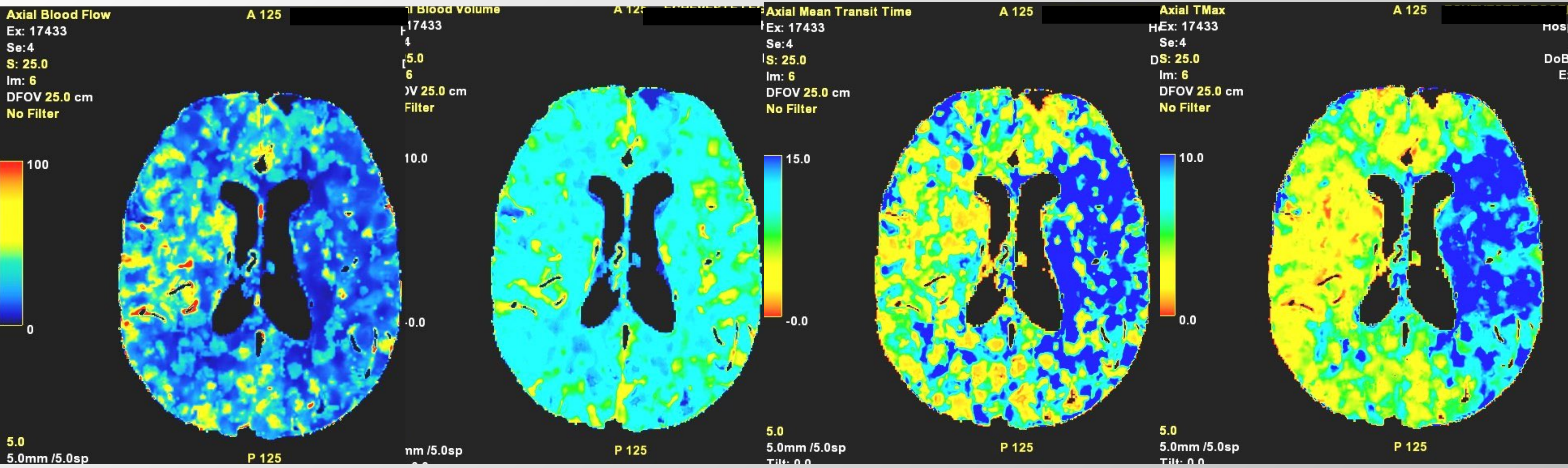




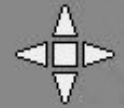

- 82 y/o
- mRS 2
- **Despertar**
- NIHSS 12
- ASPECTS 10





Rot +8°
Áng -8°
FD 31 cm



0:00
2:67
13:30:13

Rot -90°
Áng -0°
FD 25 cm



0:17
2:83
1-7 13:30:13

2
1-7

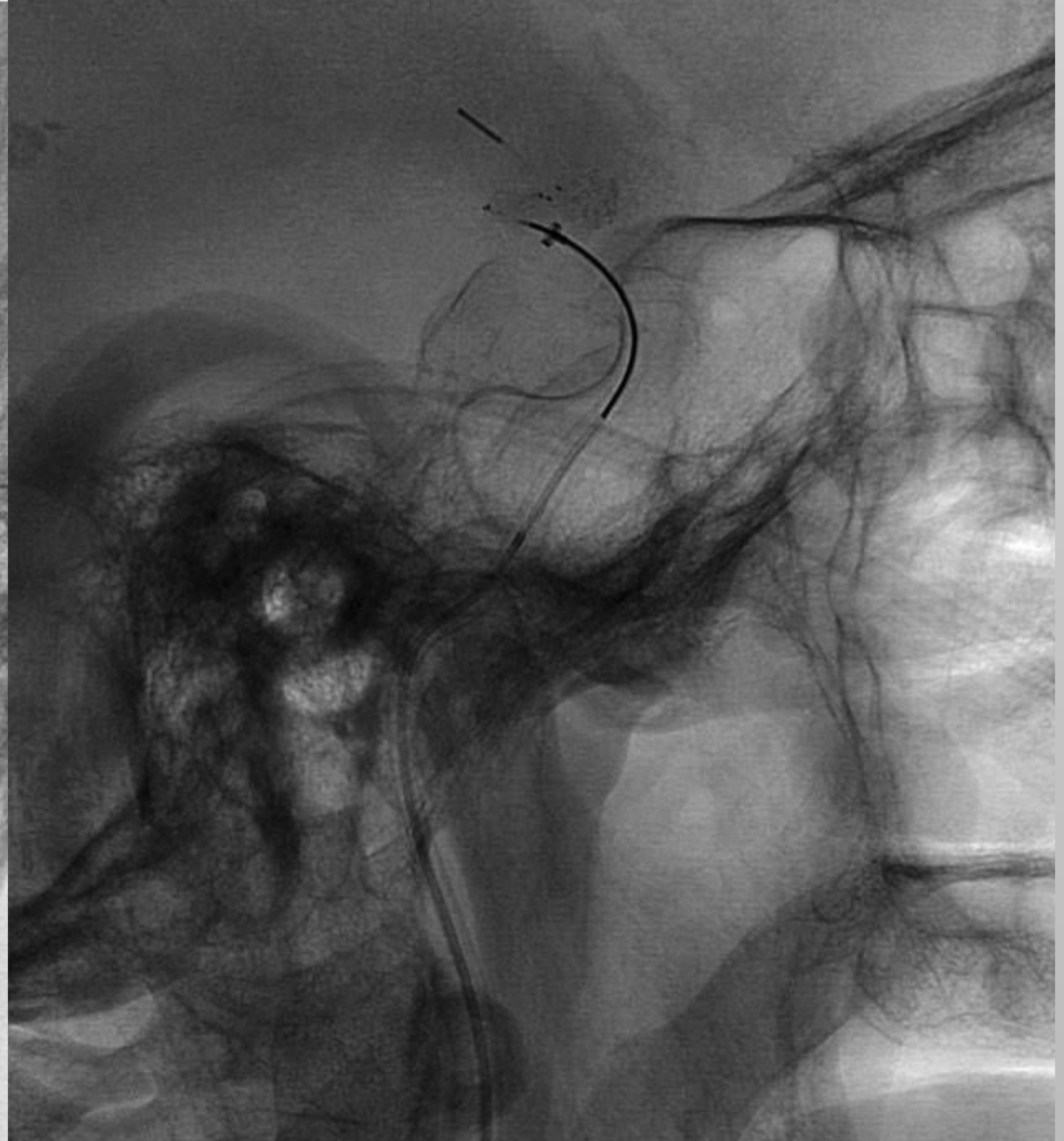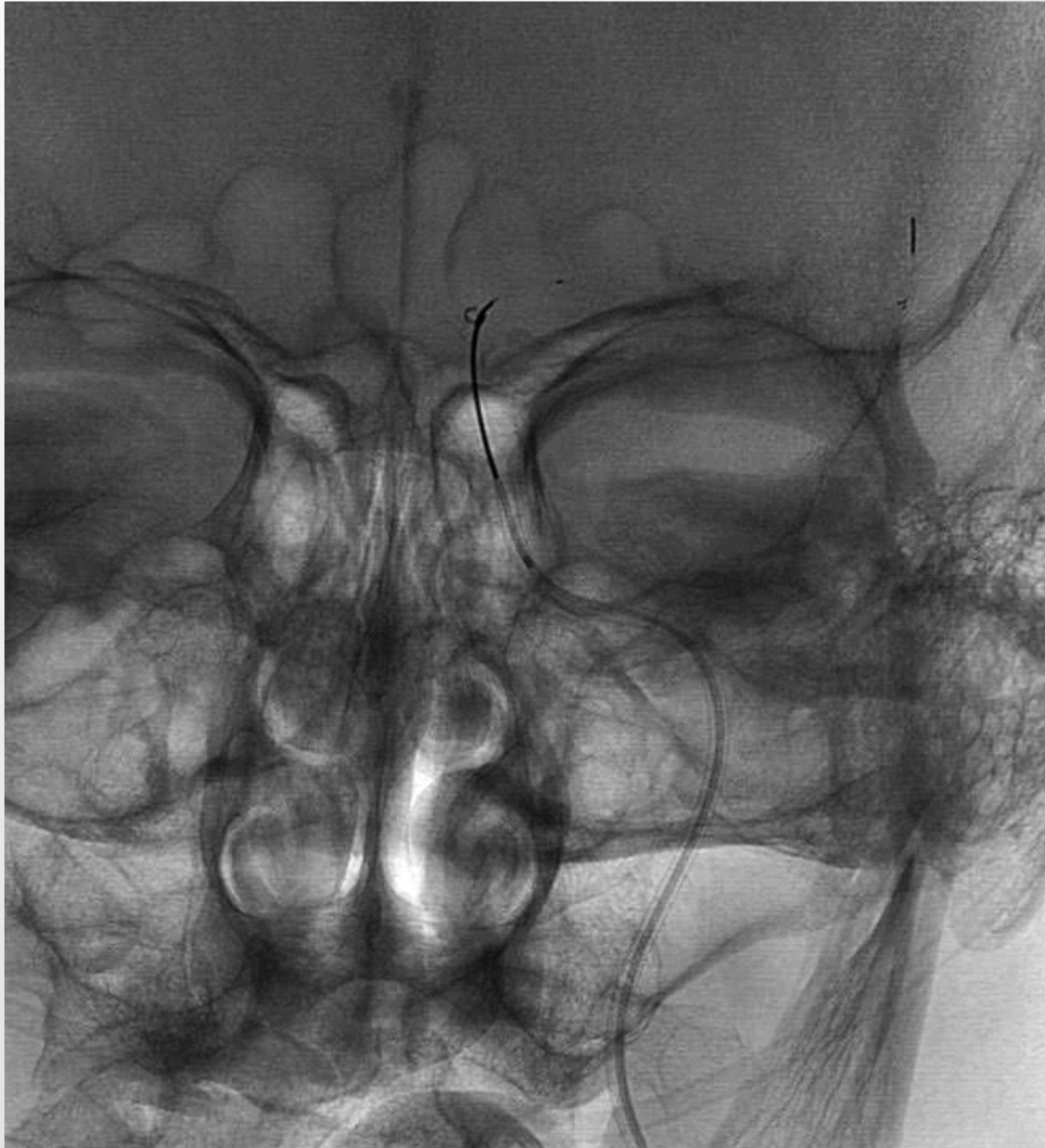Rot +8°
Áng -15°
FD 27 cm

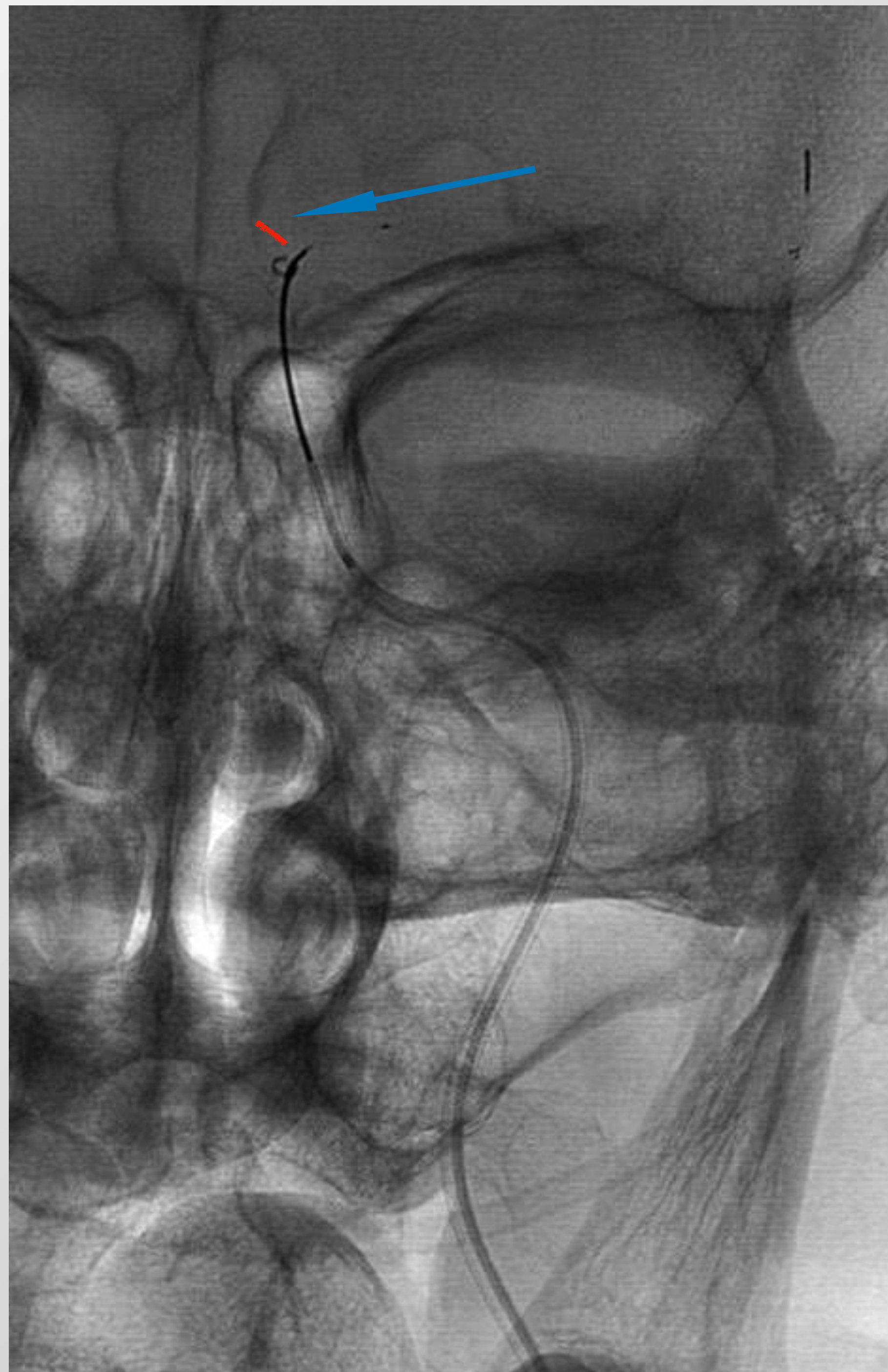


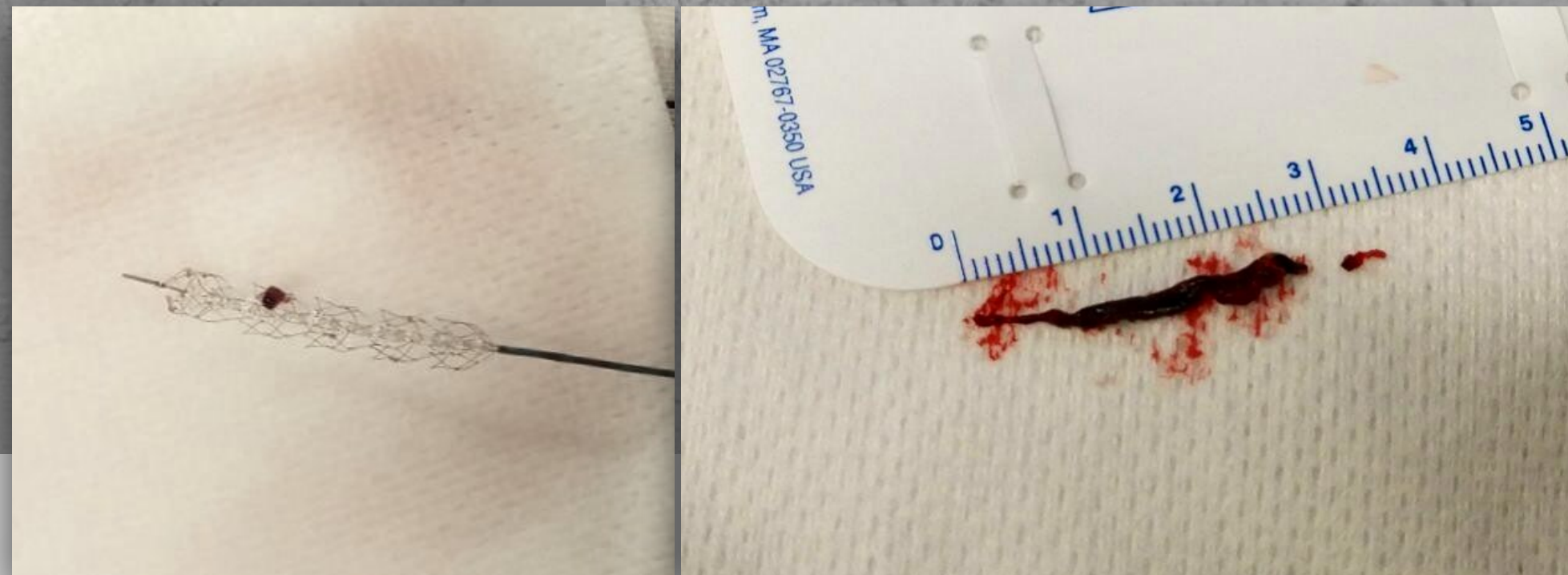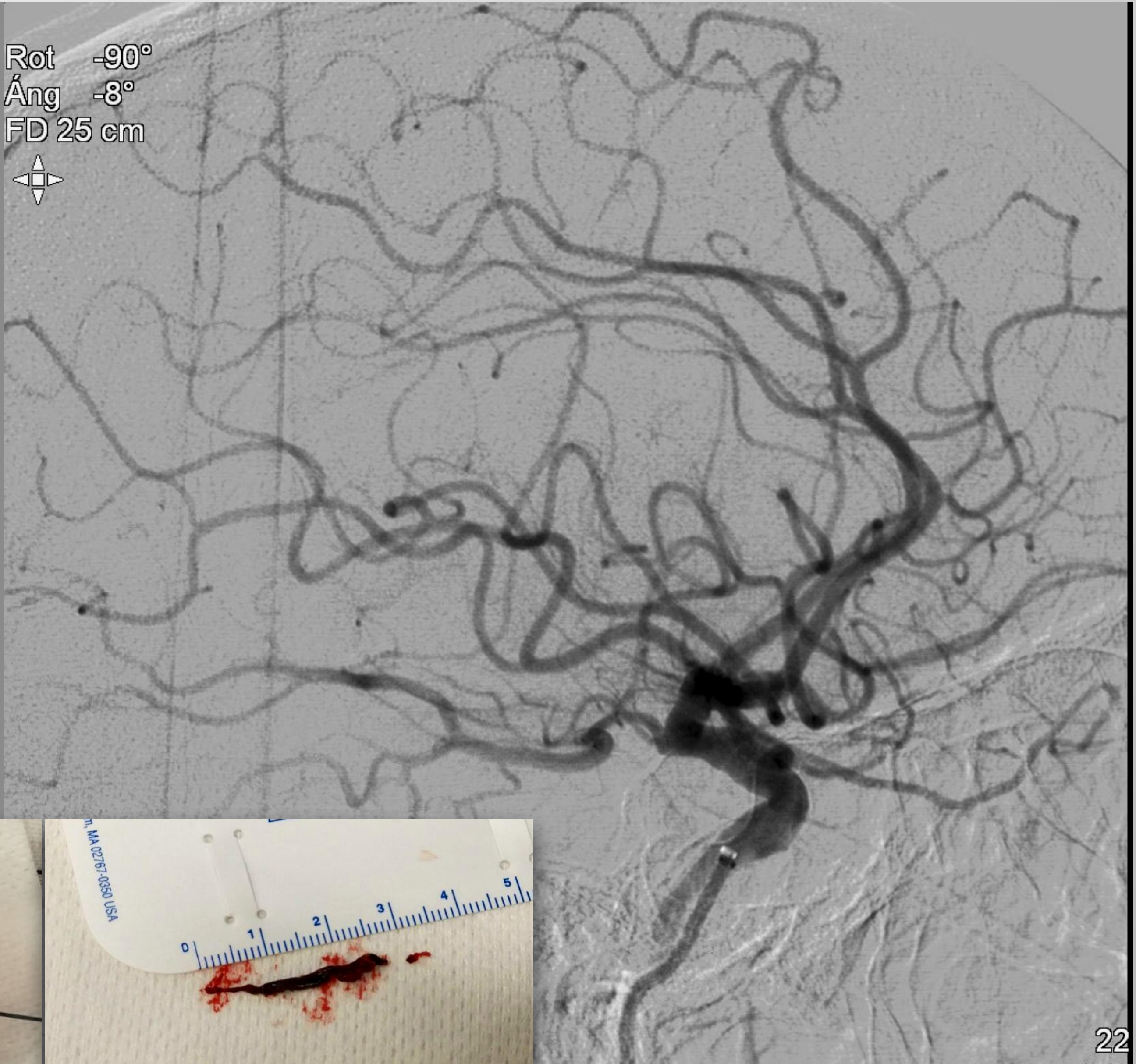
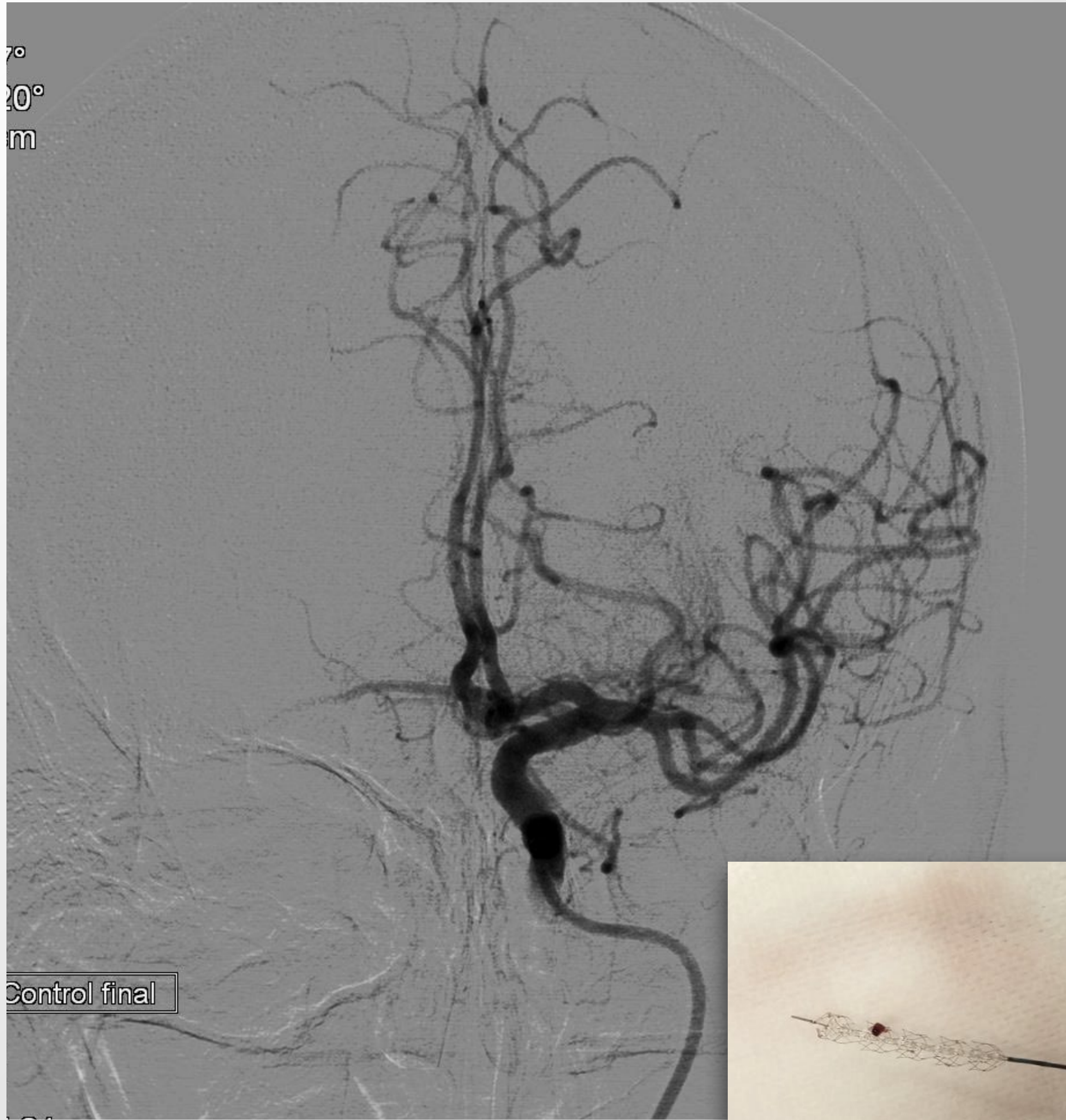
0:00
3:00

Rot -82°
Áng -1°
FD 25 cm

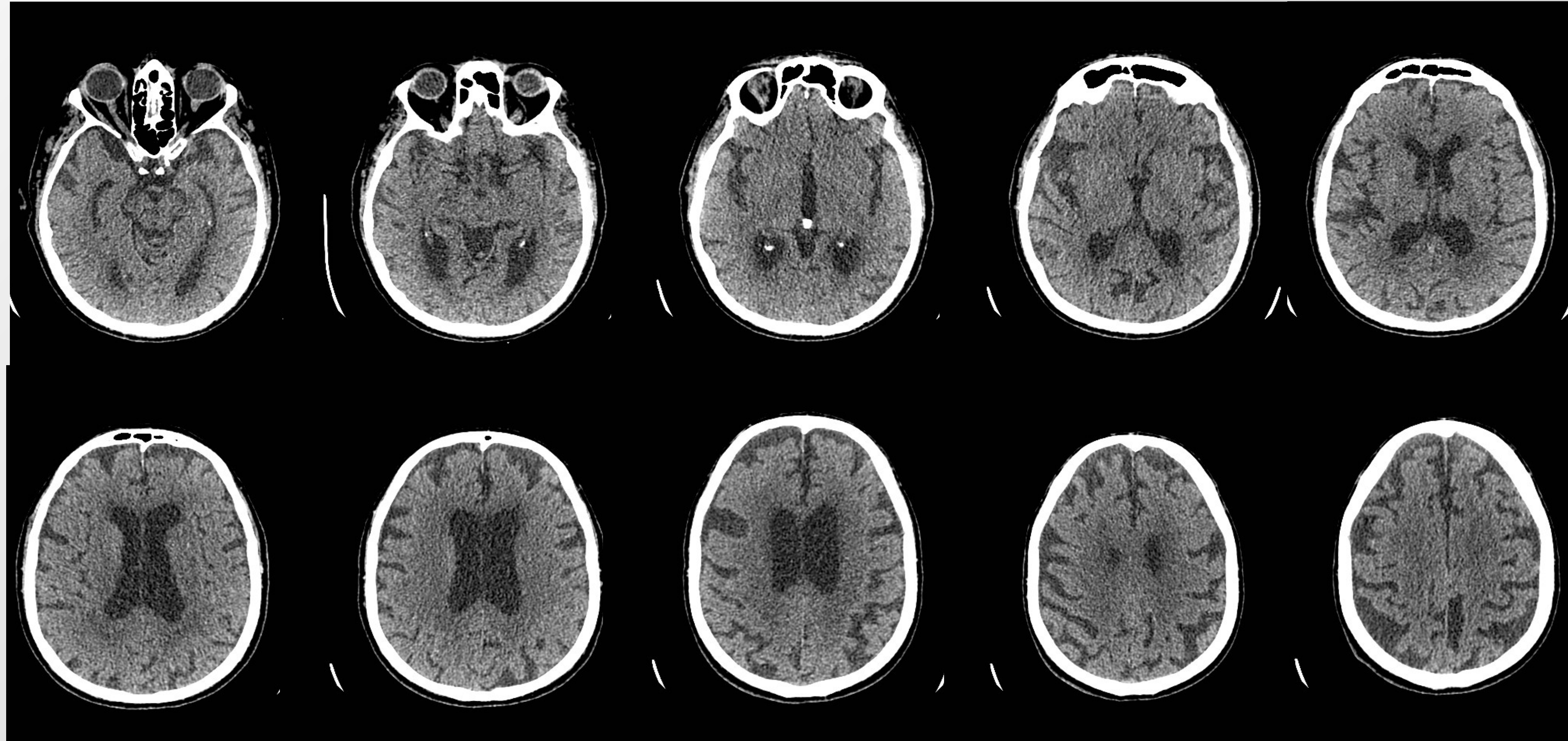
0:17
3:17



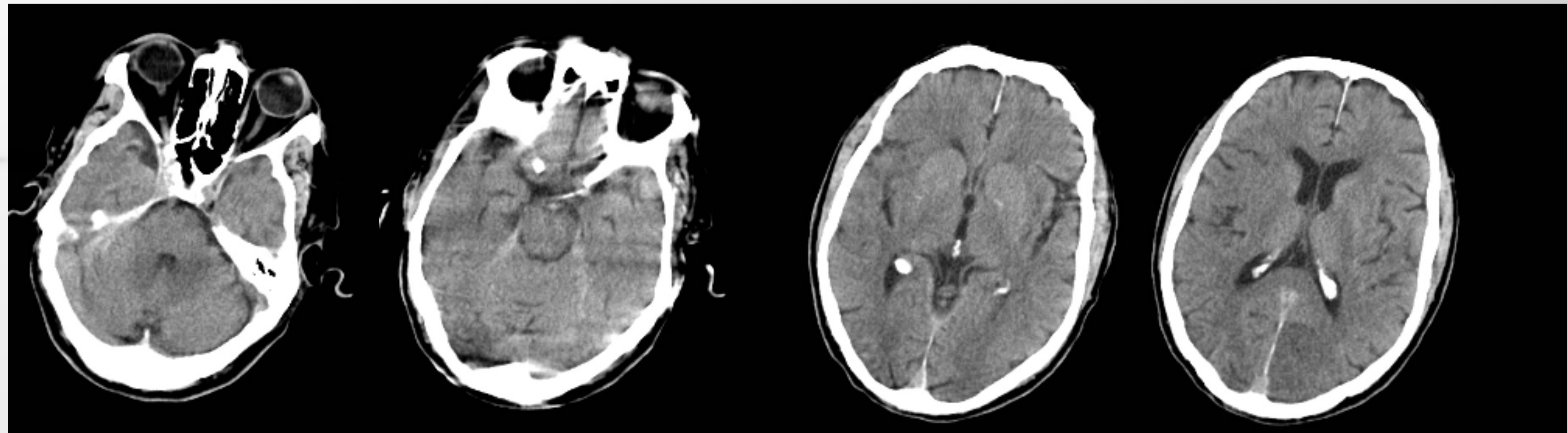



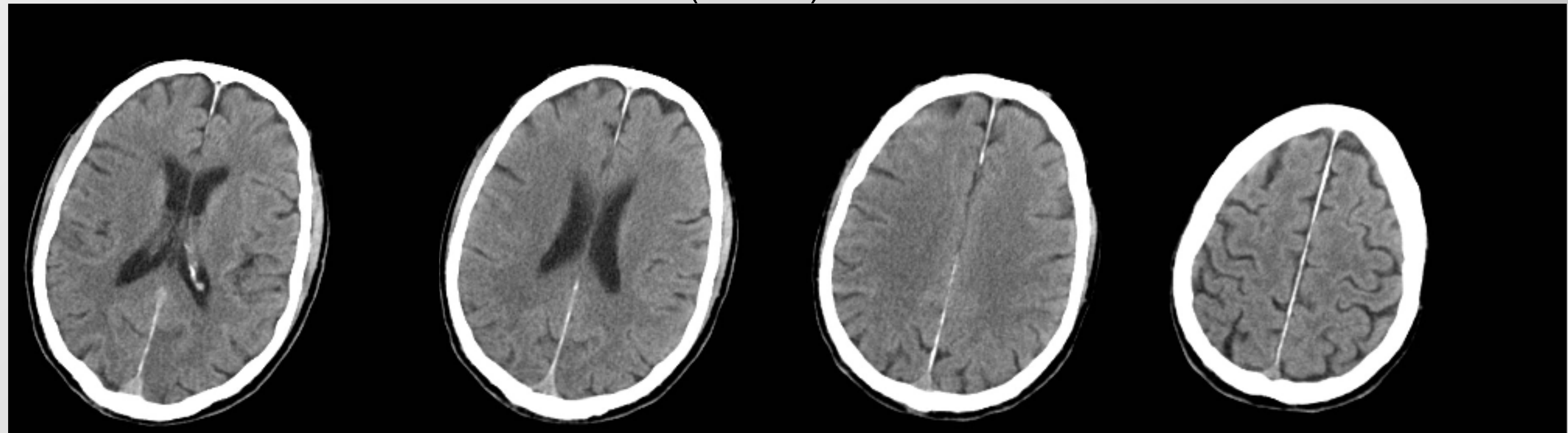
TC 24h

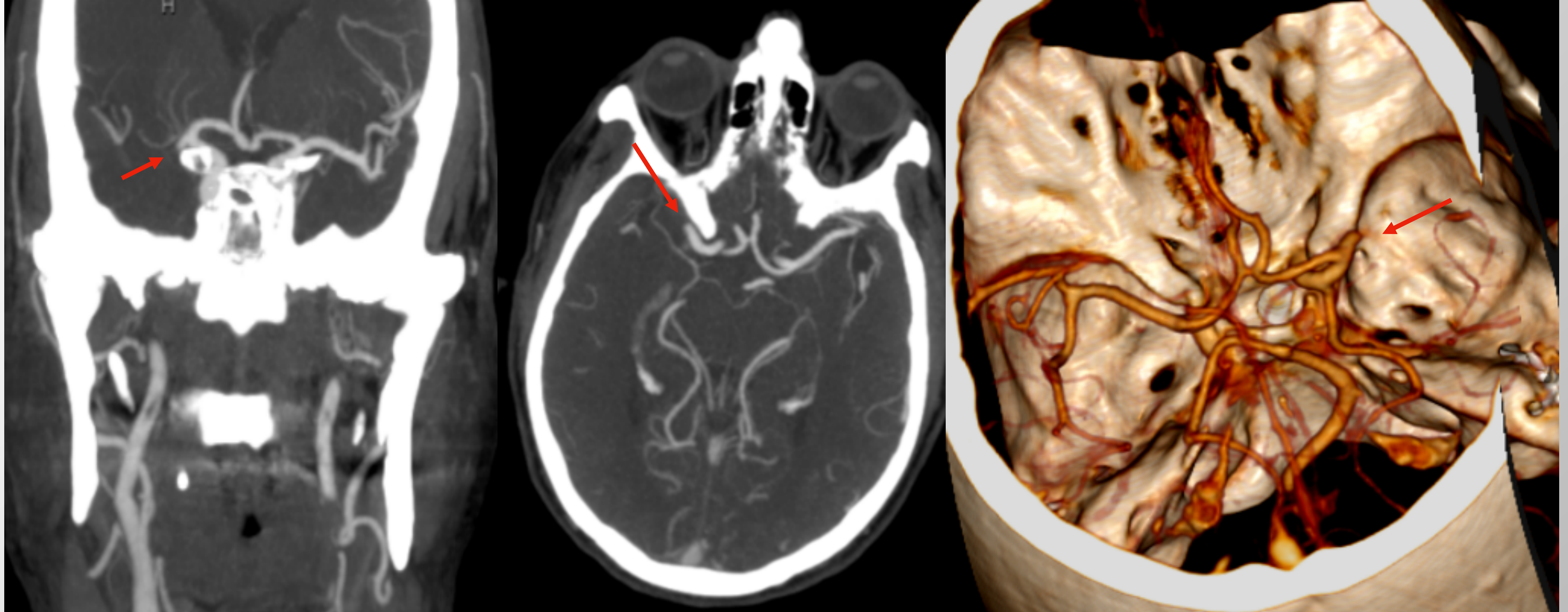


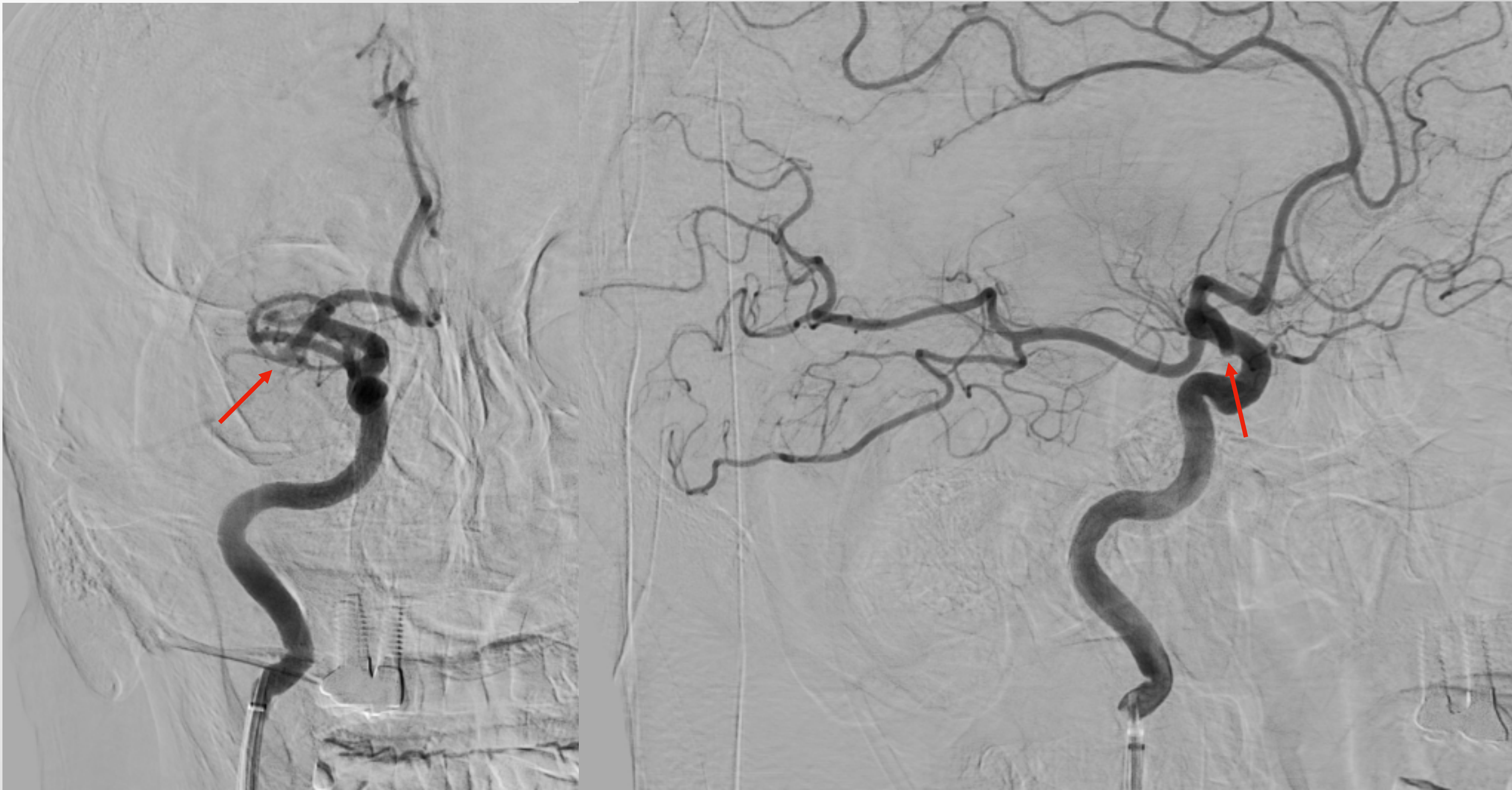
- 76 y/o
- NIHSS 18
- 14:05h.

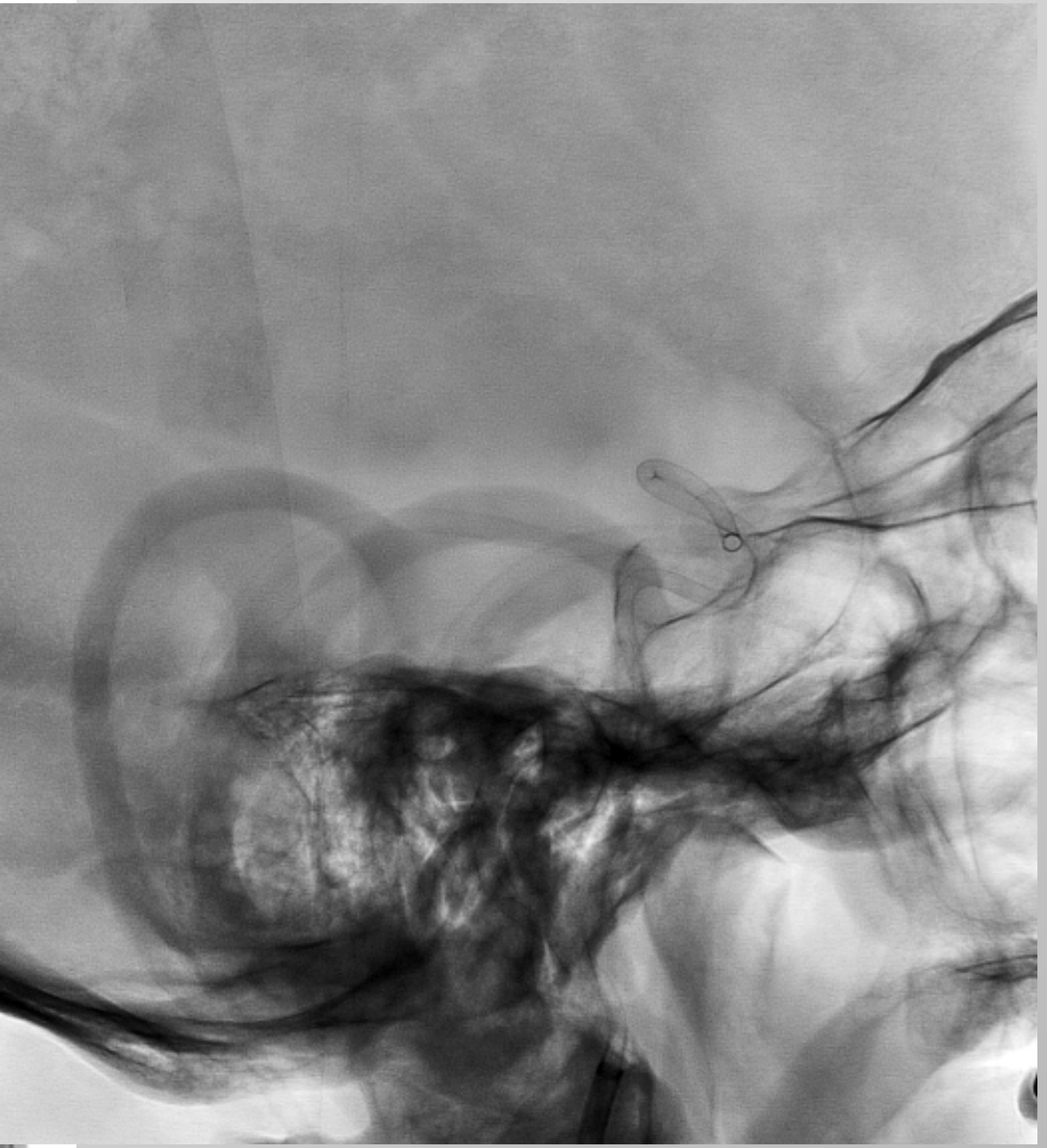
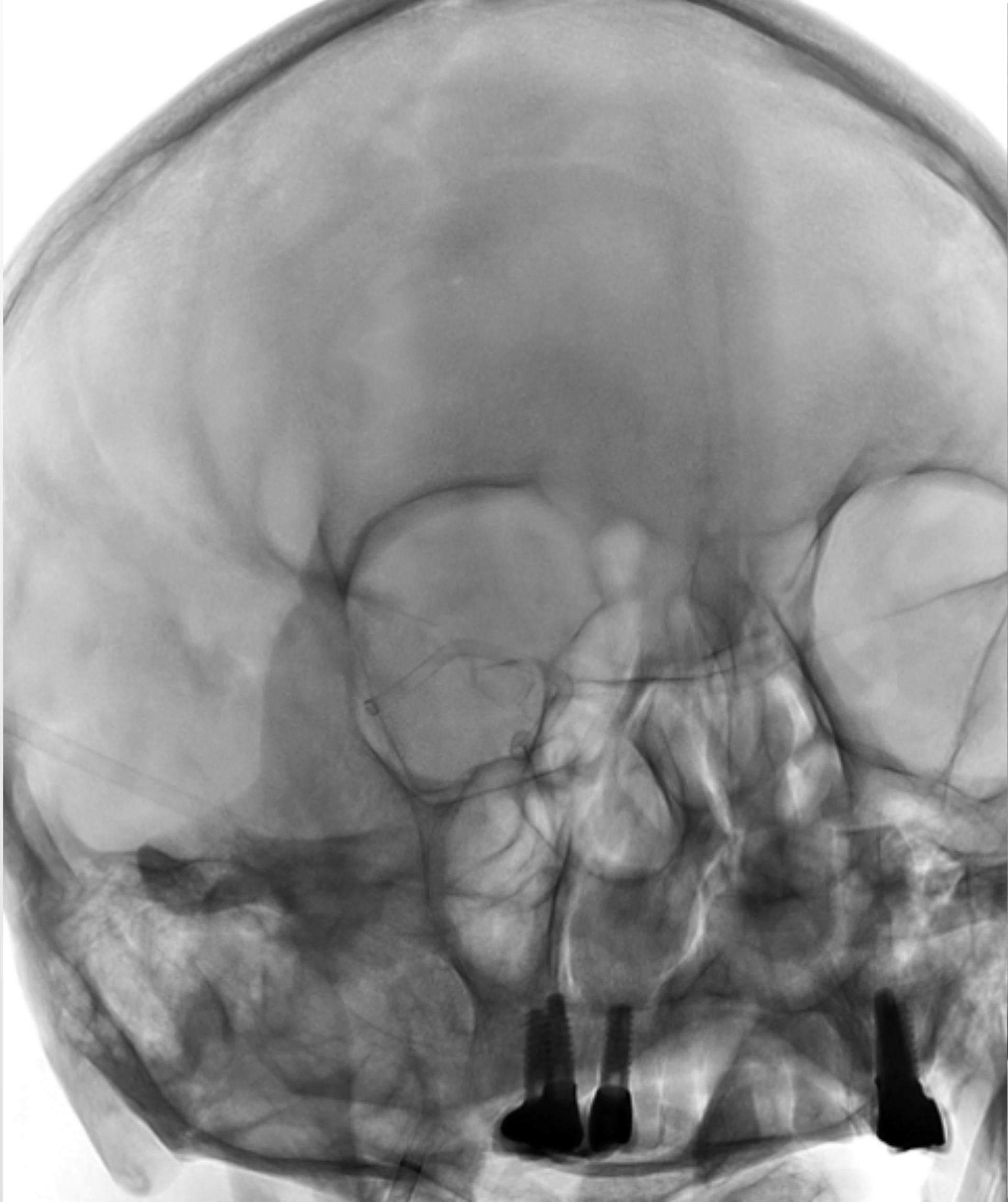
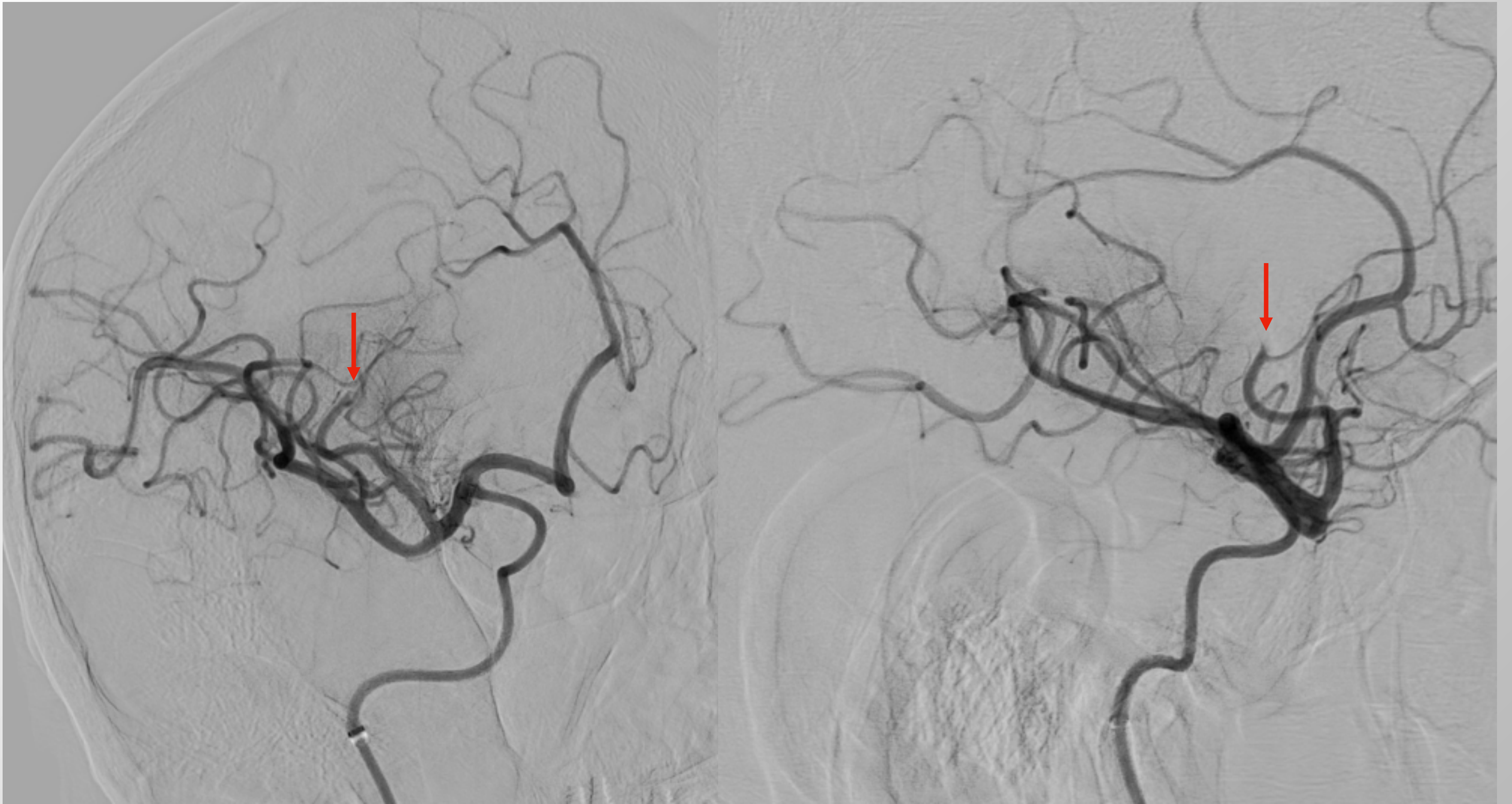
CT PRE (15:35h). ASPECTS 8

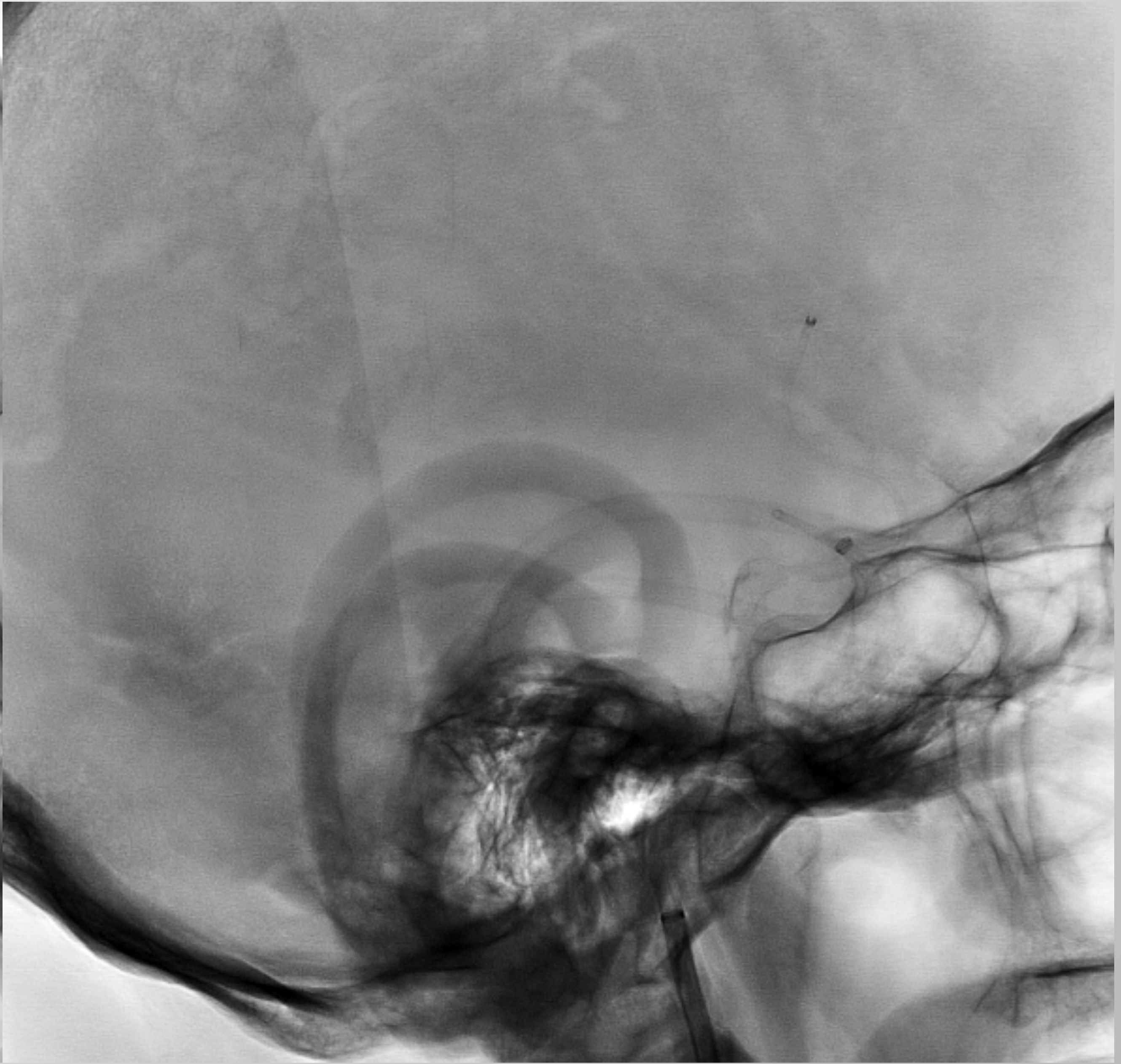
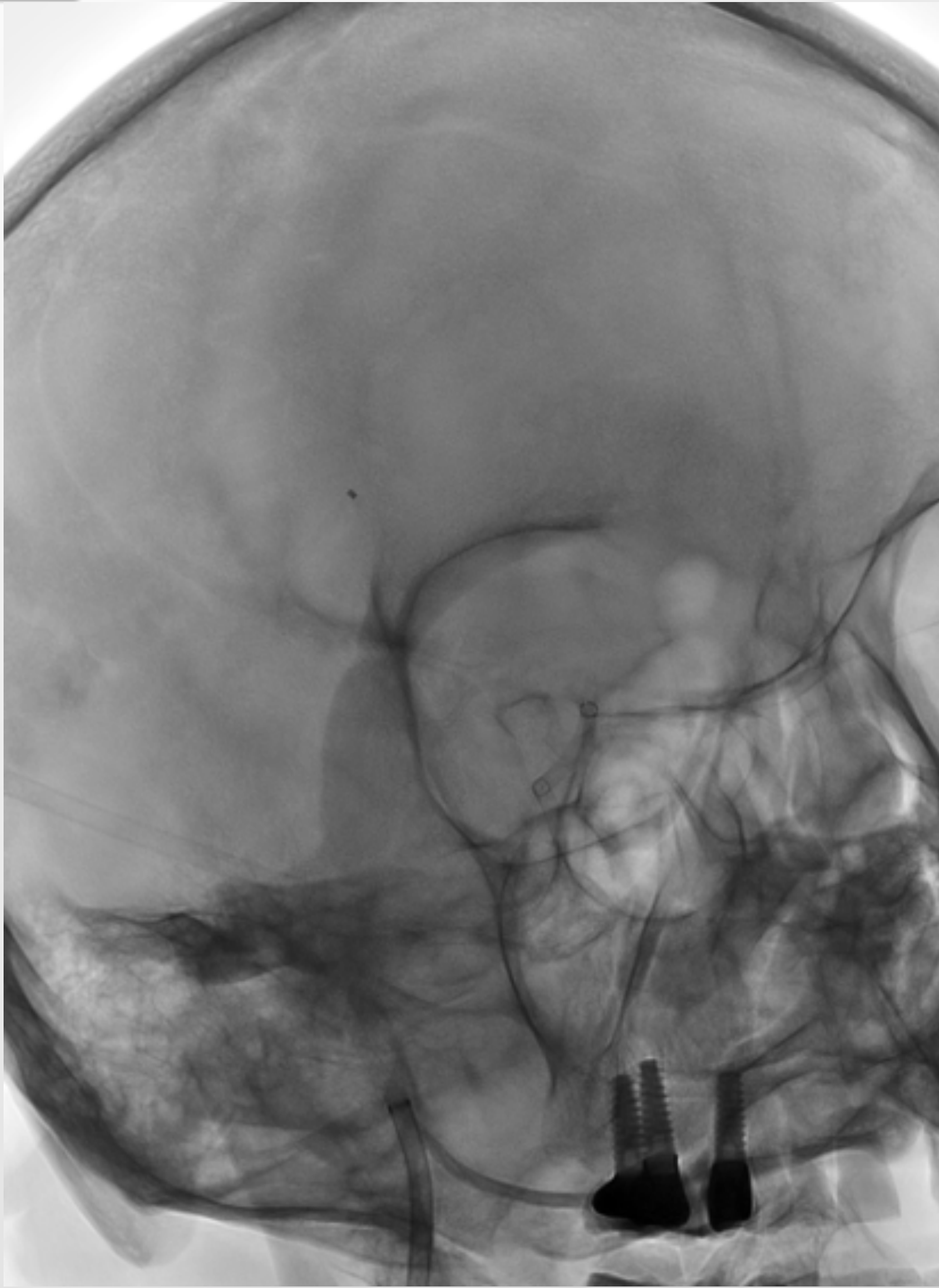




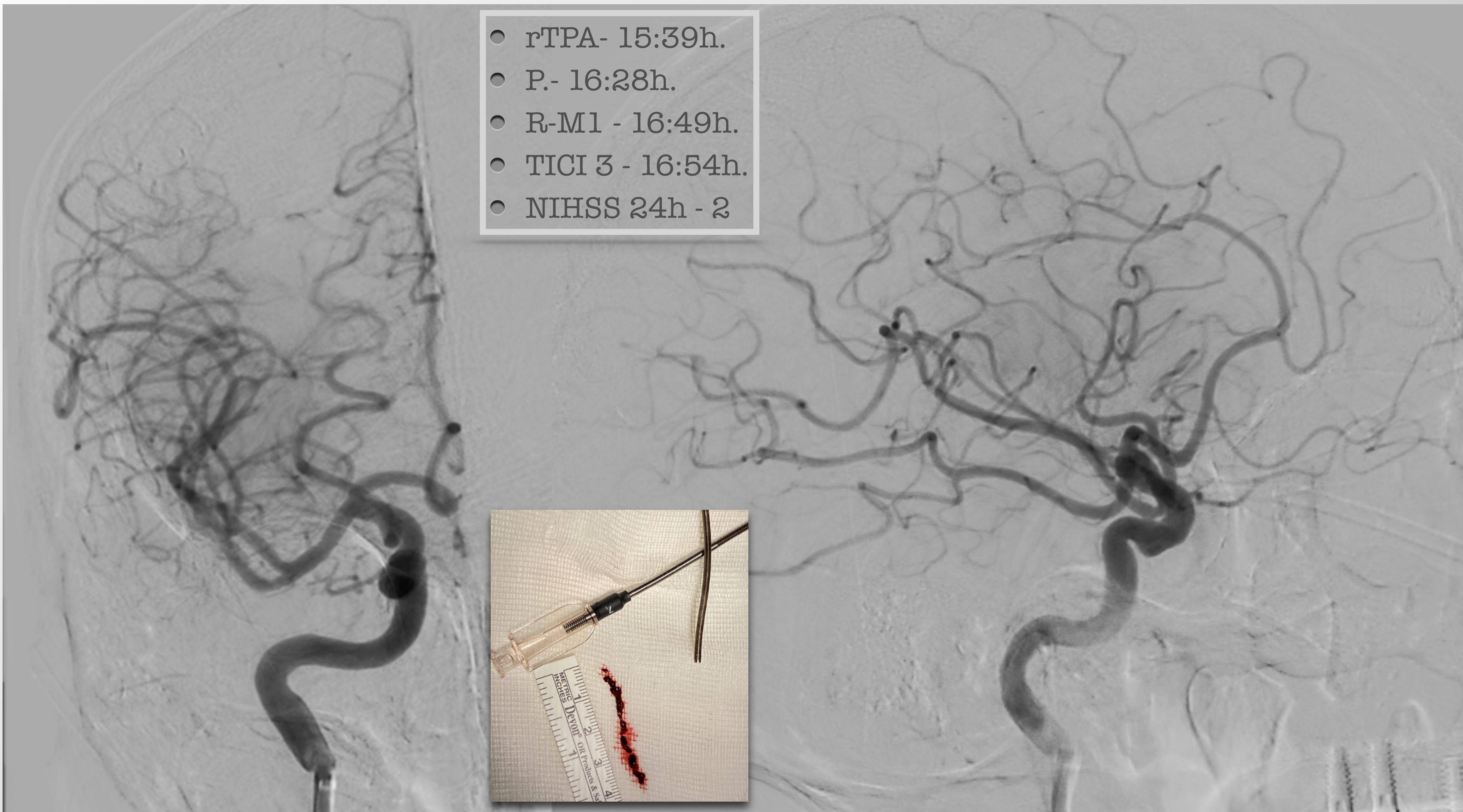


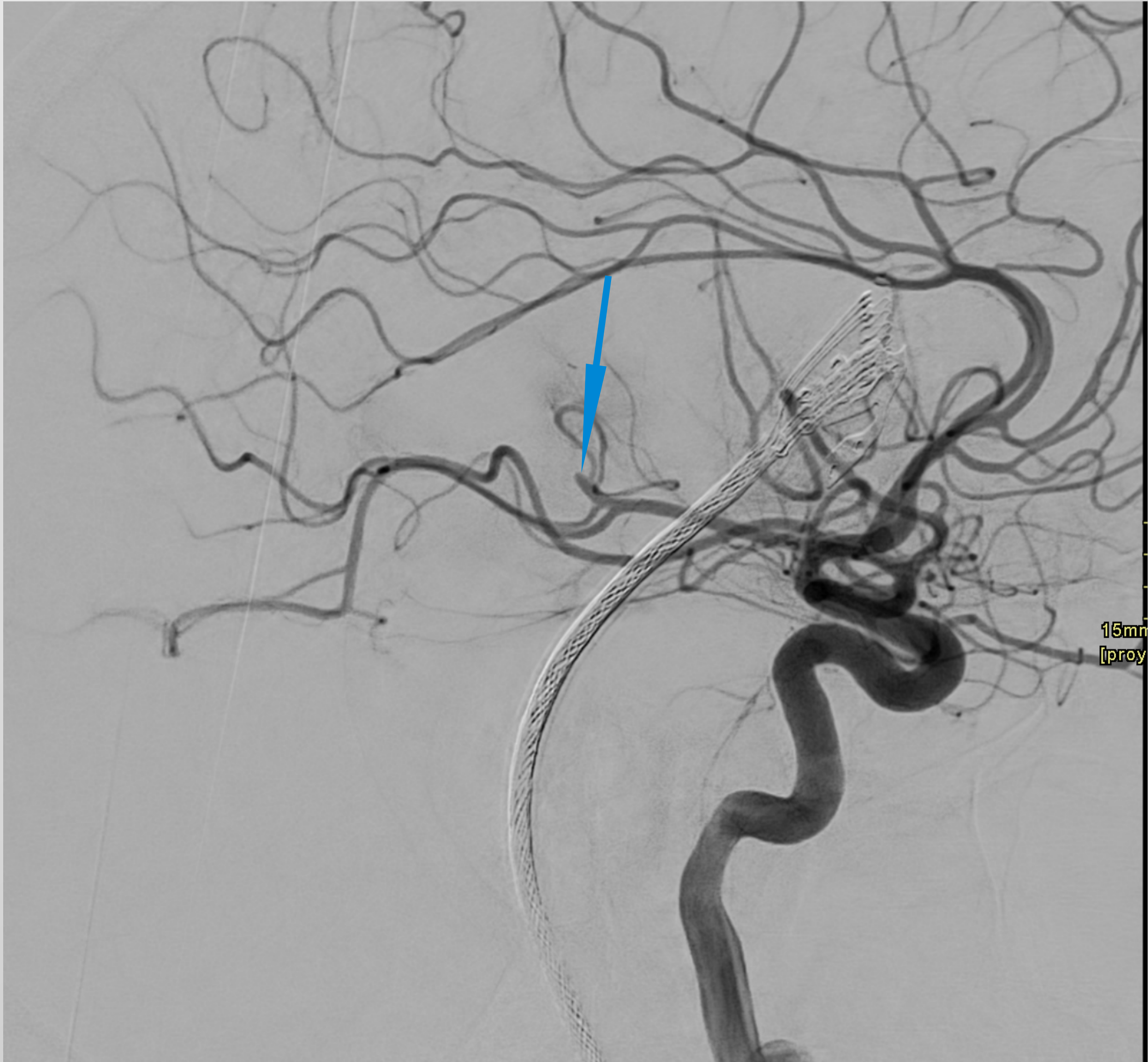
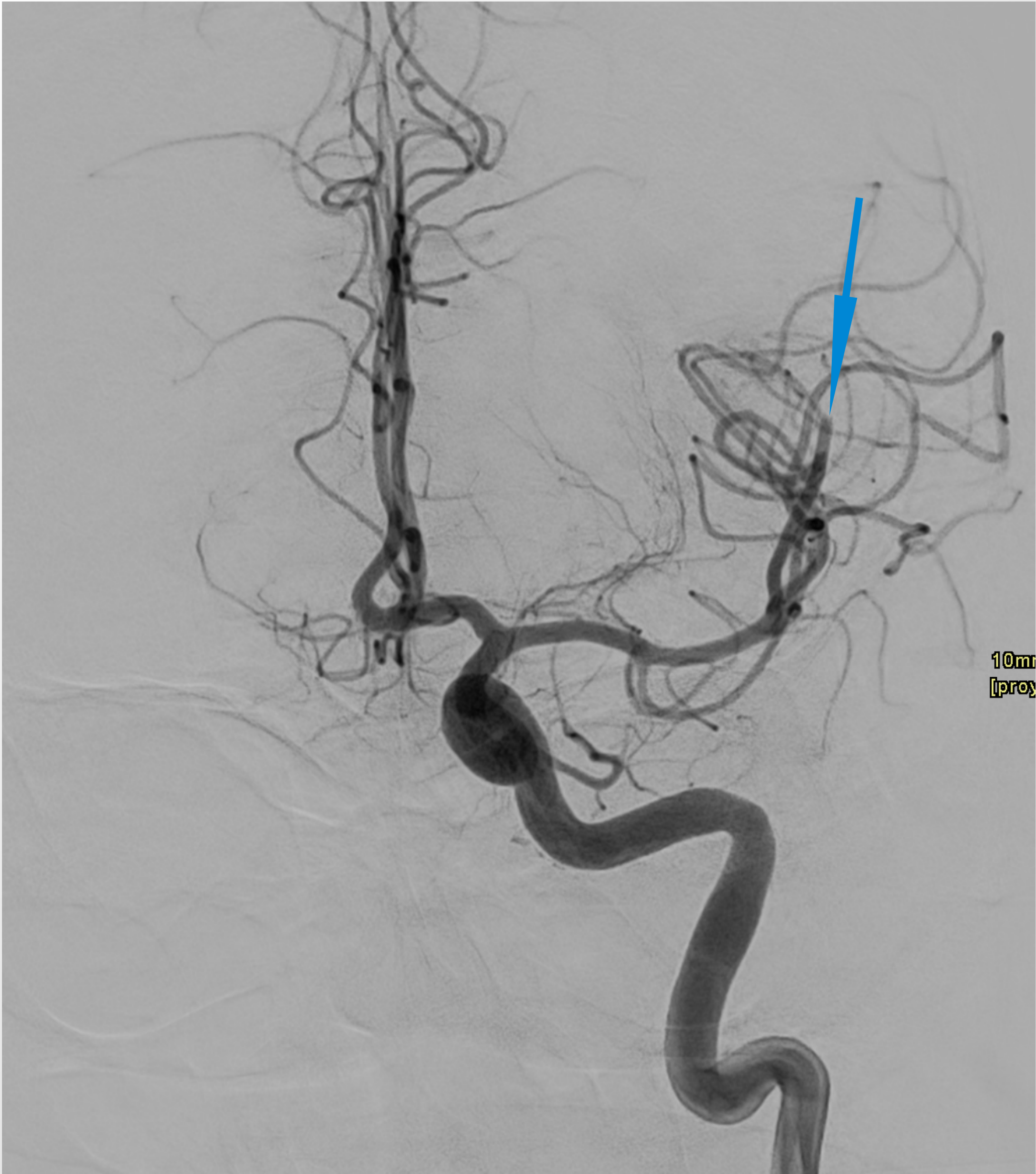
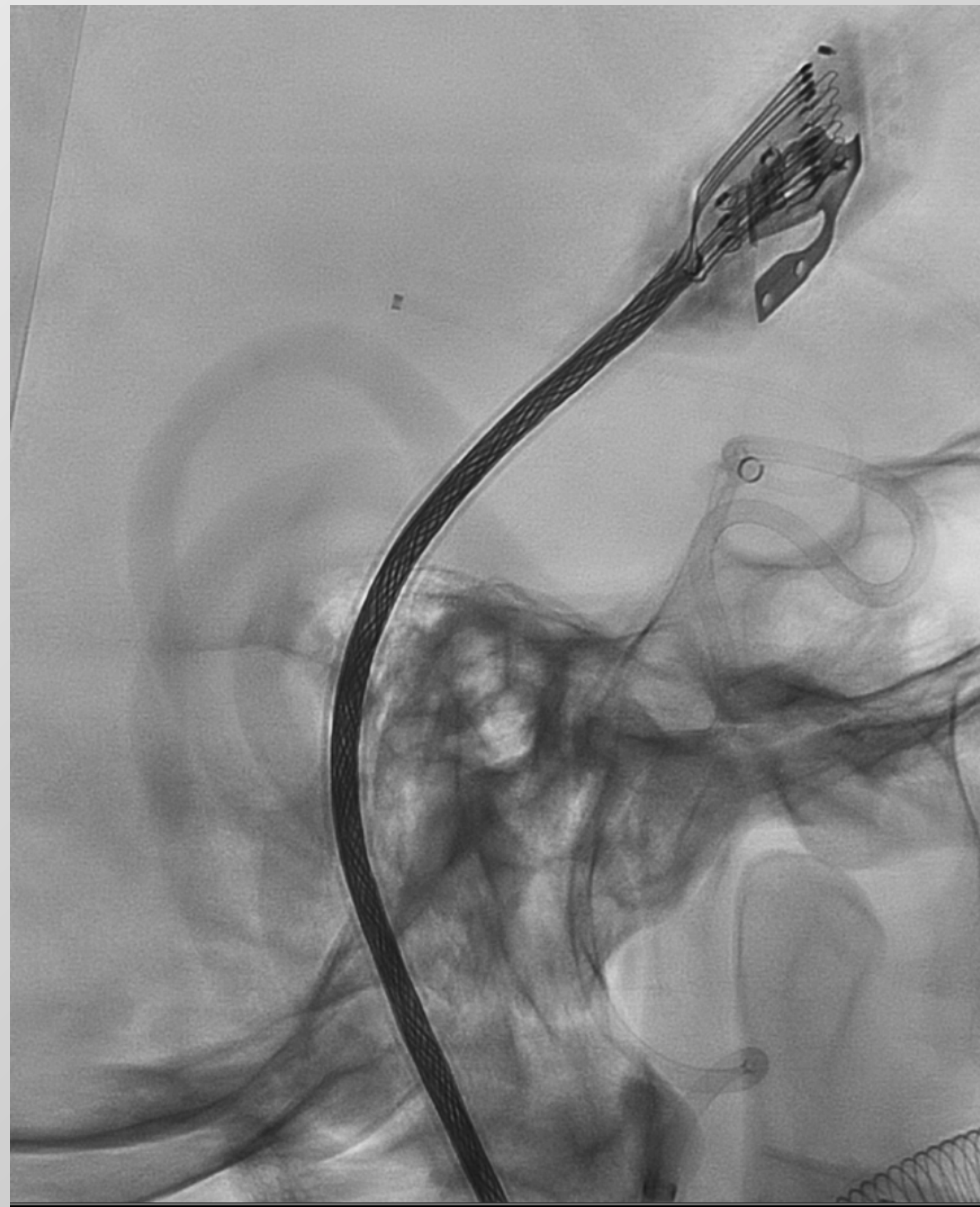


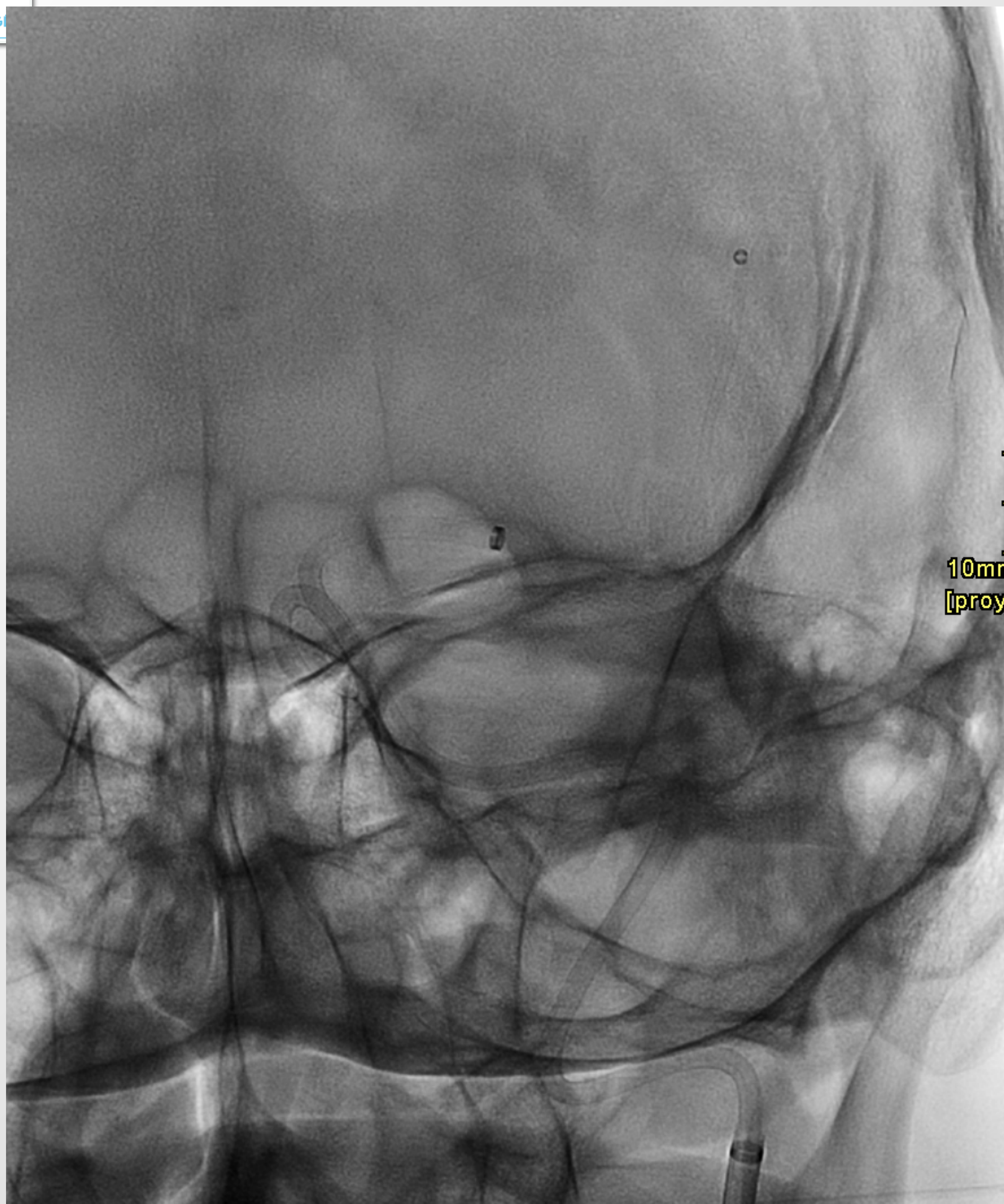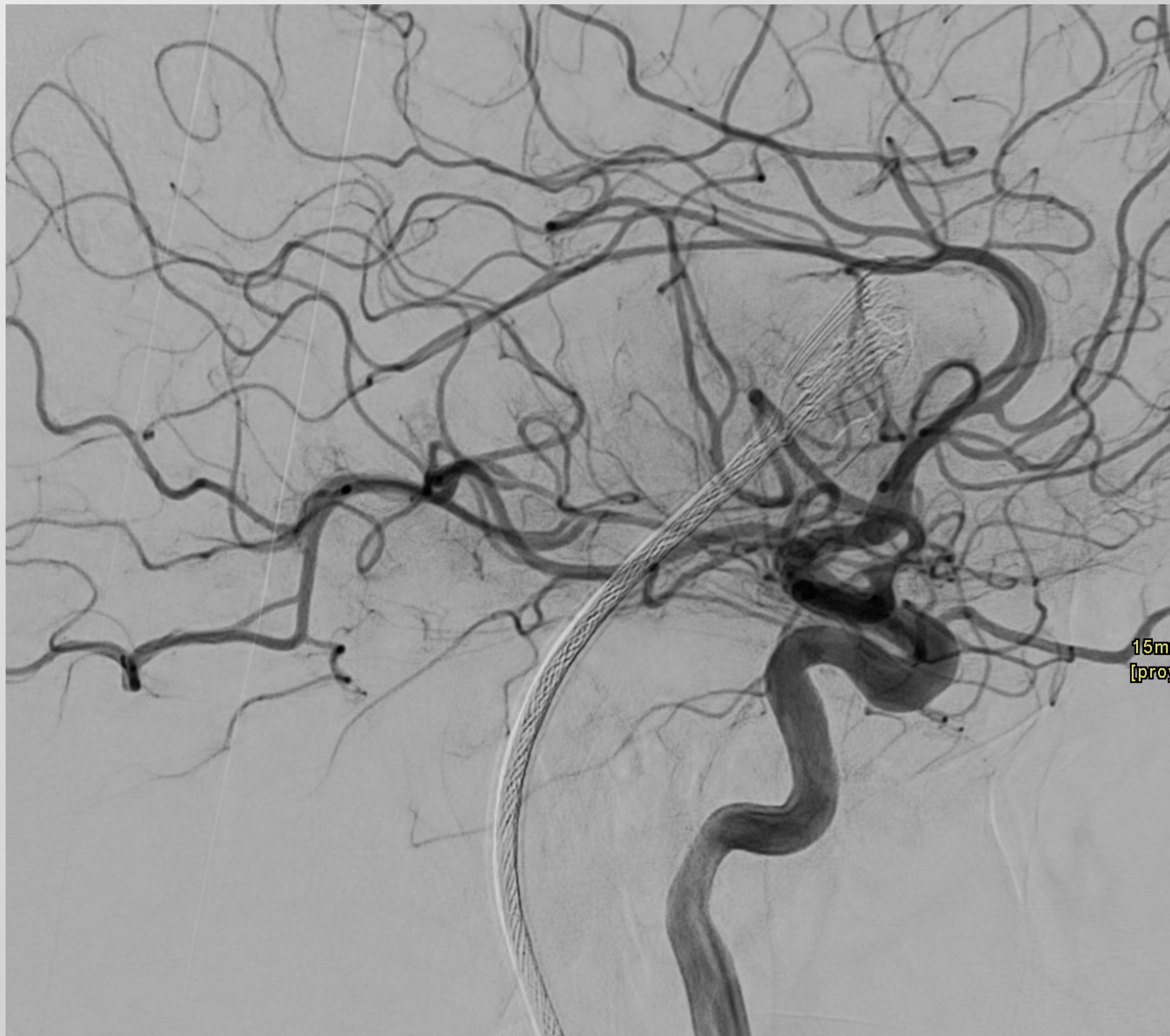


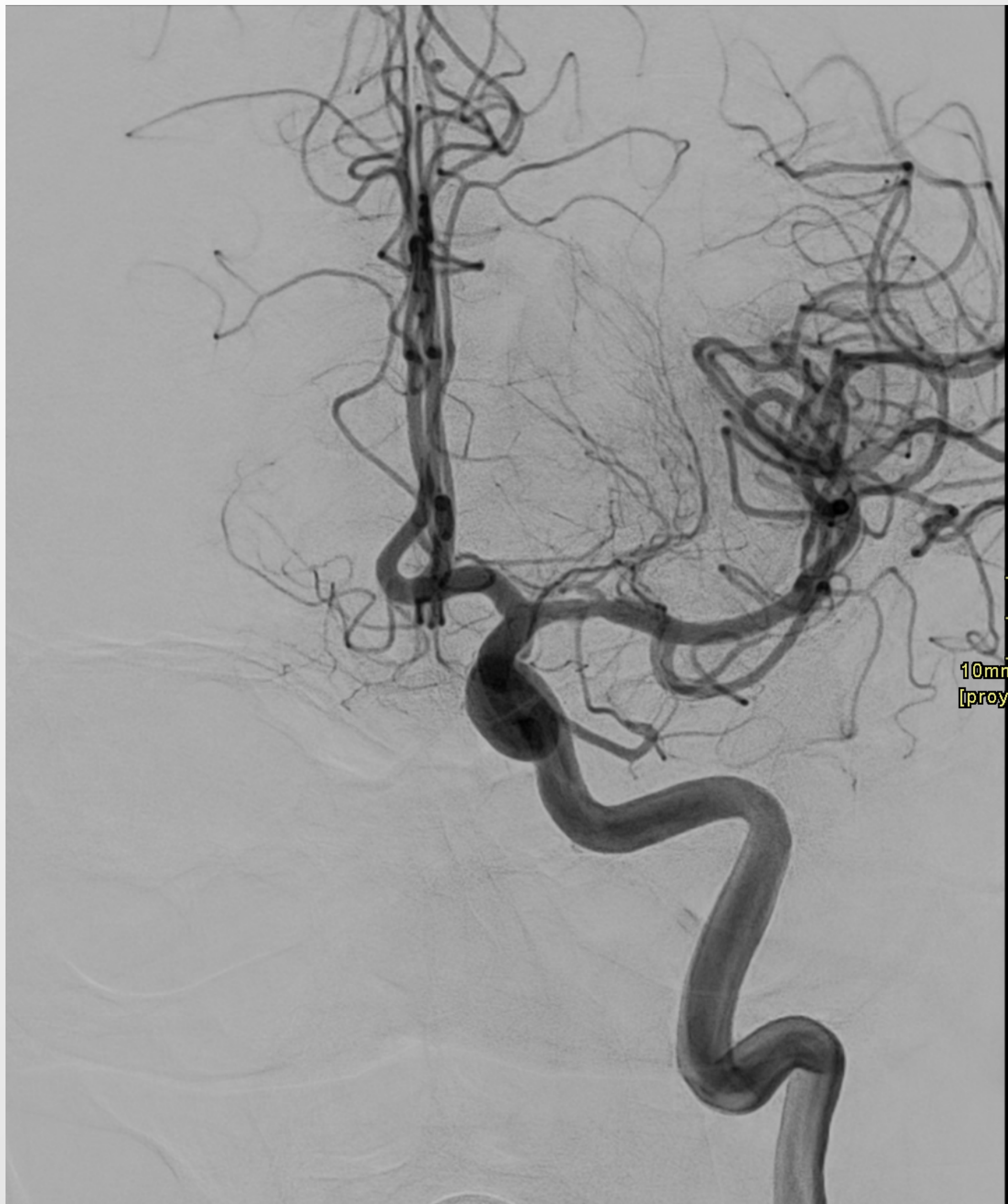- rTPA- 15:39h.
- P.- 16:28h.
- R-M1 - 16:49h.
- TICI 3 - 16:54h.
- NIHSS 24h - 2

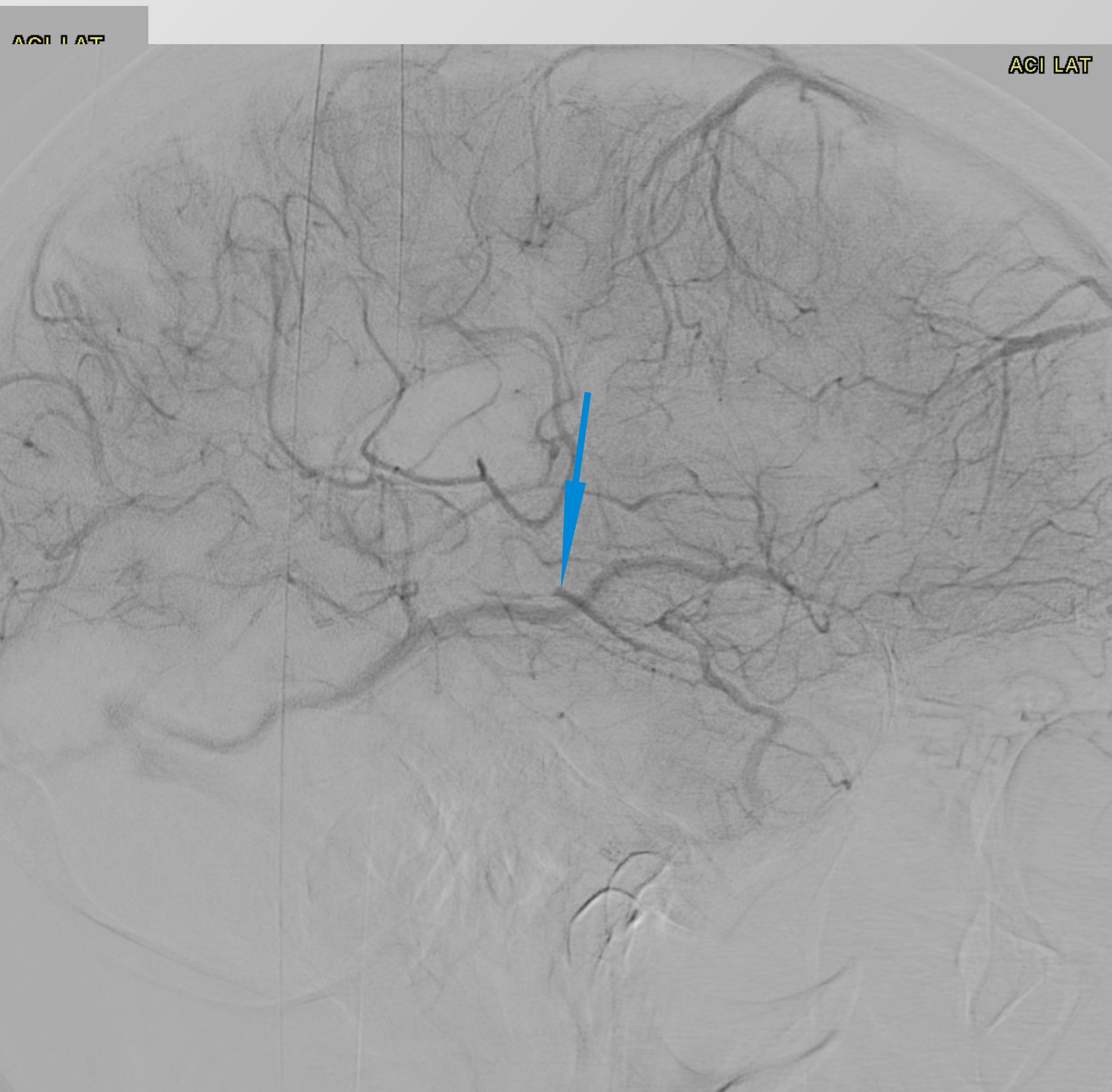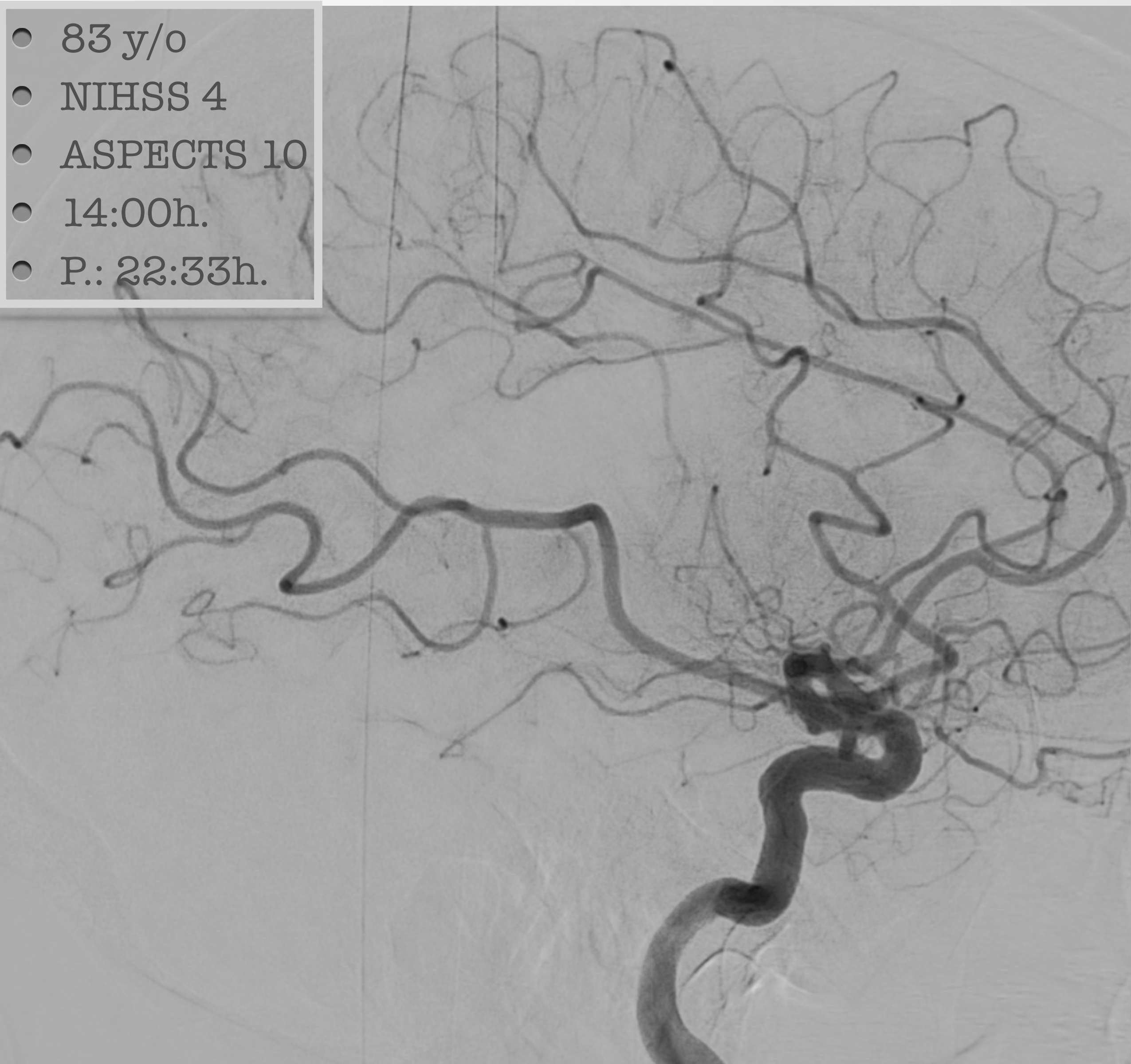



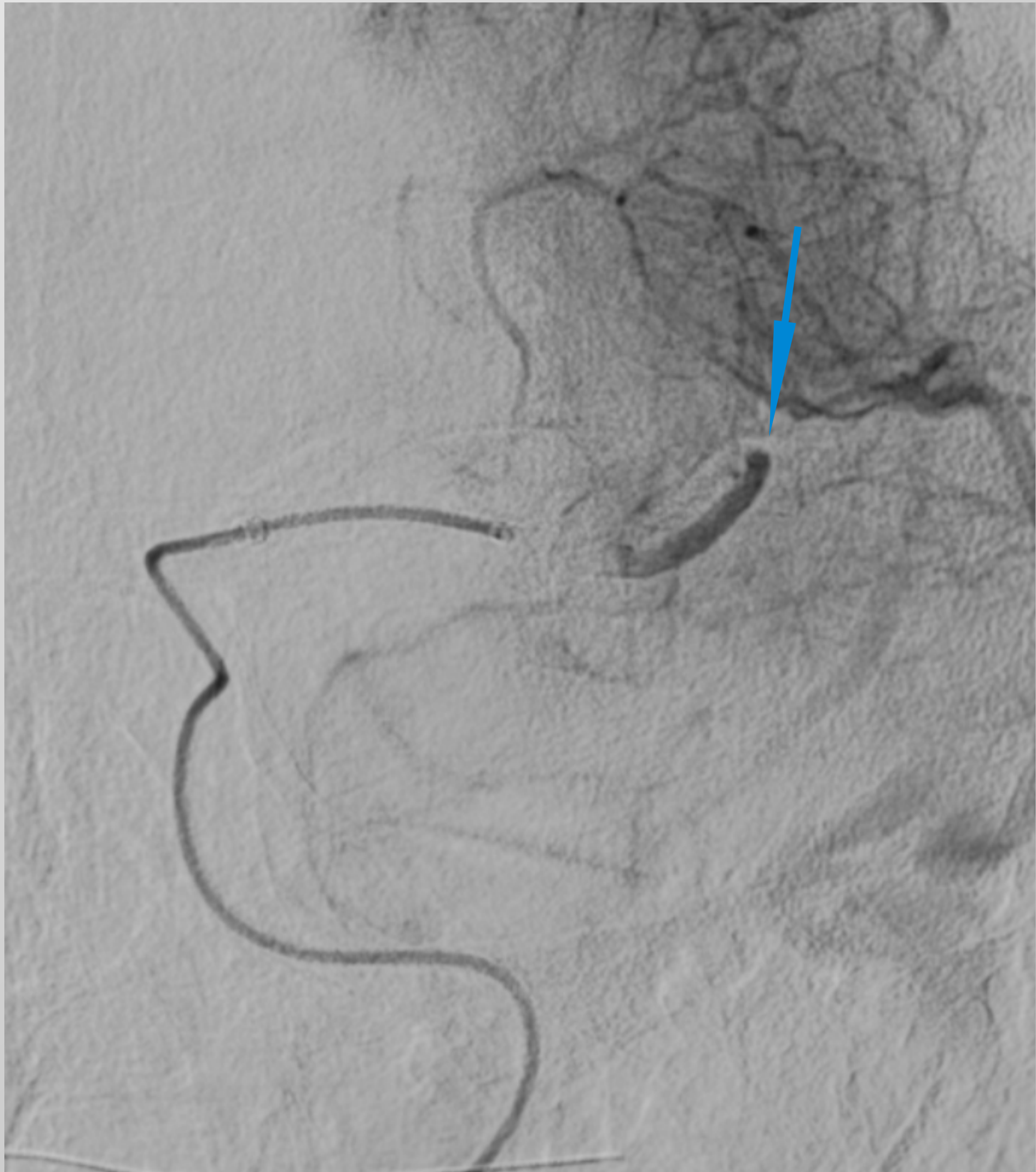
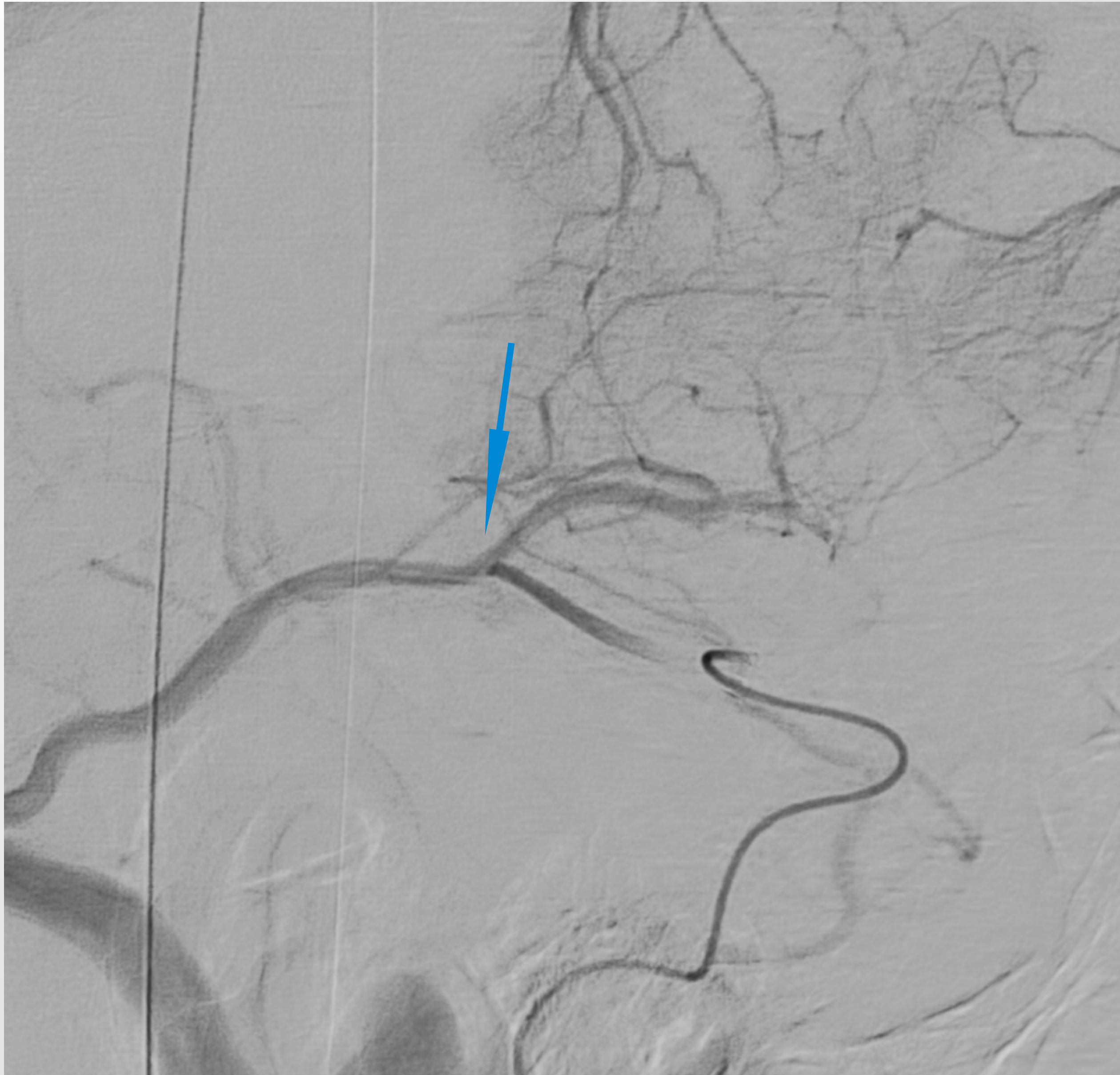


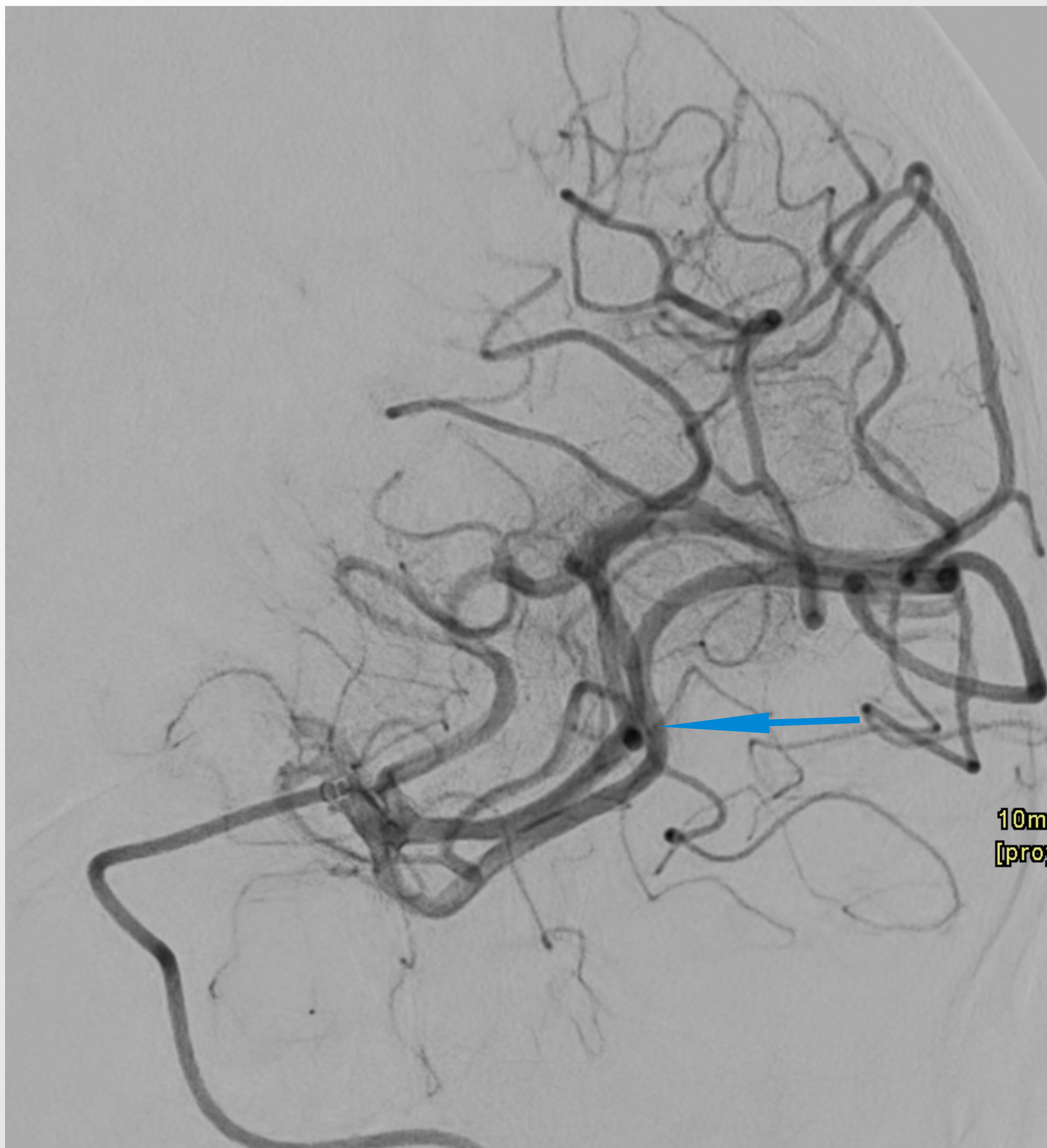
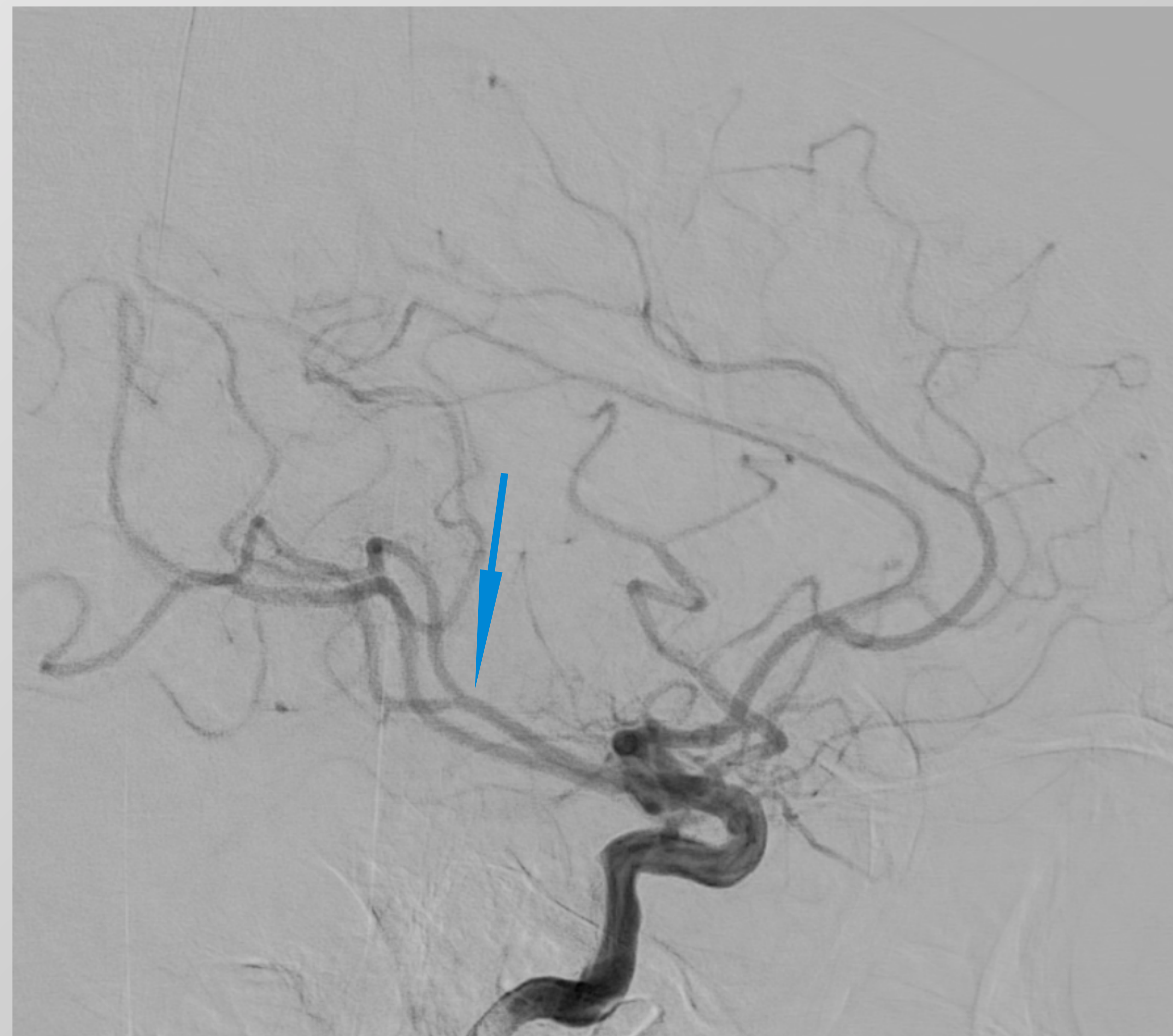- 83 y/o
- NIHSS 4
- ASPECTS 10
- 14:00h.
- P.: 22:33h.

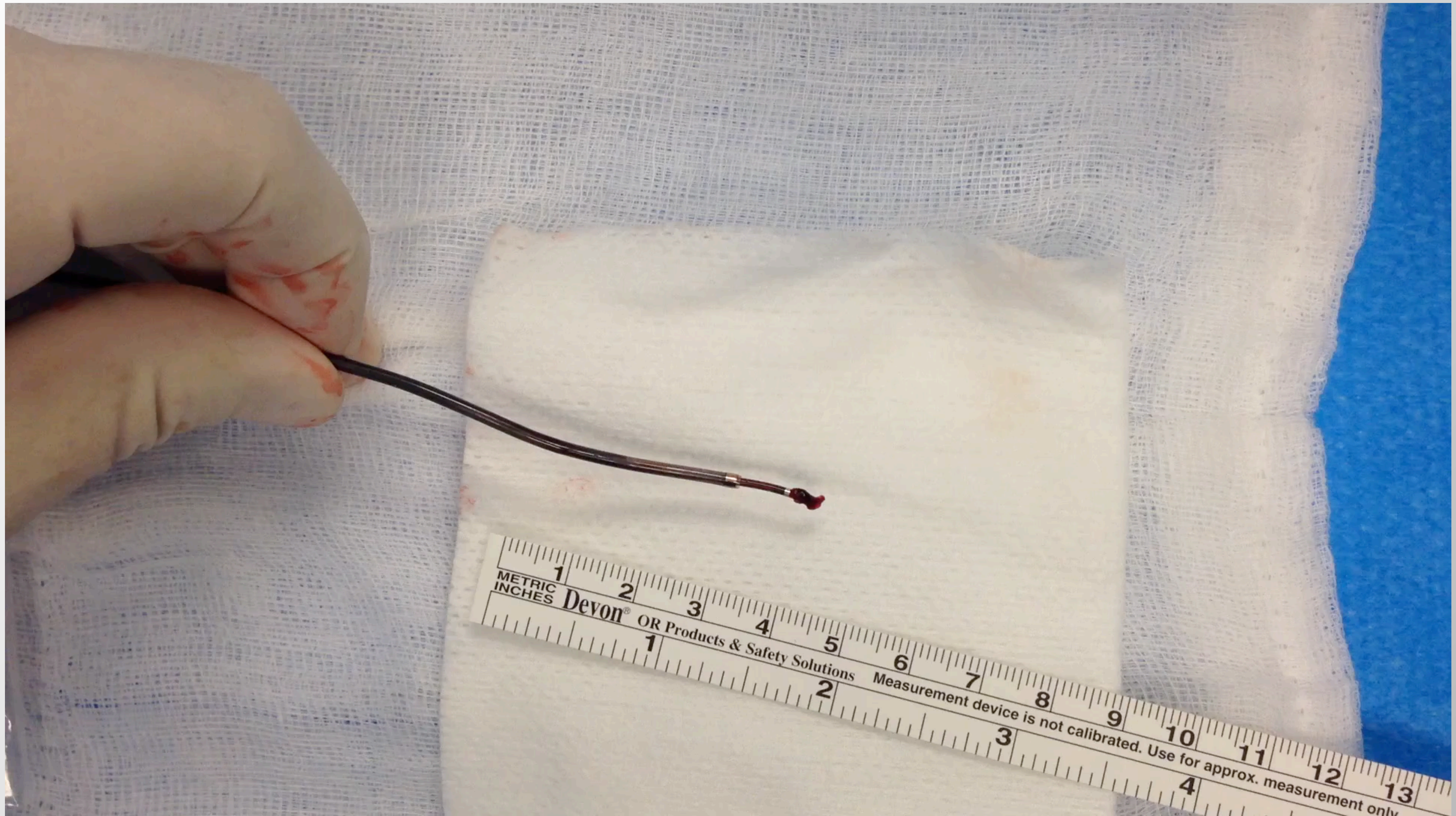




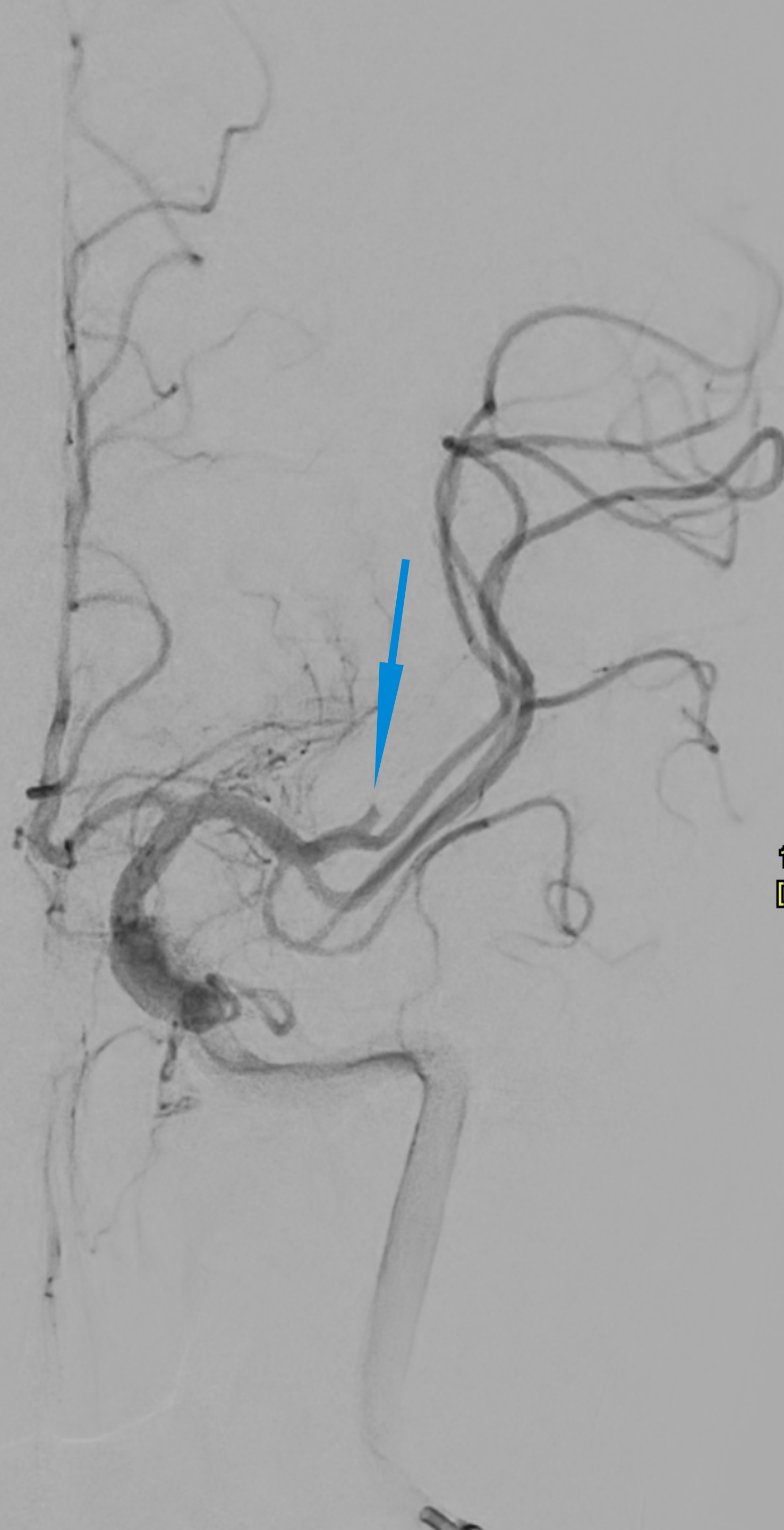


- TICI 3: 23:02h.
- P-R: 29 min.
- NIHSS 24h: 2

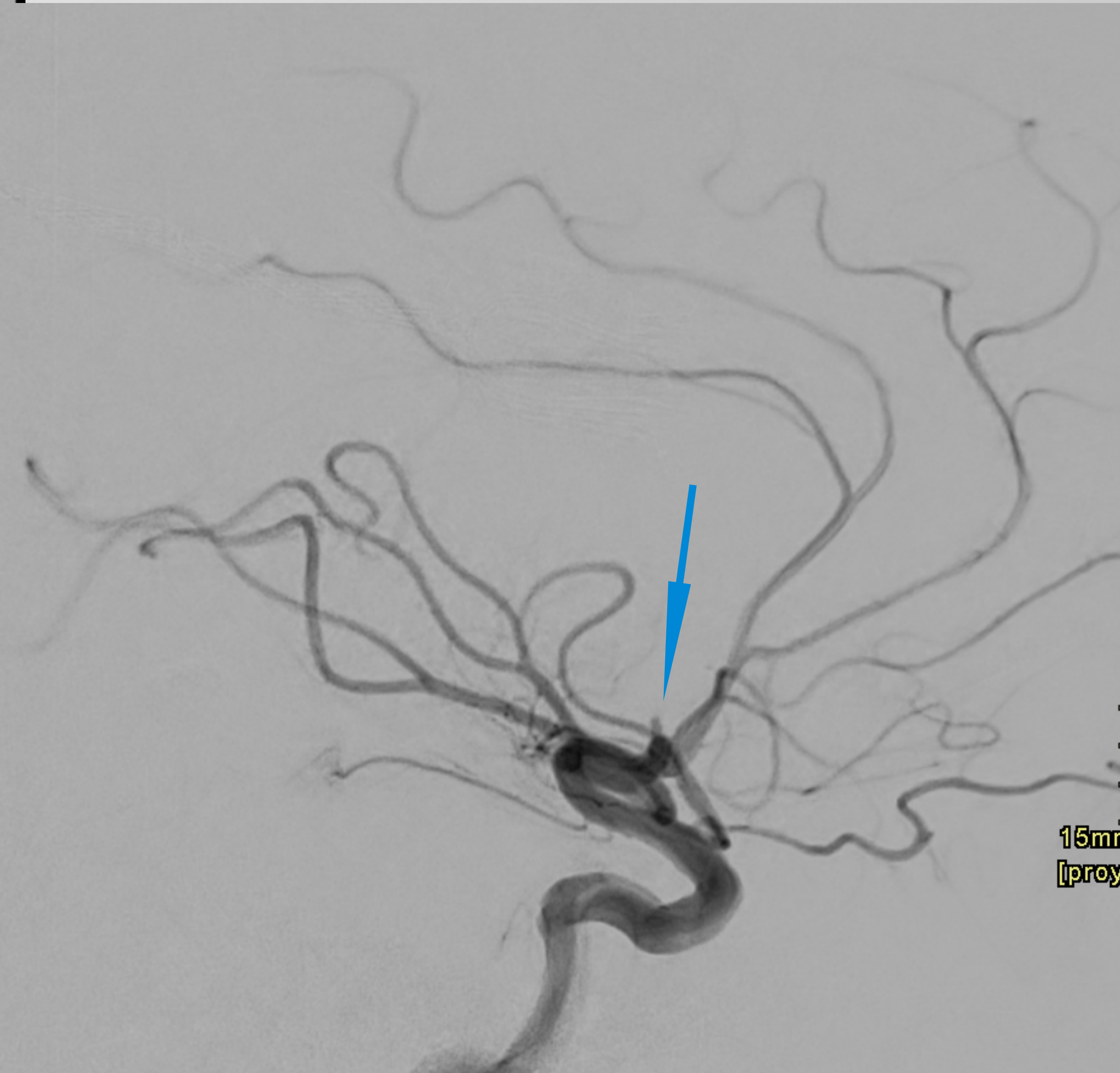



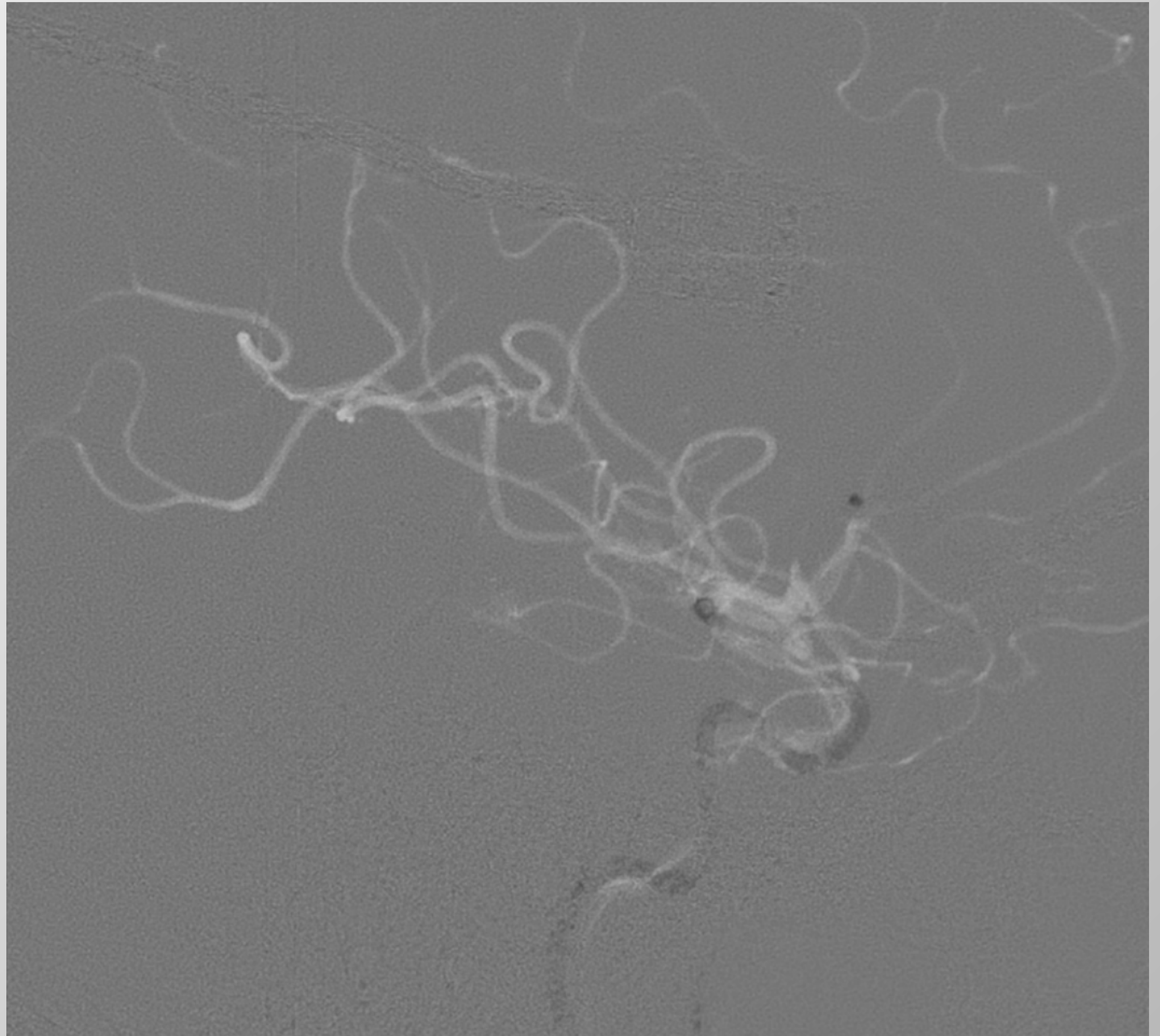
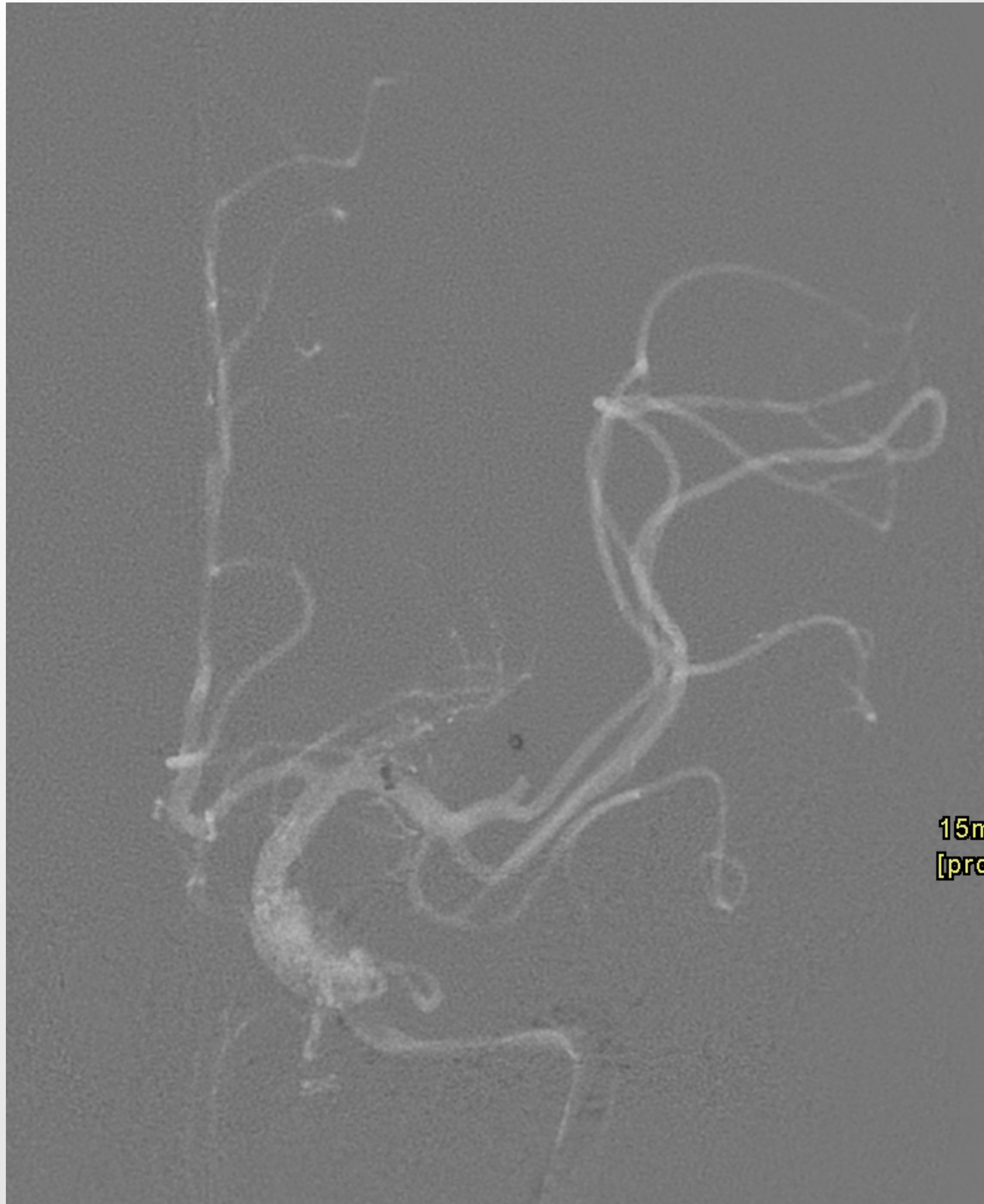- 82 y/o
- NIHSS 6
- ASPECTS 9
- Wake up
- P.: 18:15h.

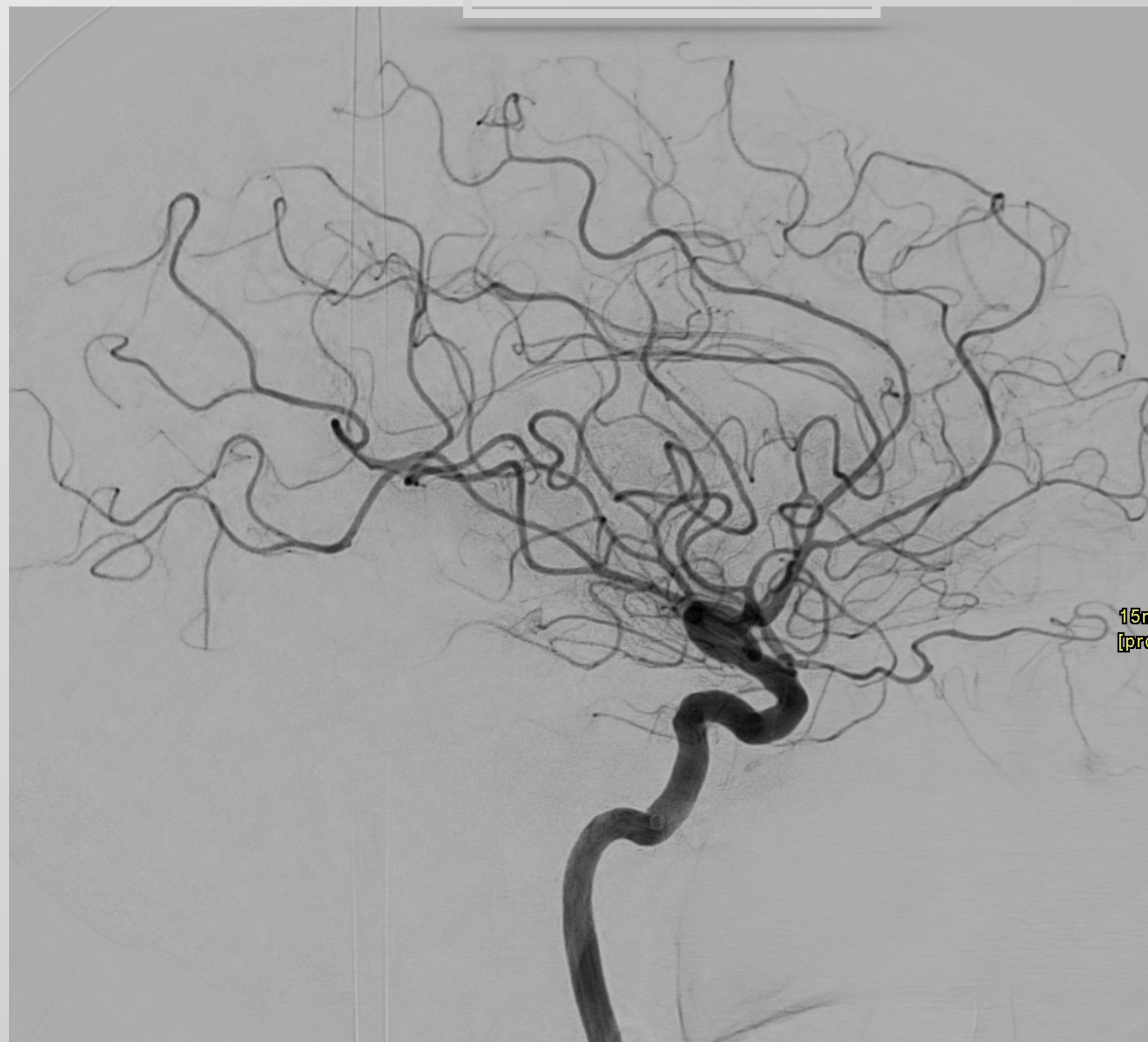
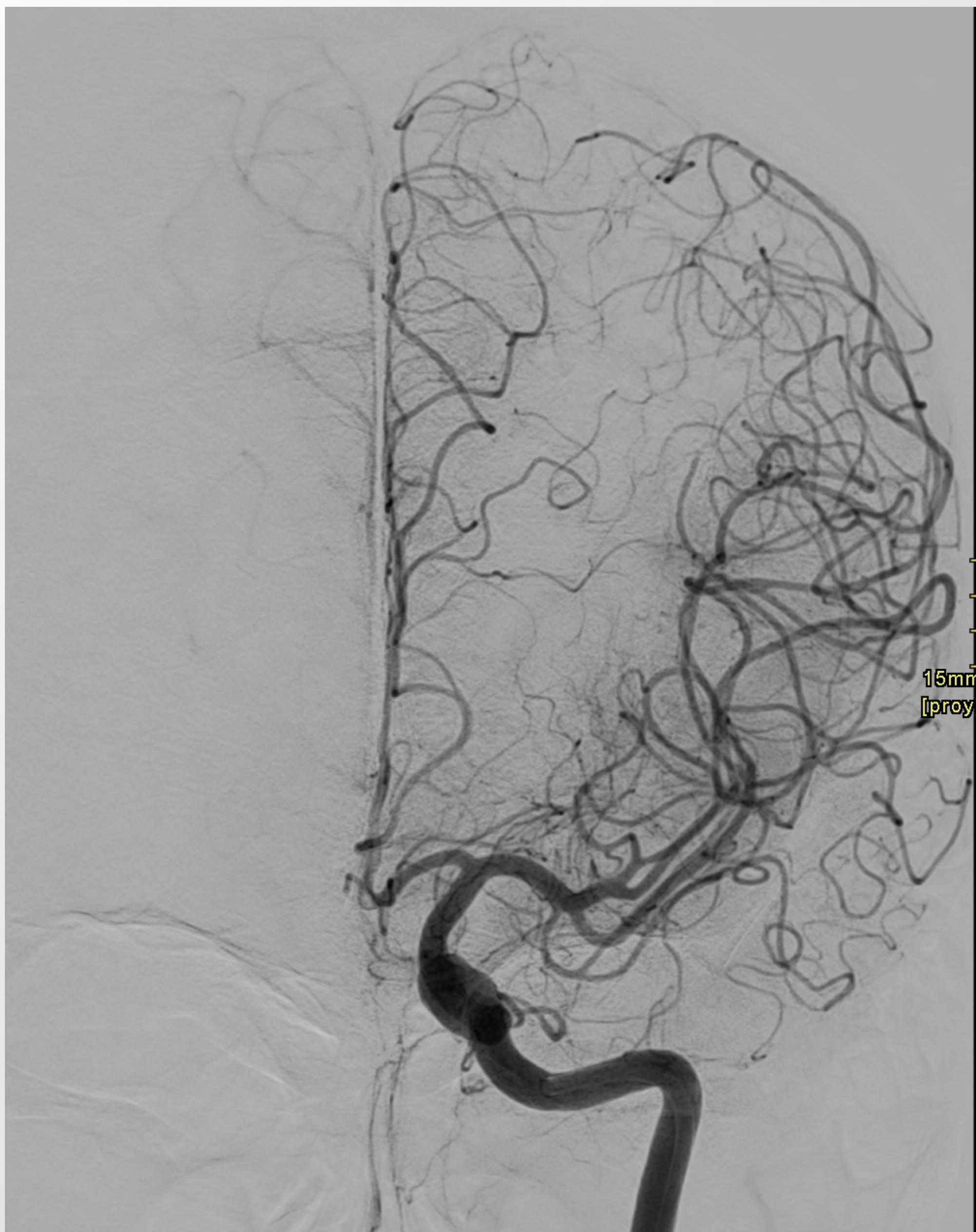

15r
[pr]

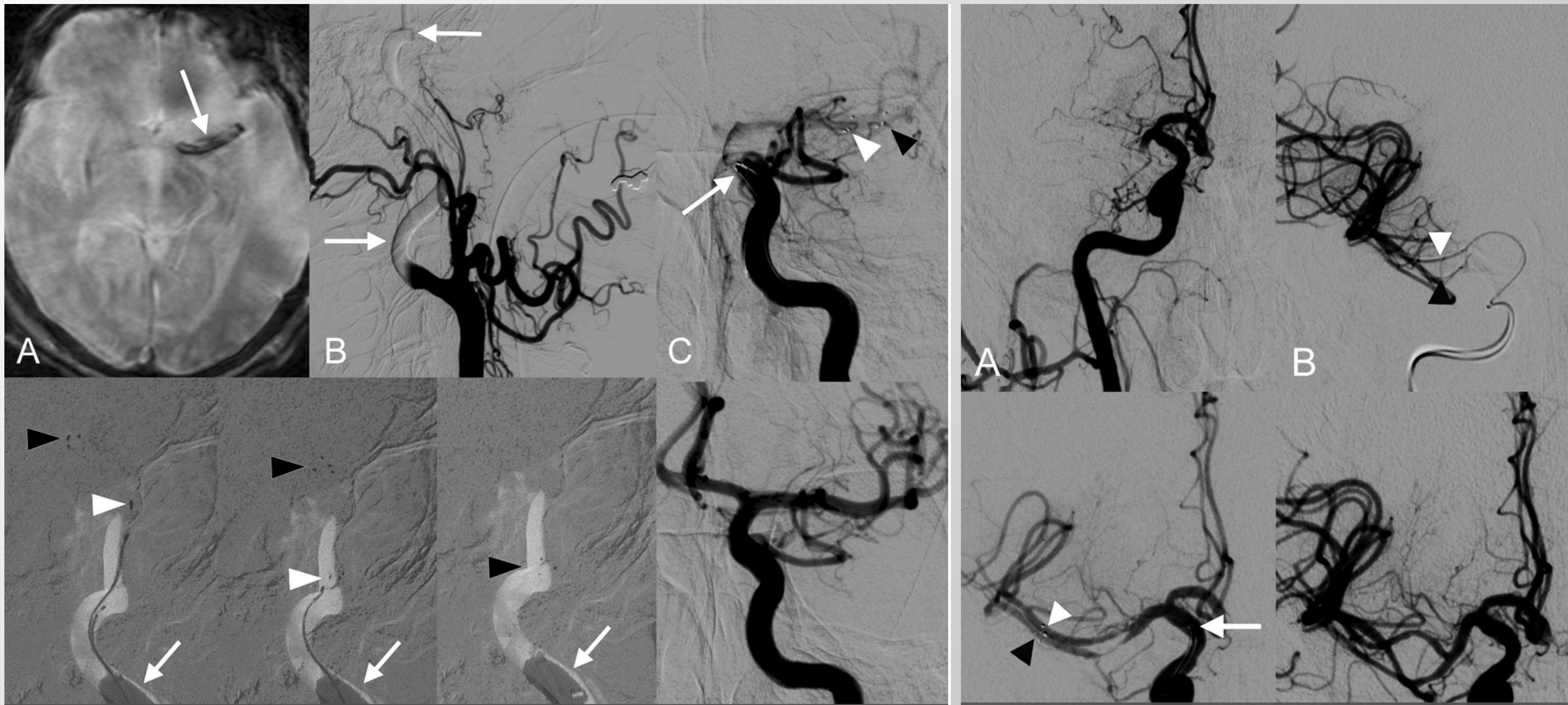


15mr
[proy]





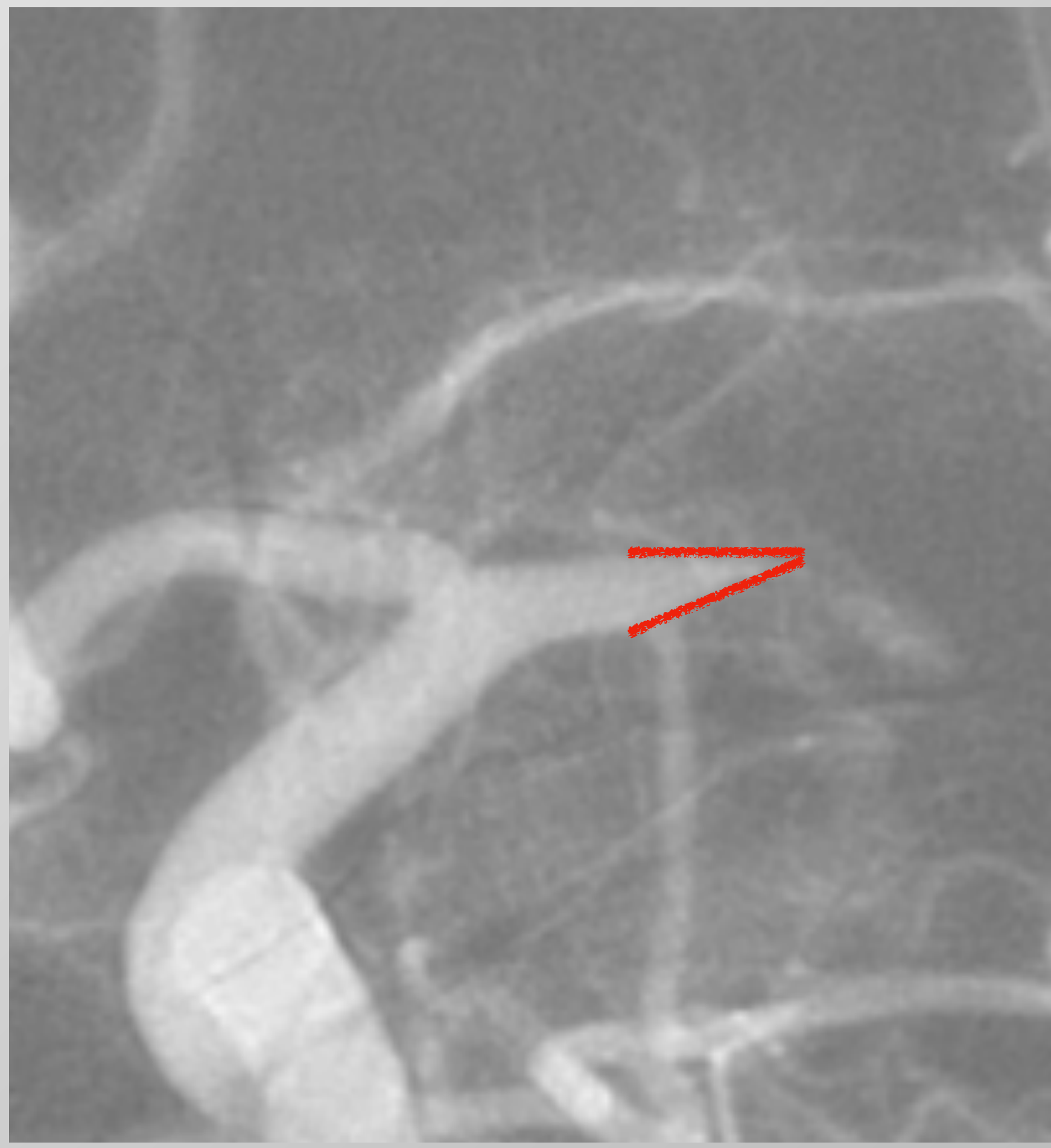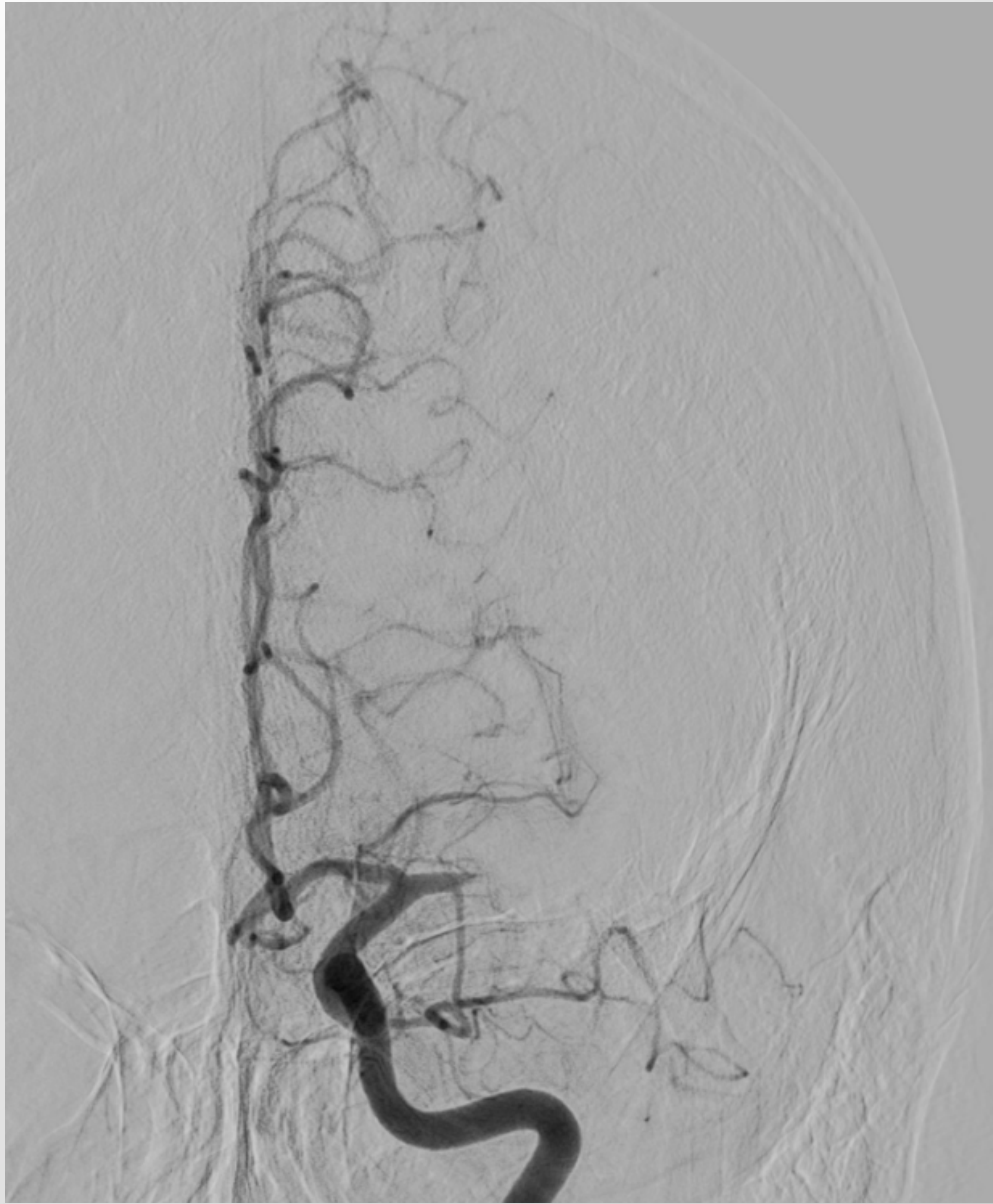
- TICI 2C: 18:53h.
- P-R: 38 min.
- NIHSS 24h: 1

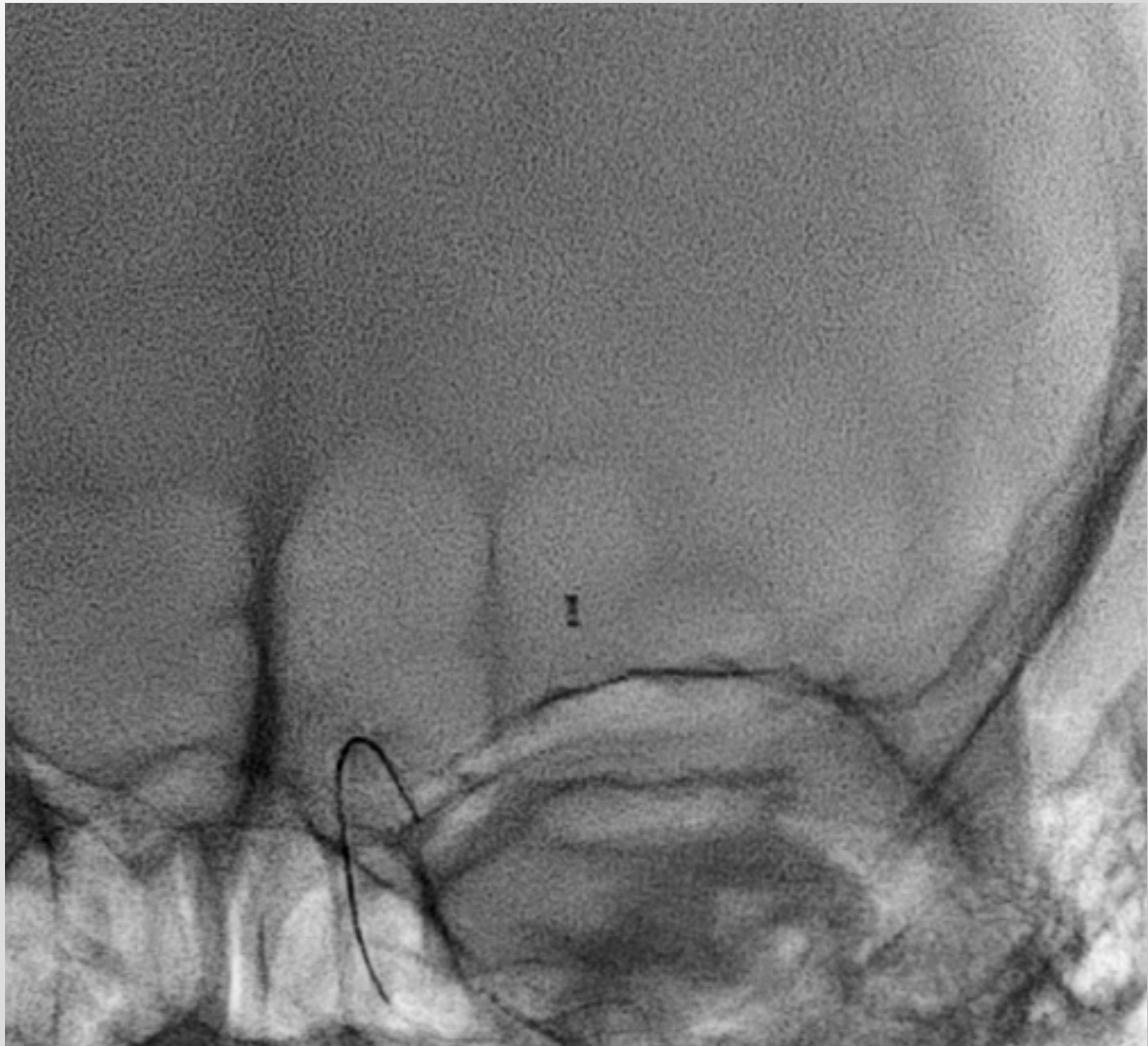


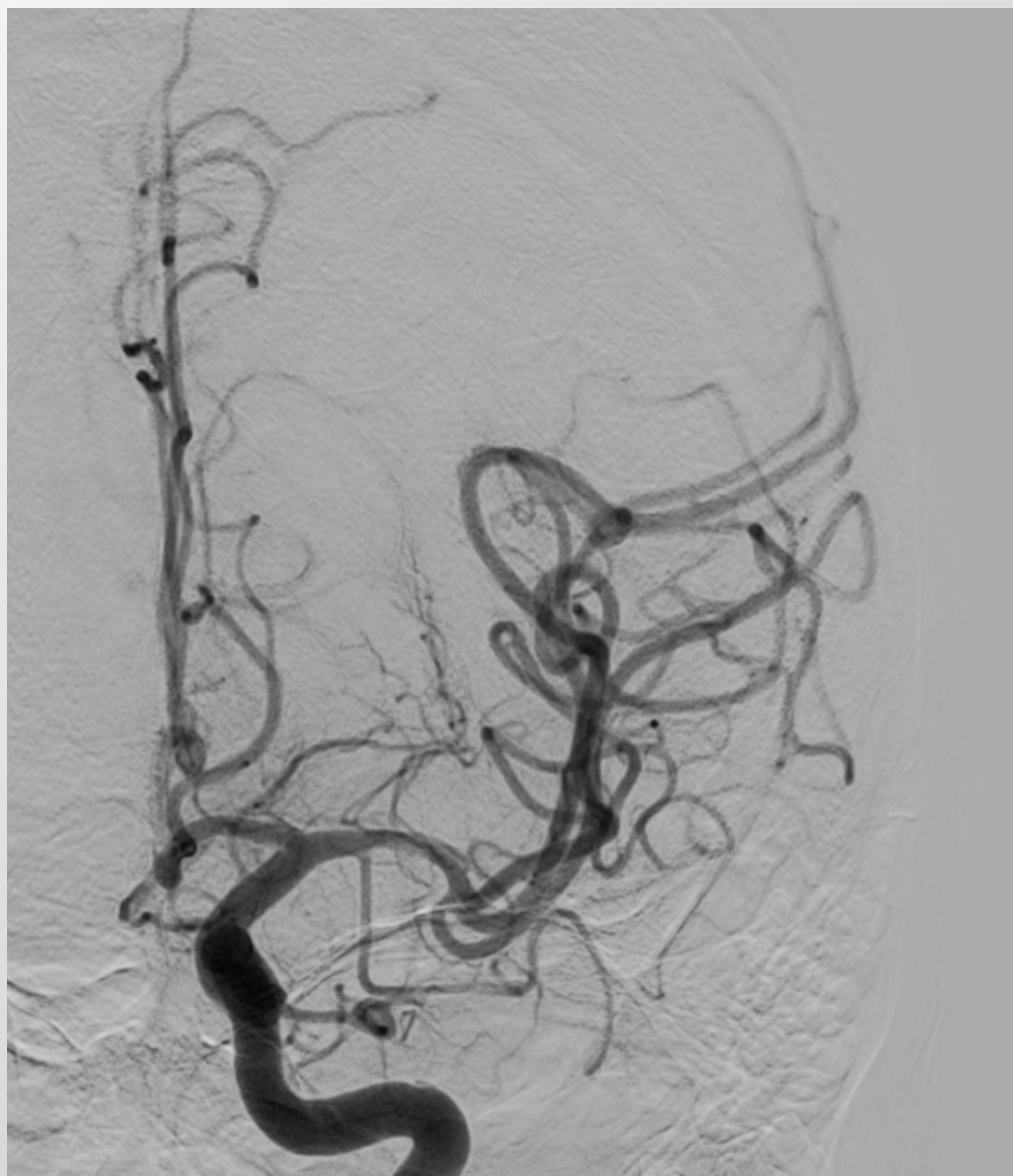Double Solitaire Mechanical Thrombectomy in Acute Stroke: Effective Rescue Strategy for Refractory Artery Occlusions?

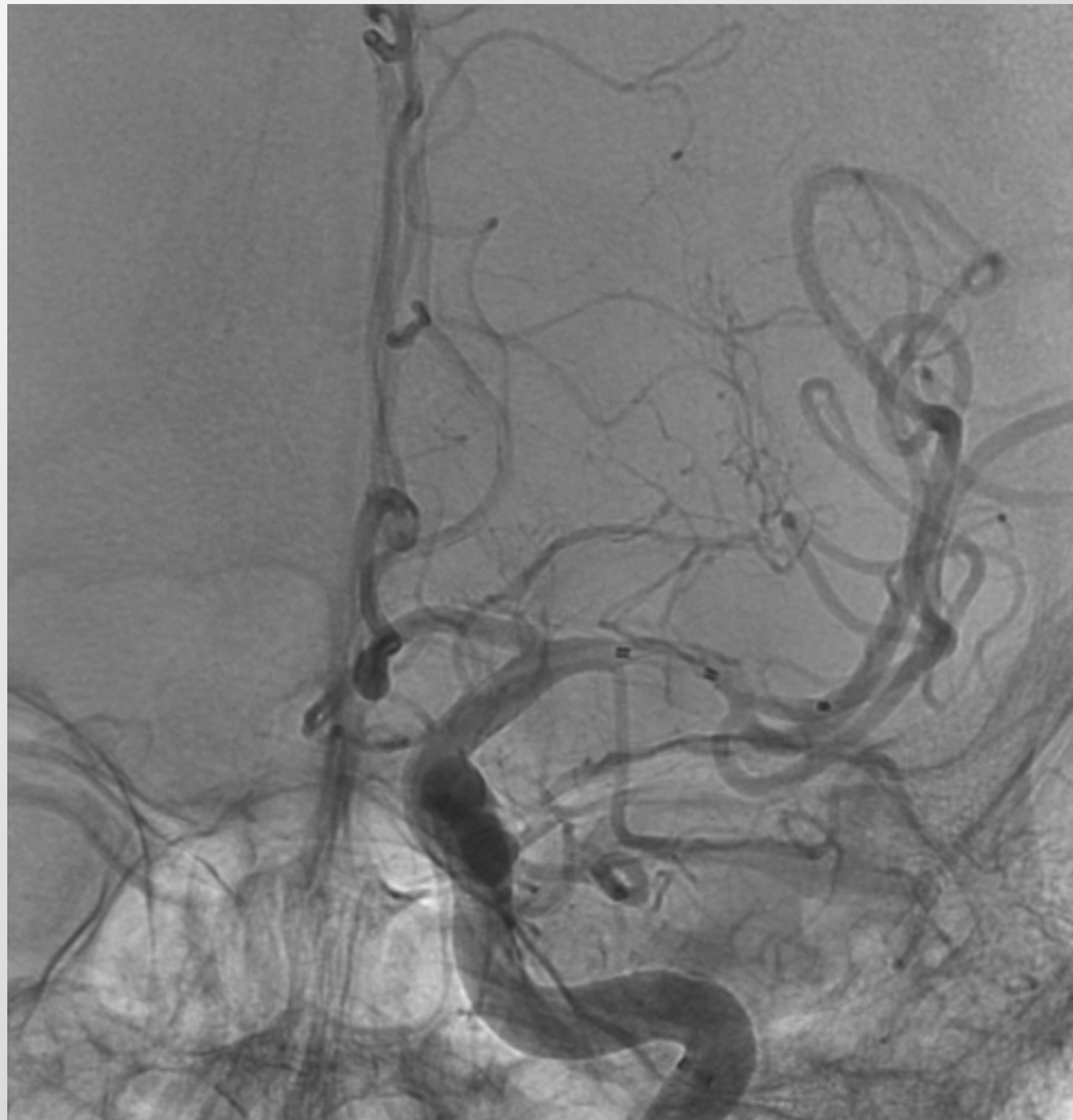
J. Klisch, V. Sychra, C. Strasilla, C.A. Taschner, M. Reinhard, H. Urbach, S. Meckel

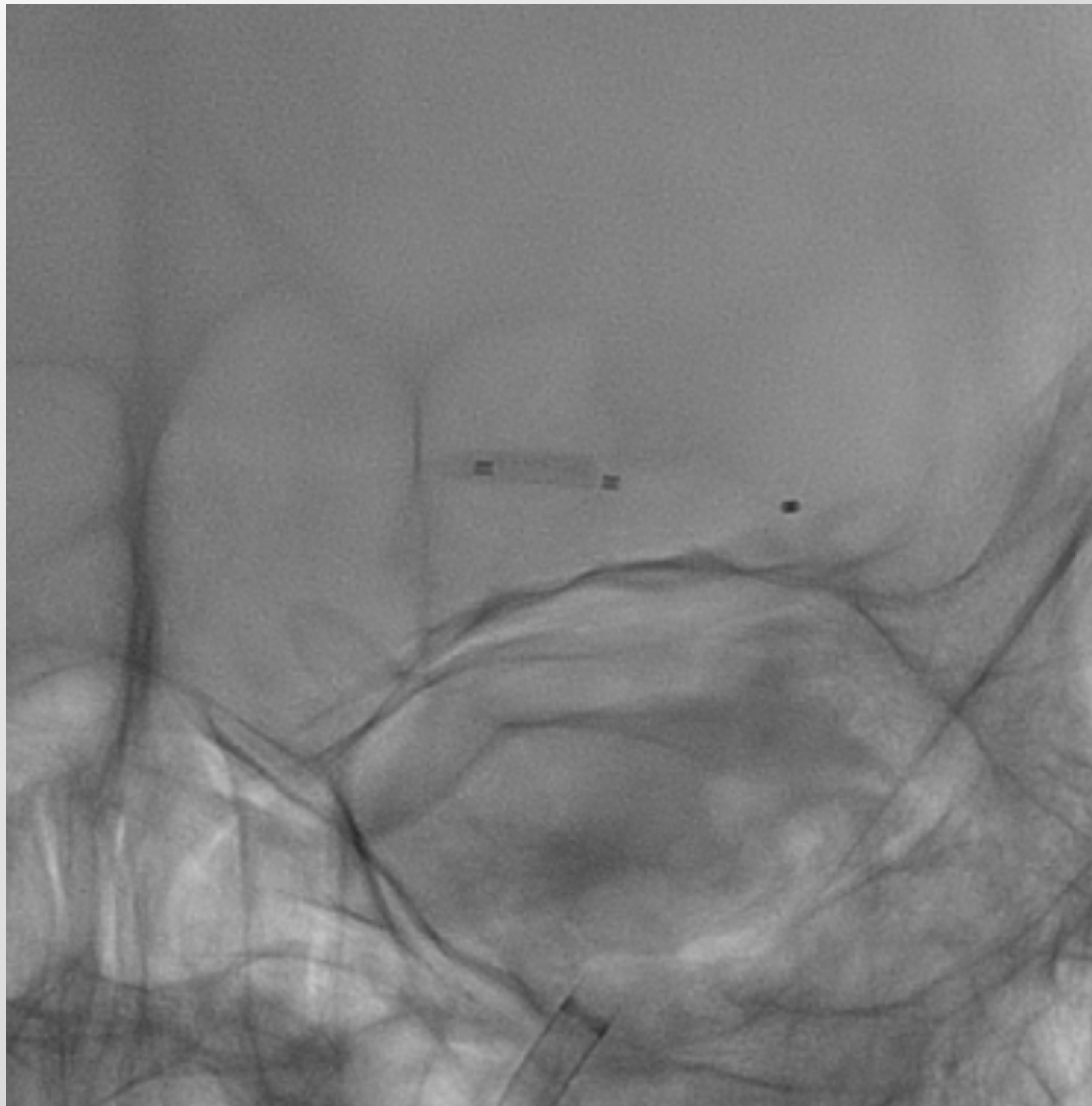
American Journal of Neuroradiology Mar 2015, 36 (3) 552-556; DOI: 10.3174/ajnr.A4133

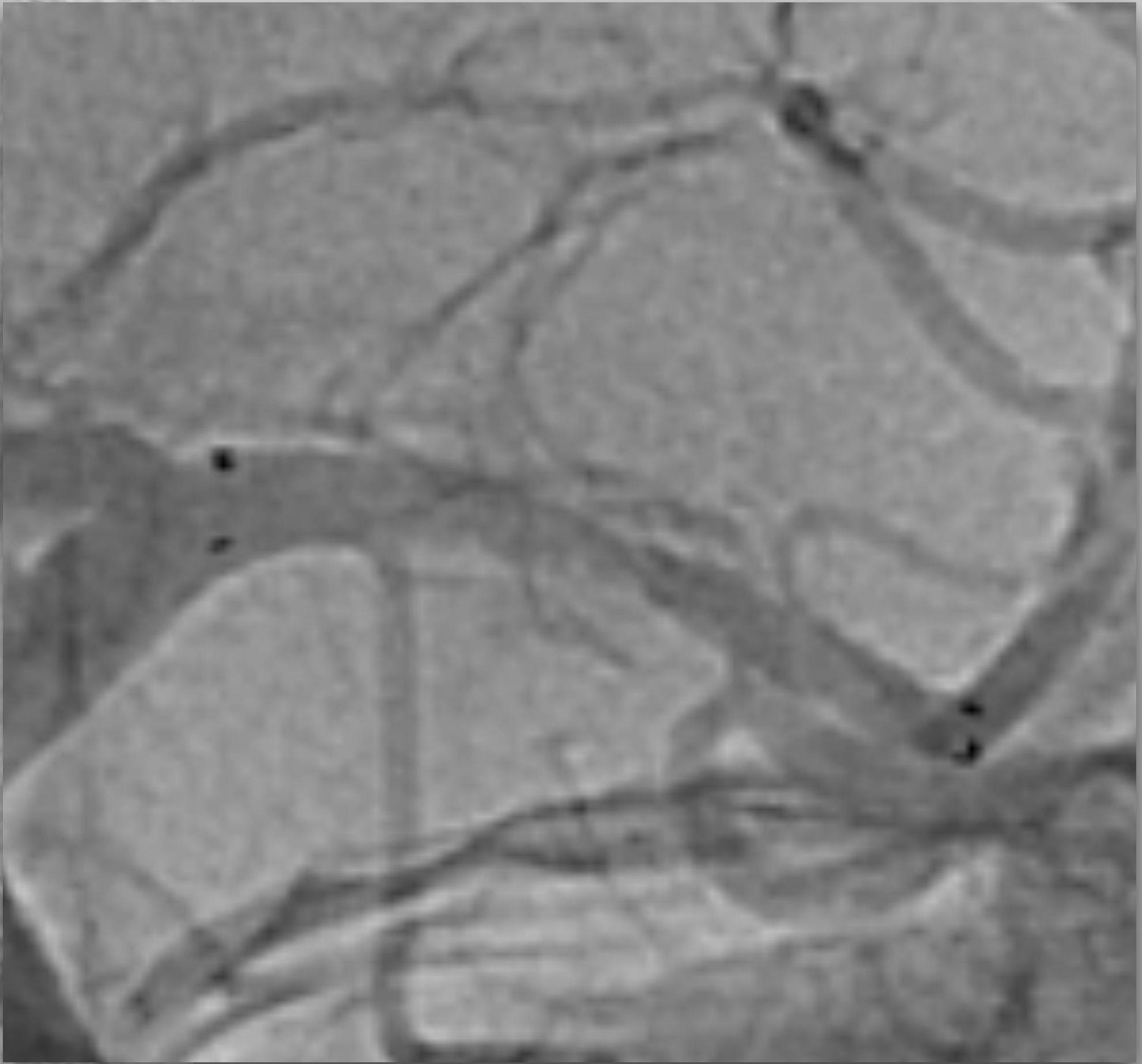
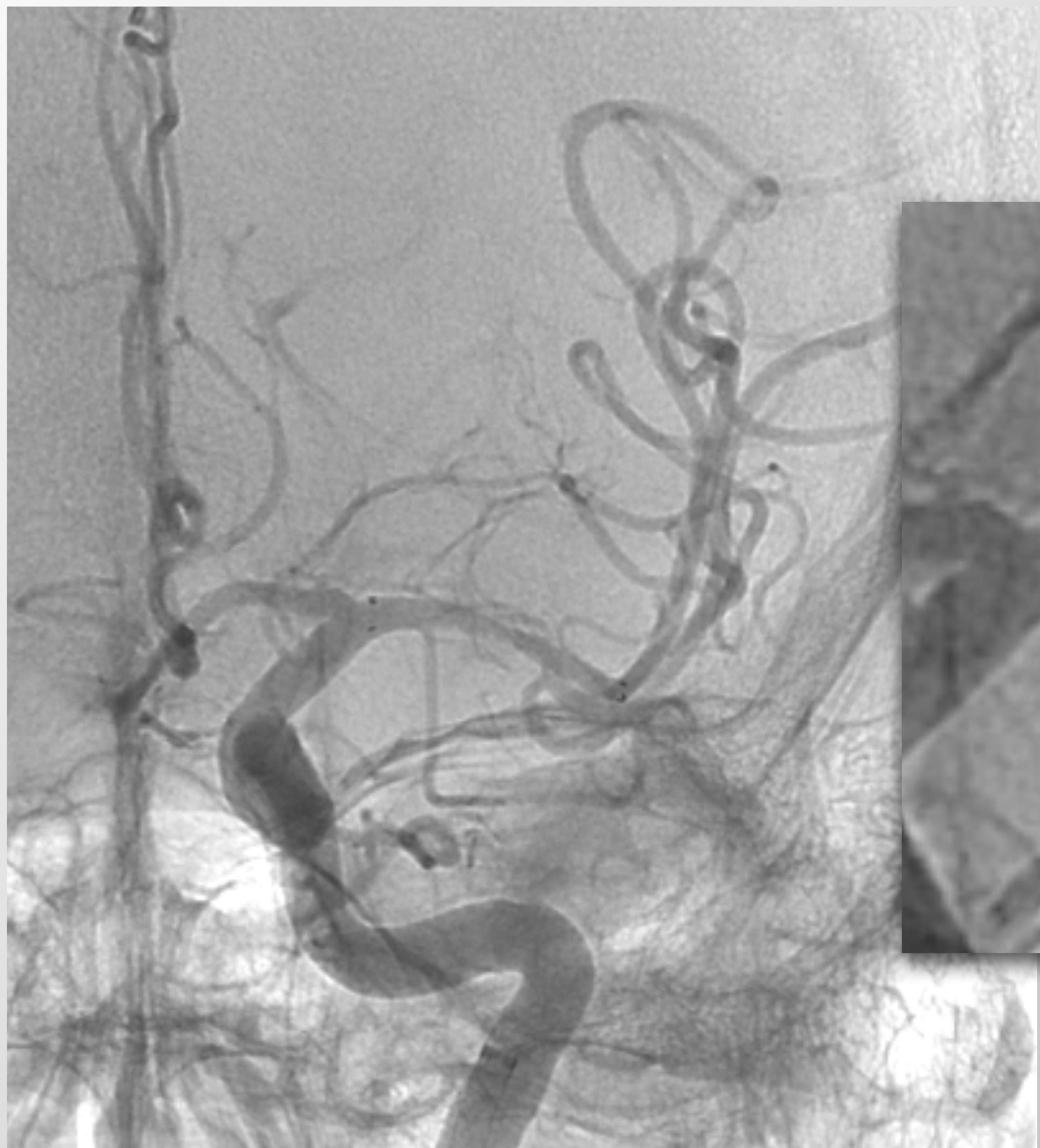


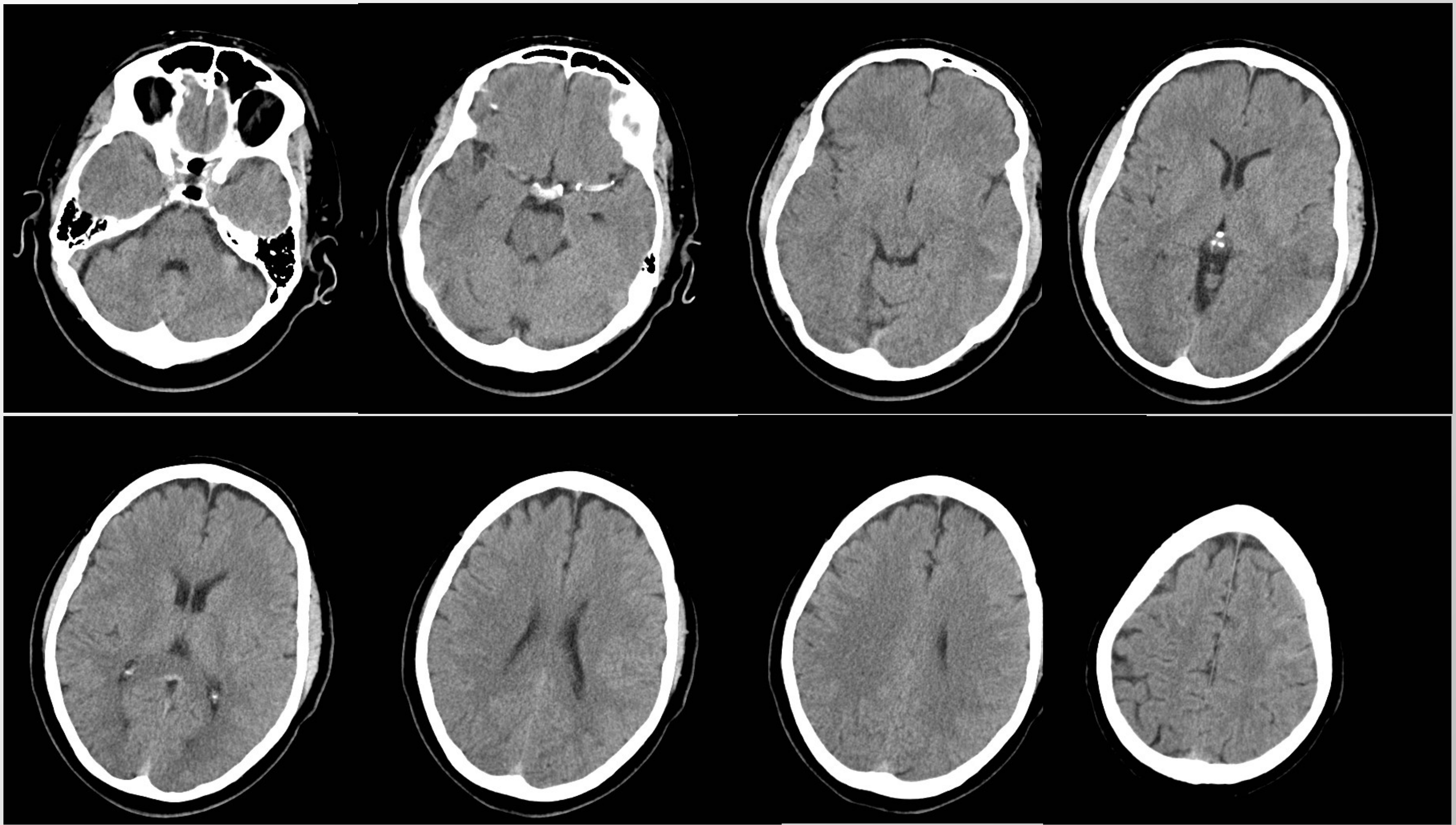




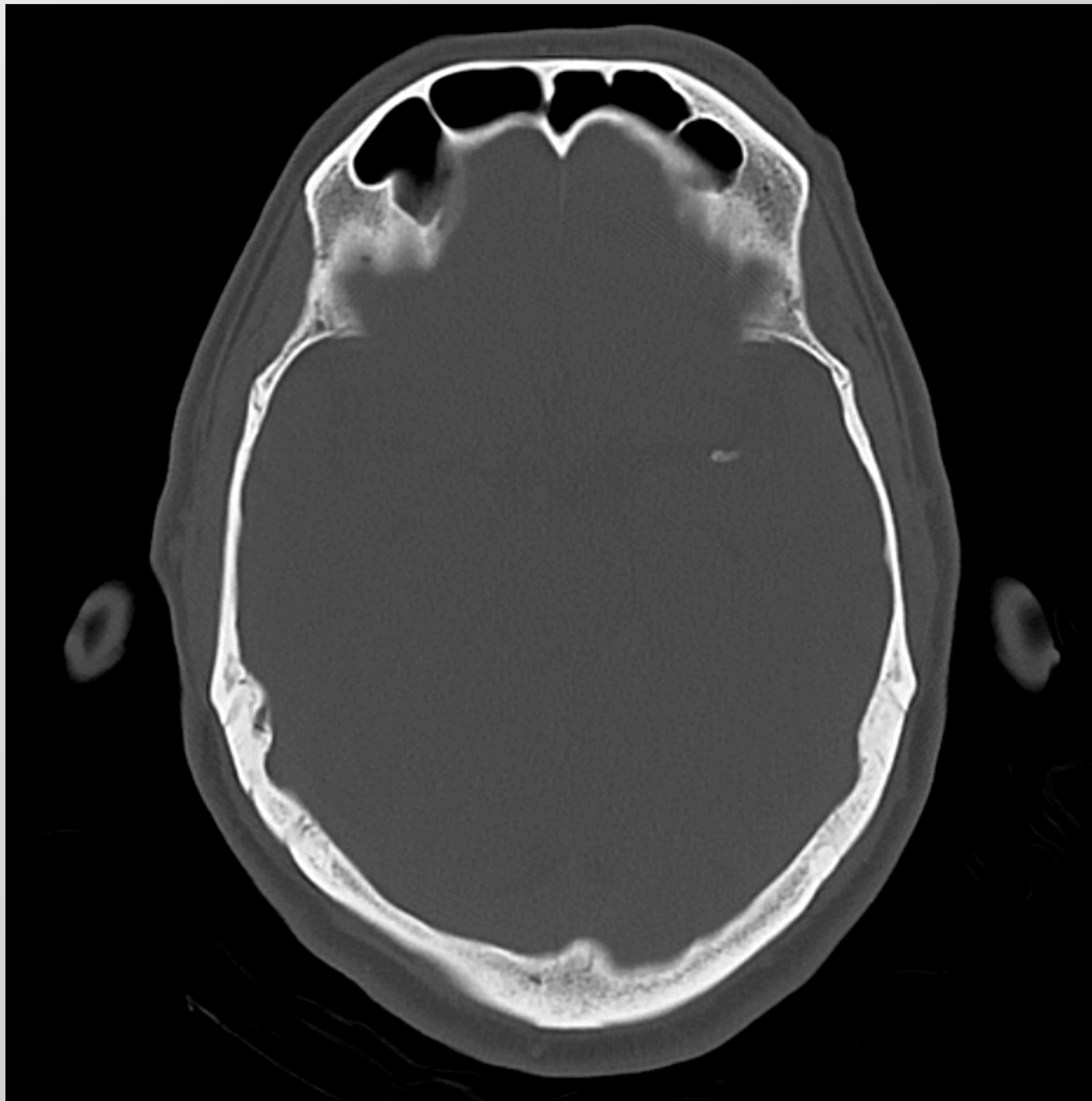
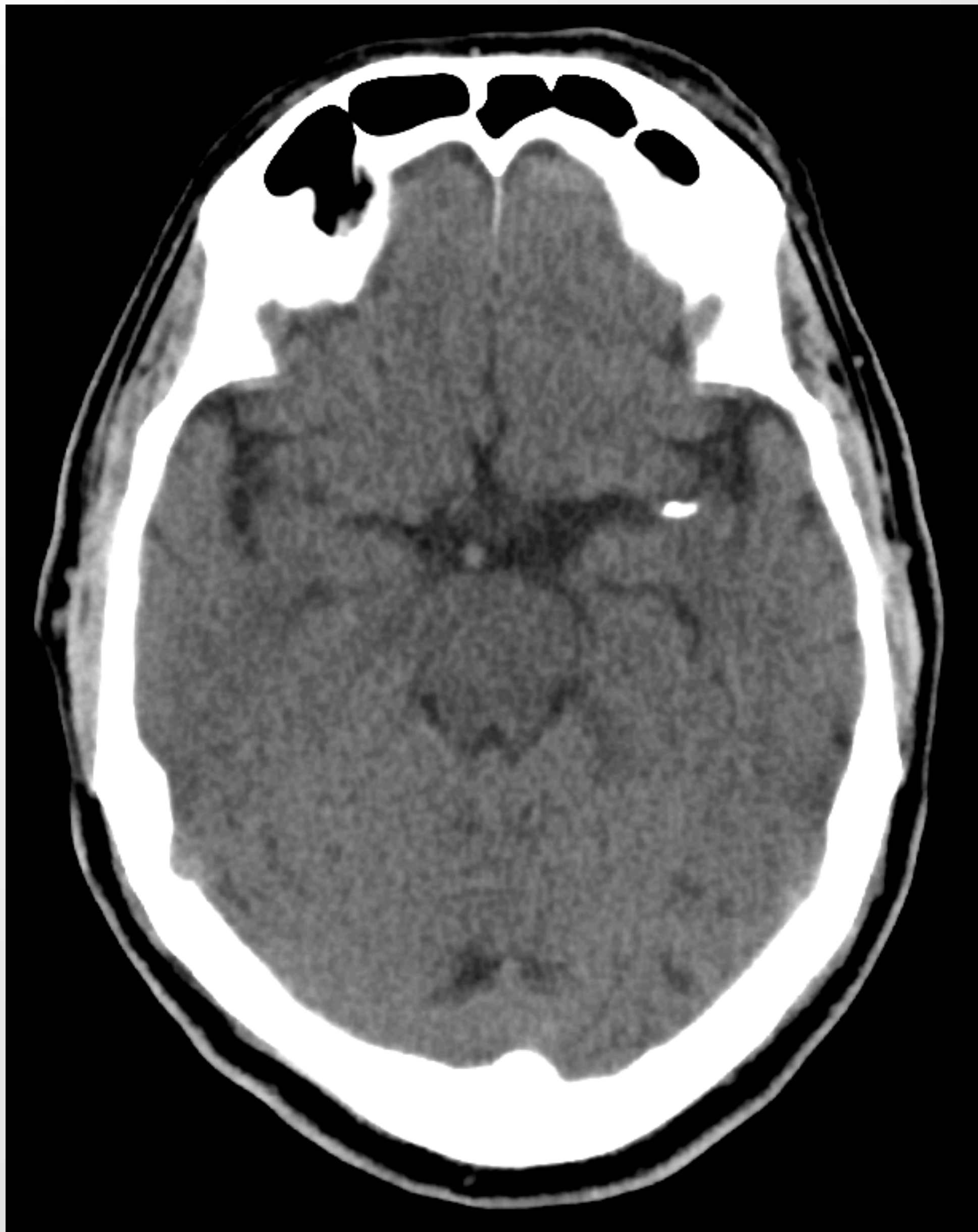

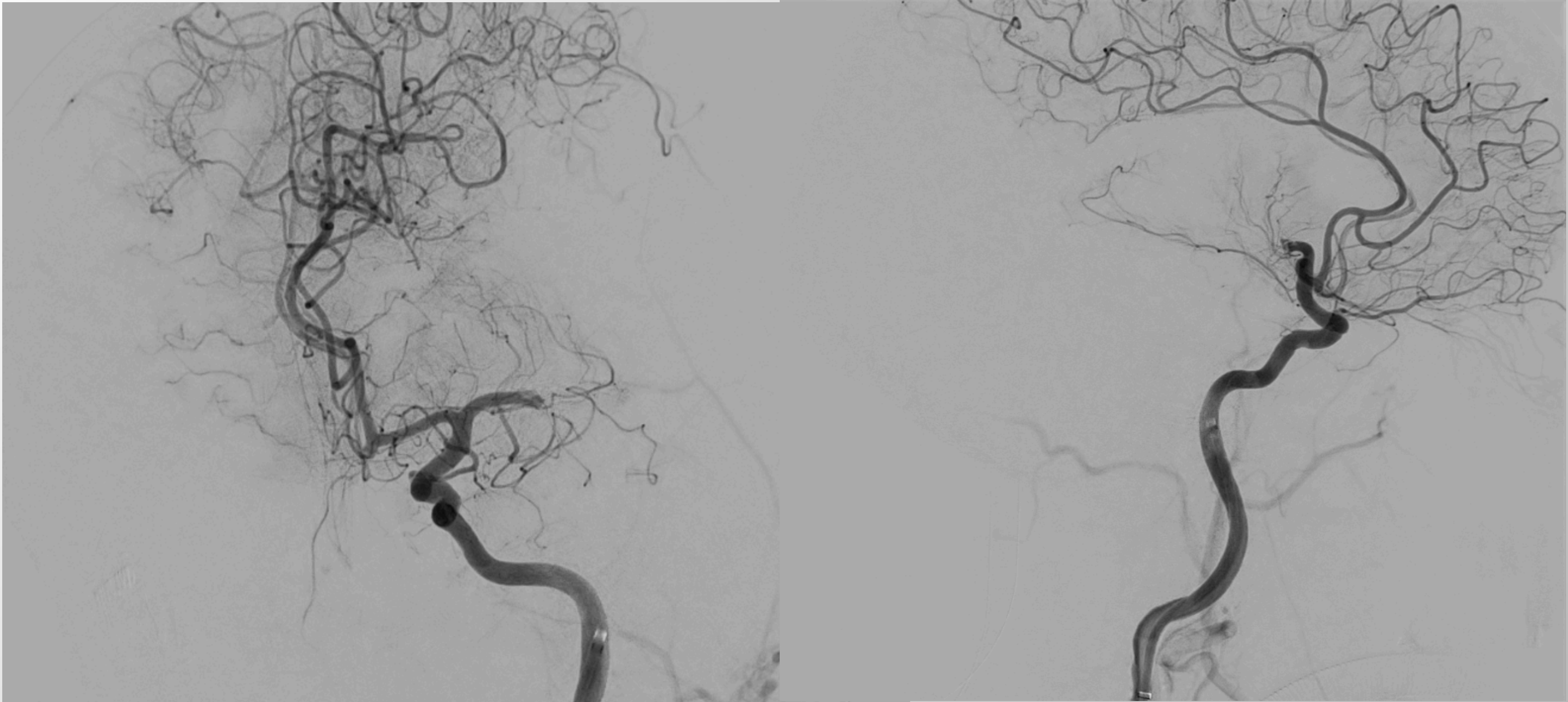


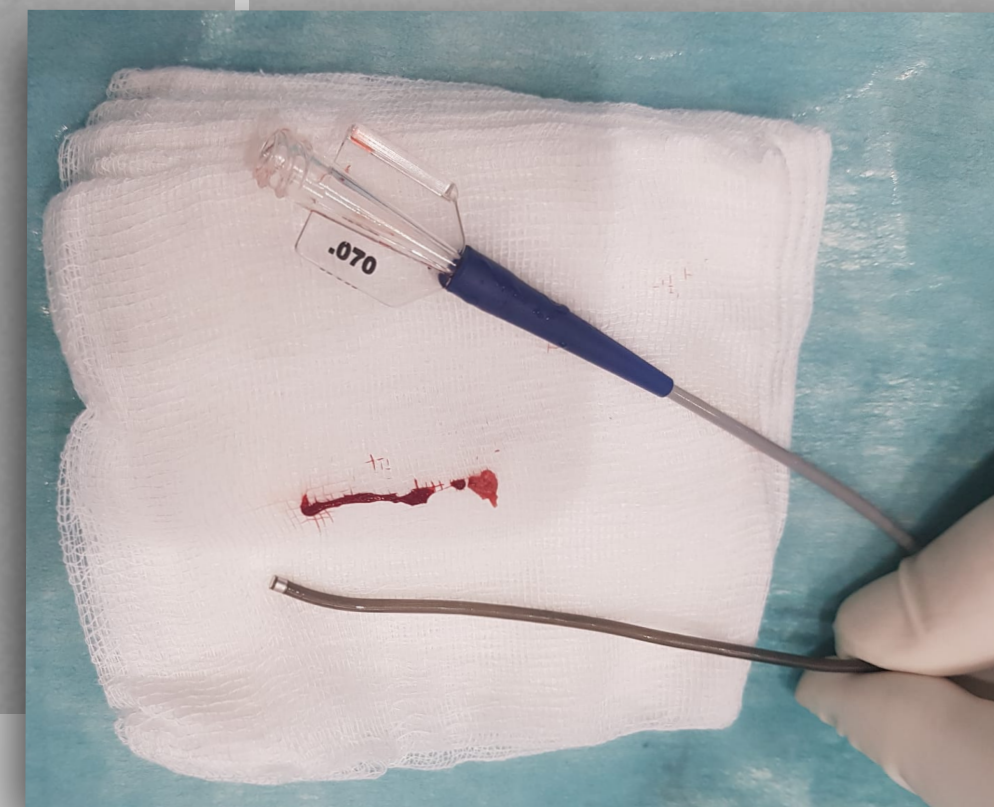
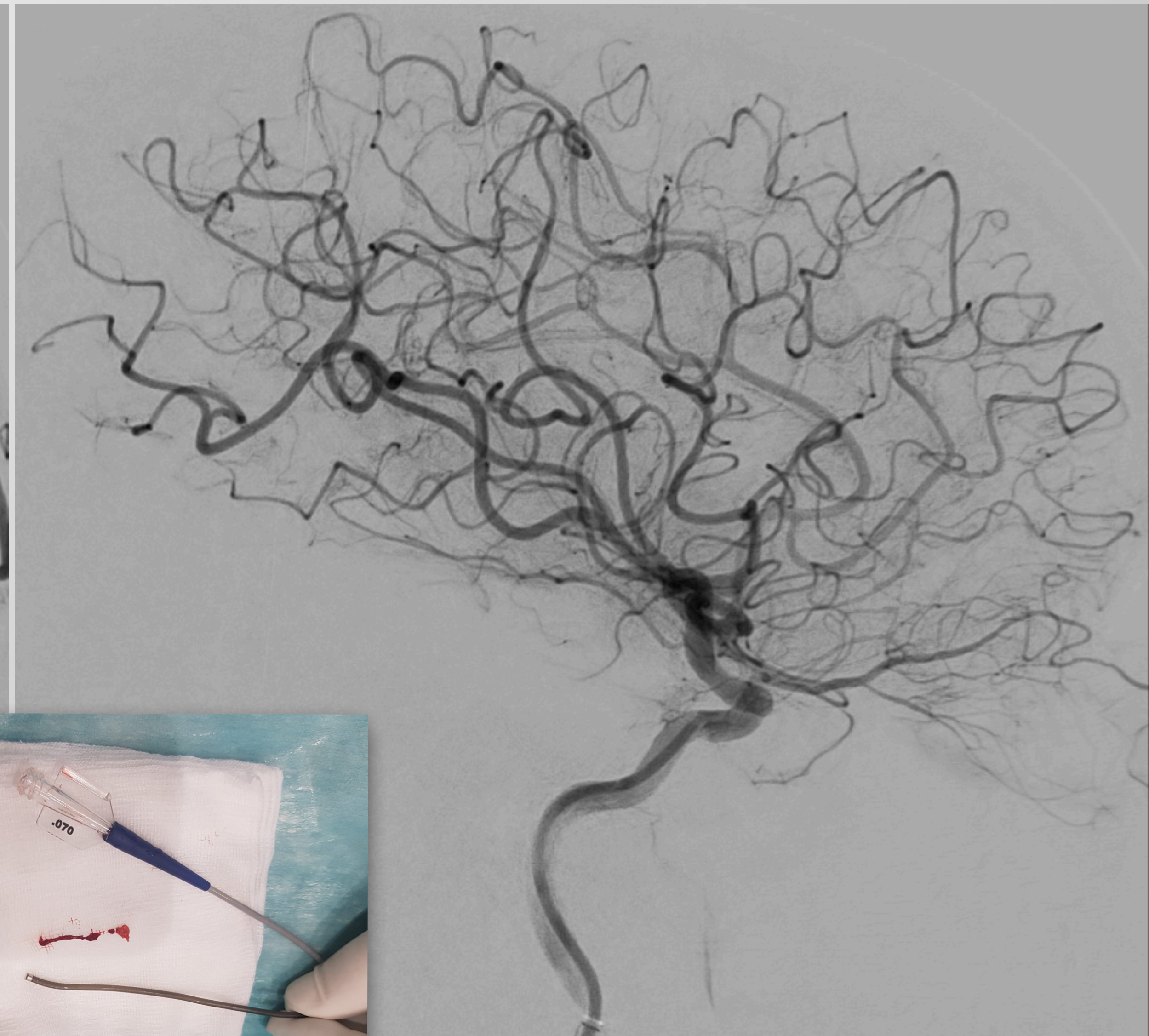
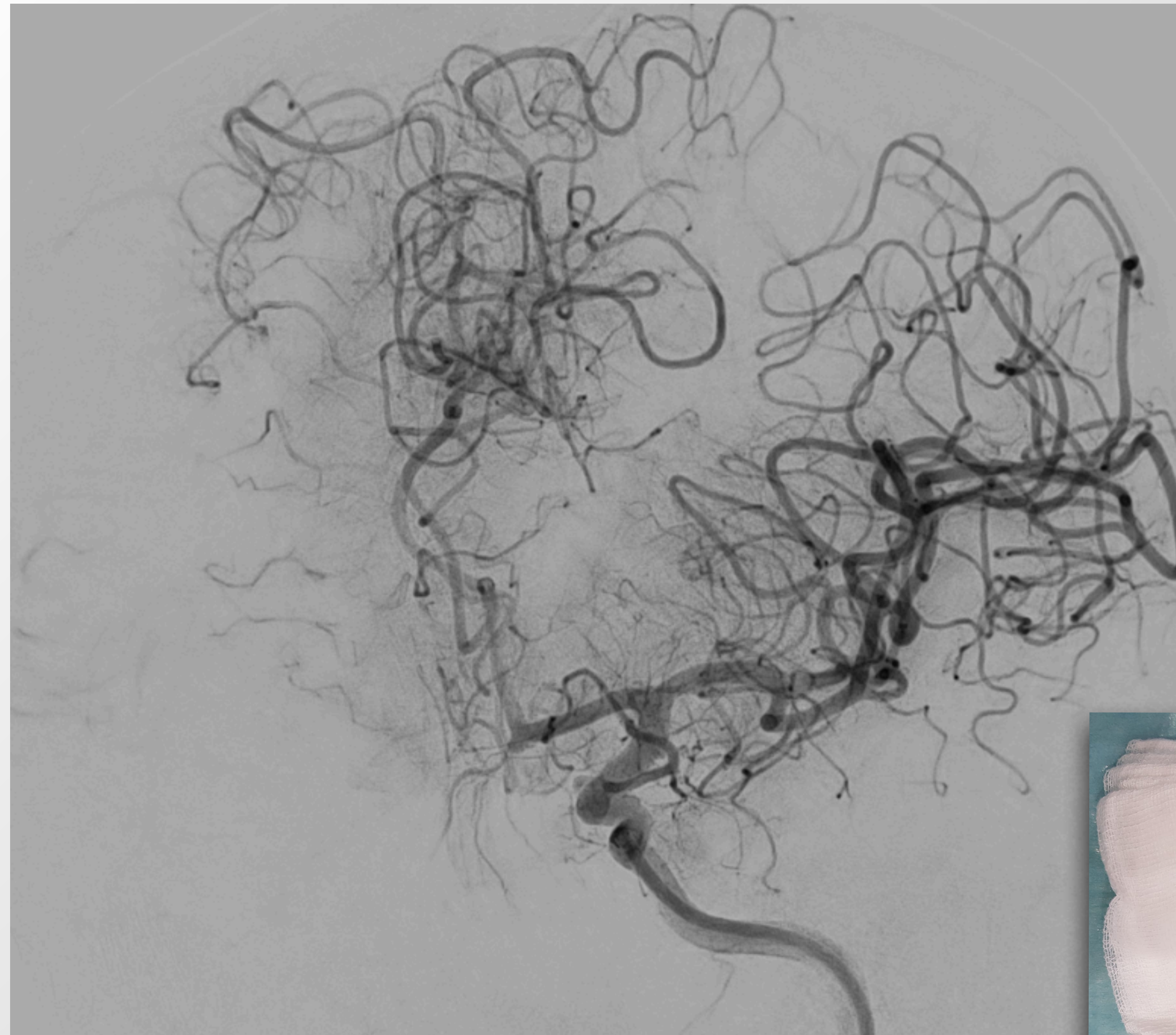




24h CT

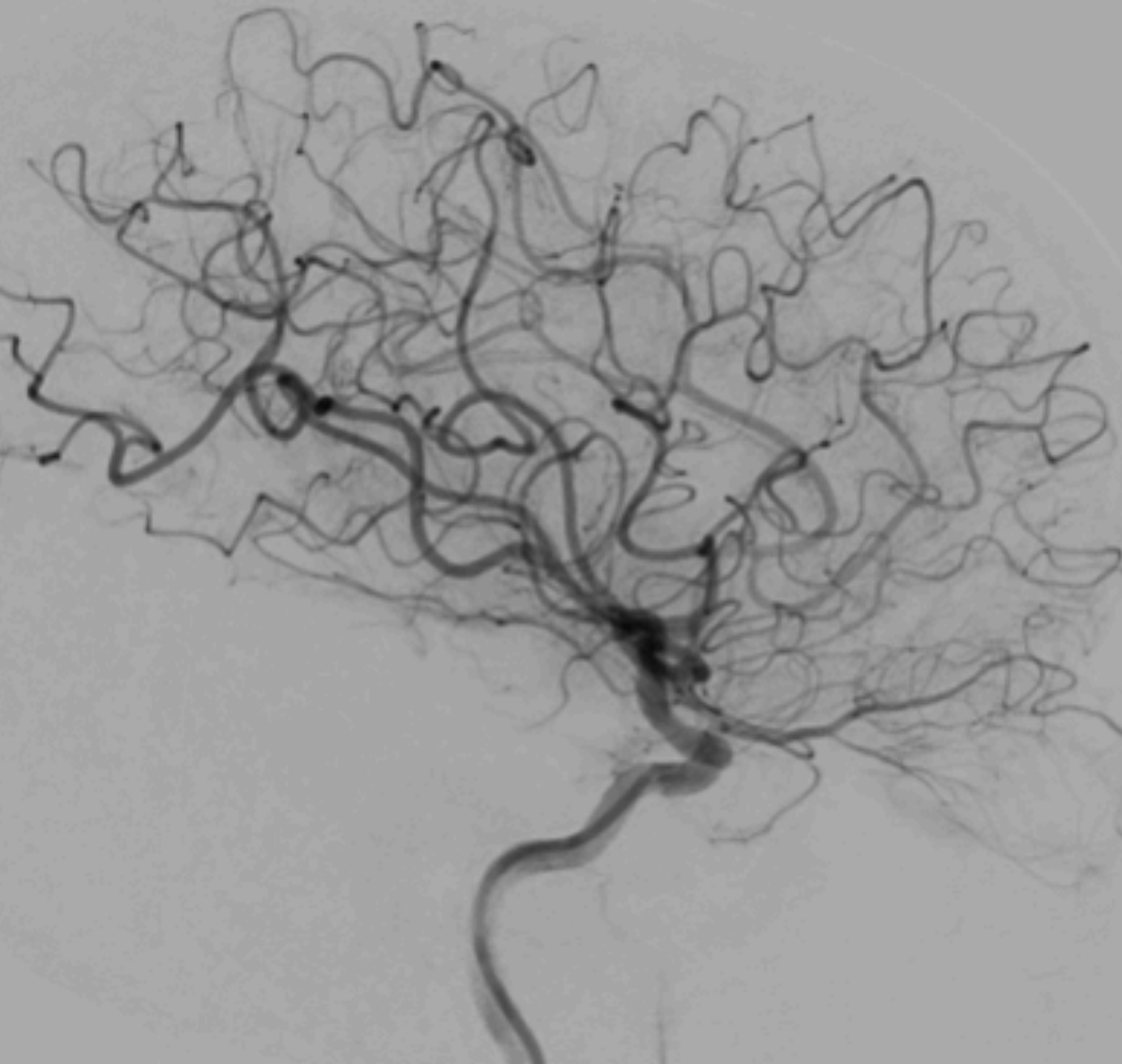
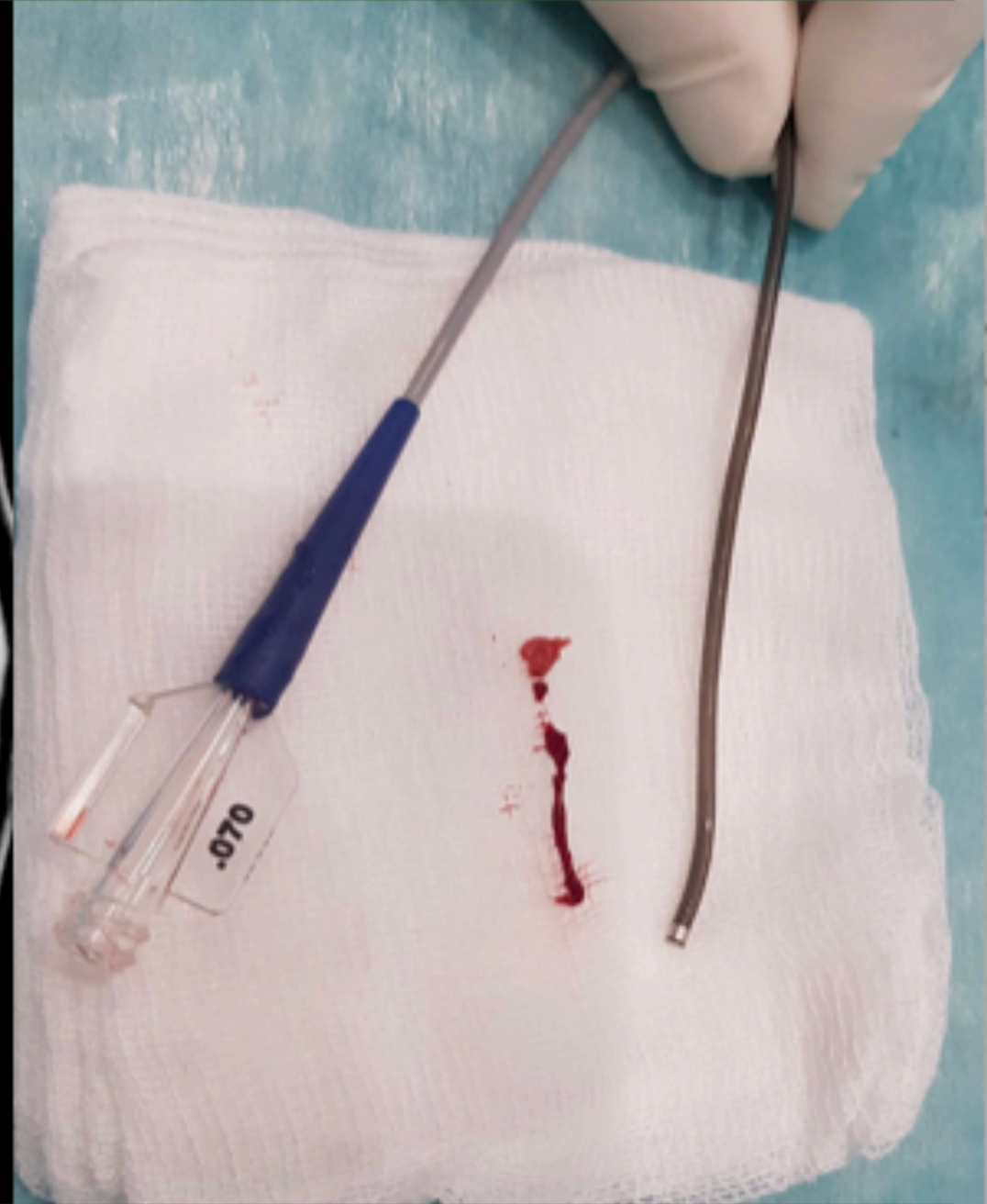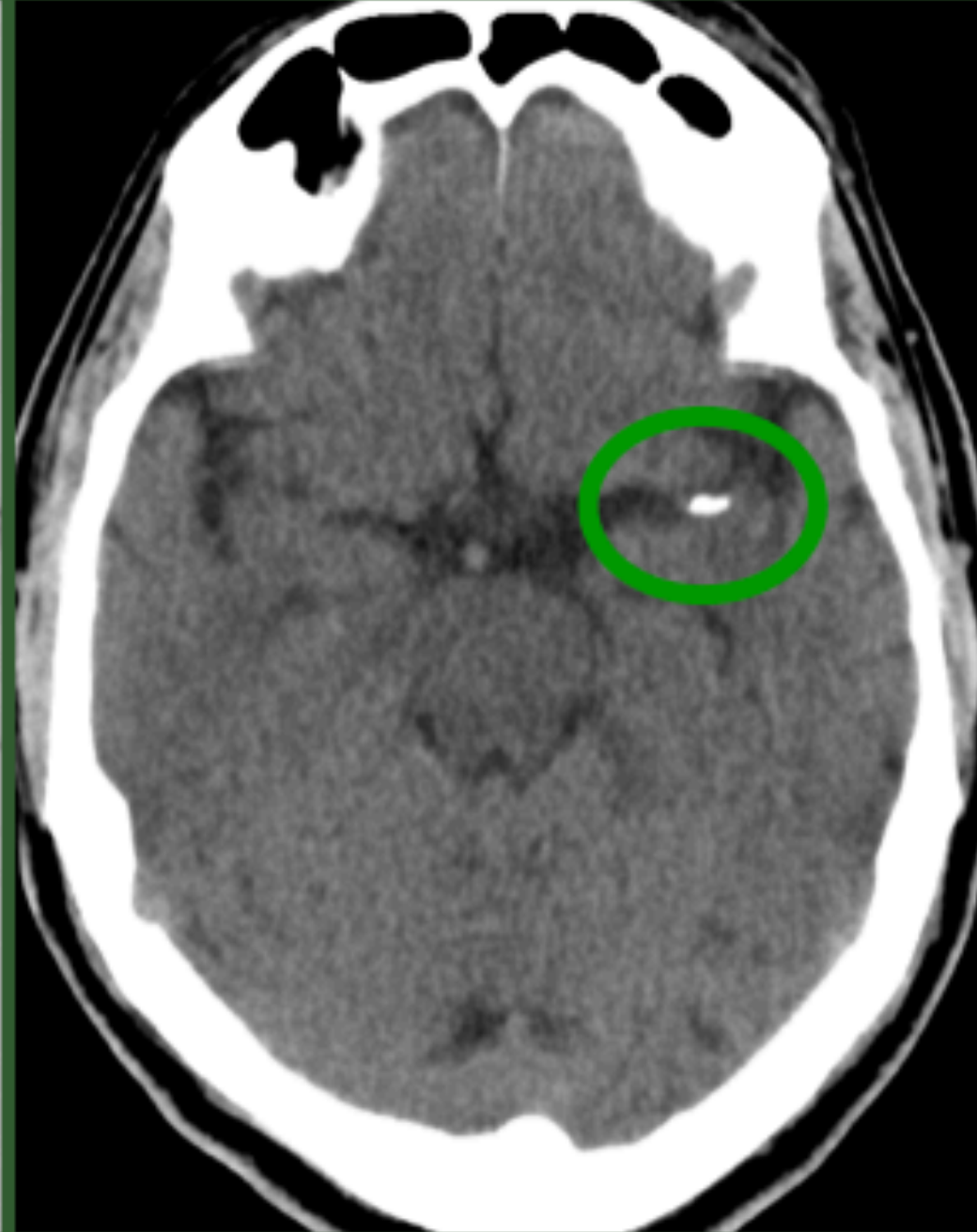
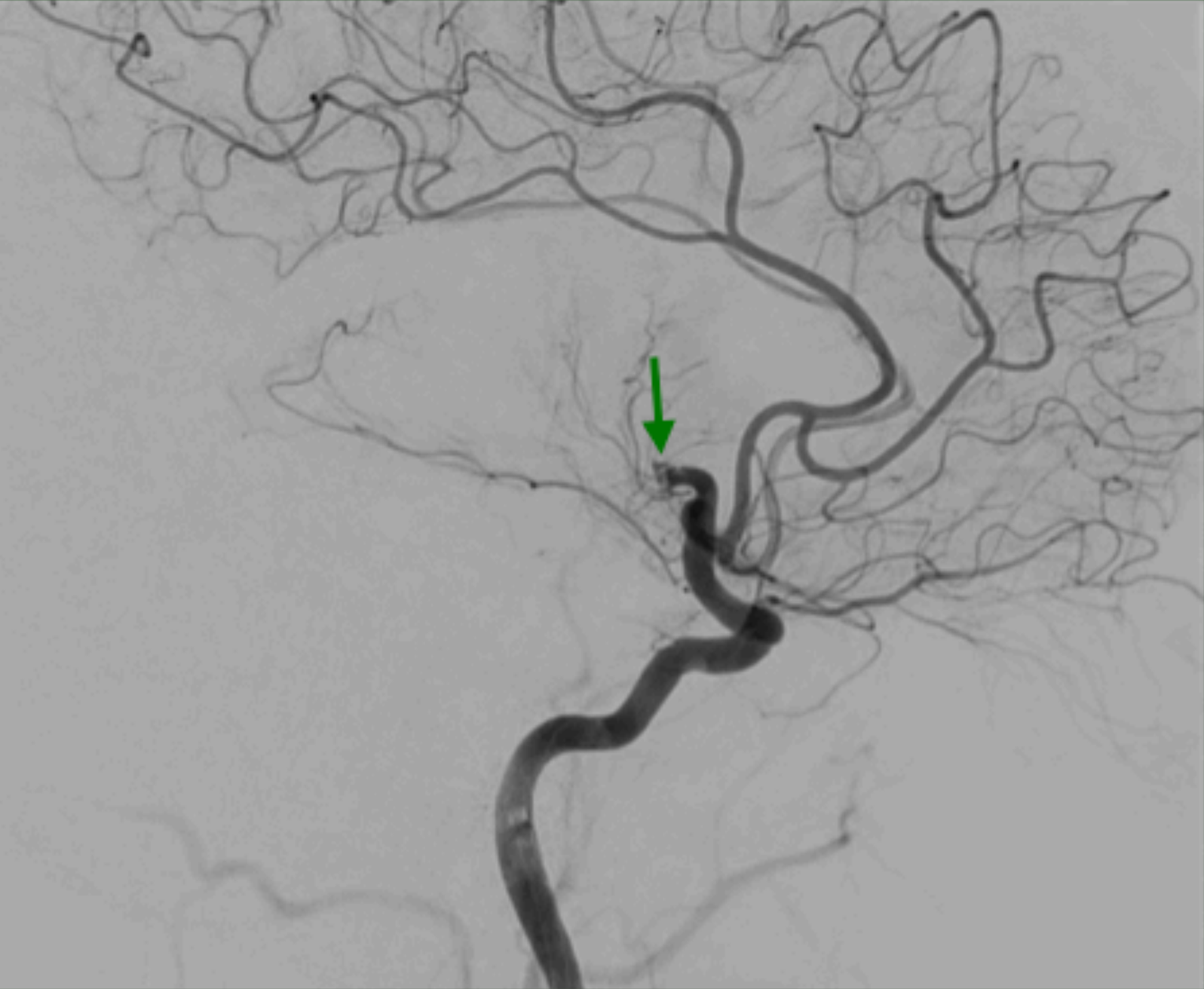


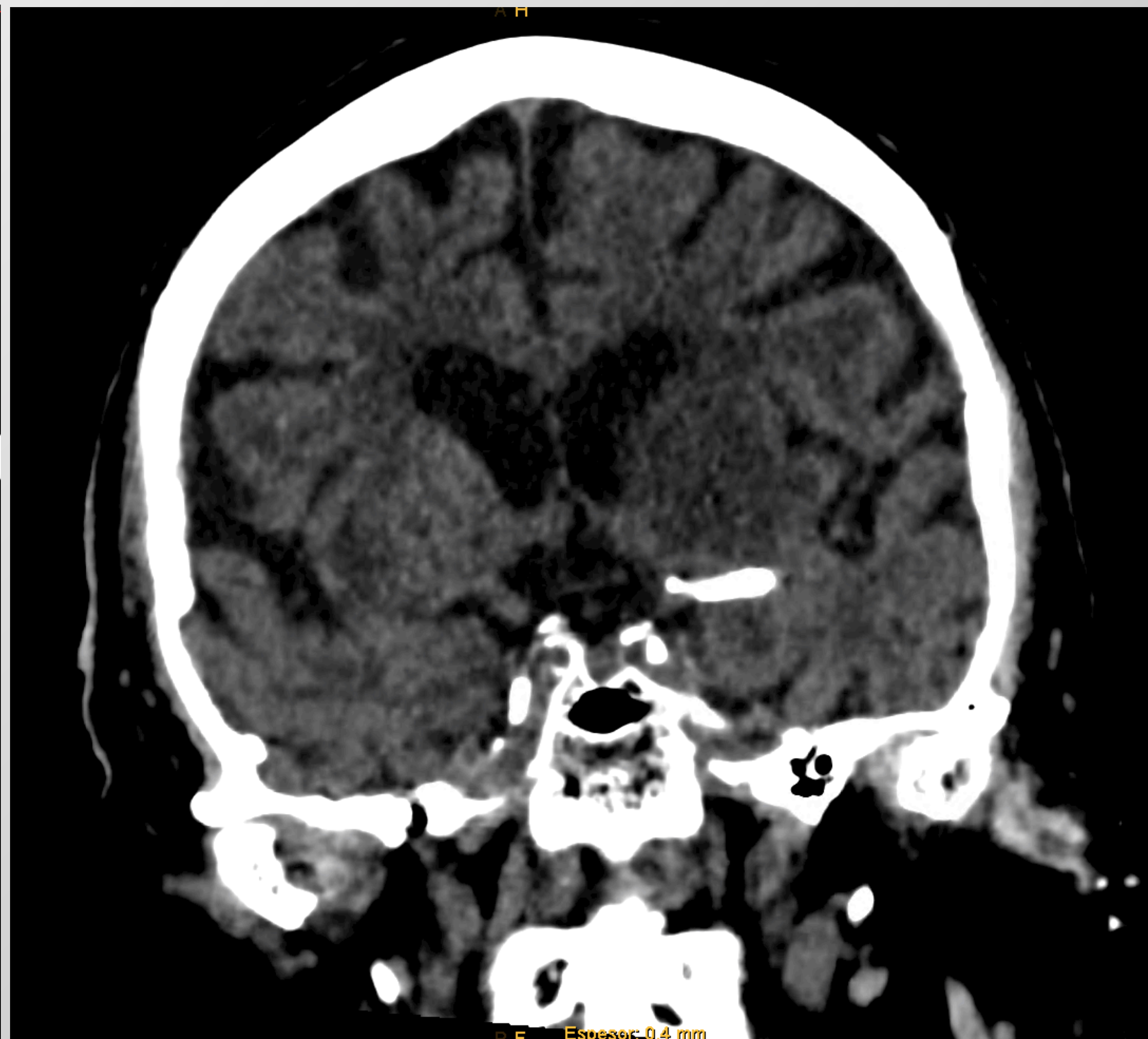
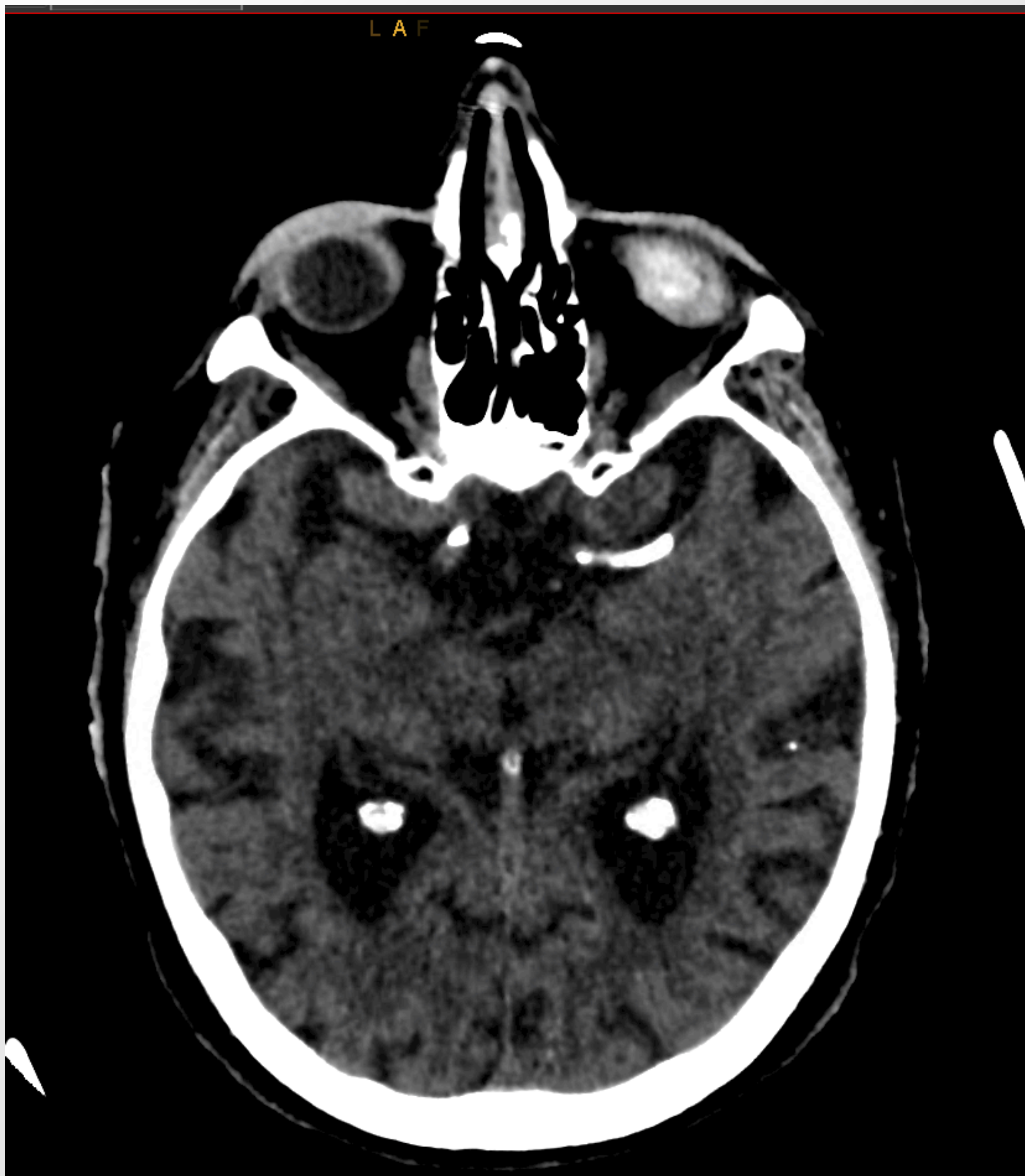


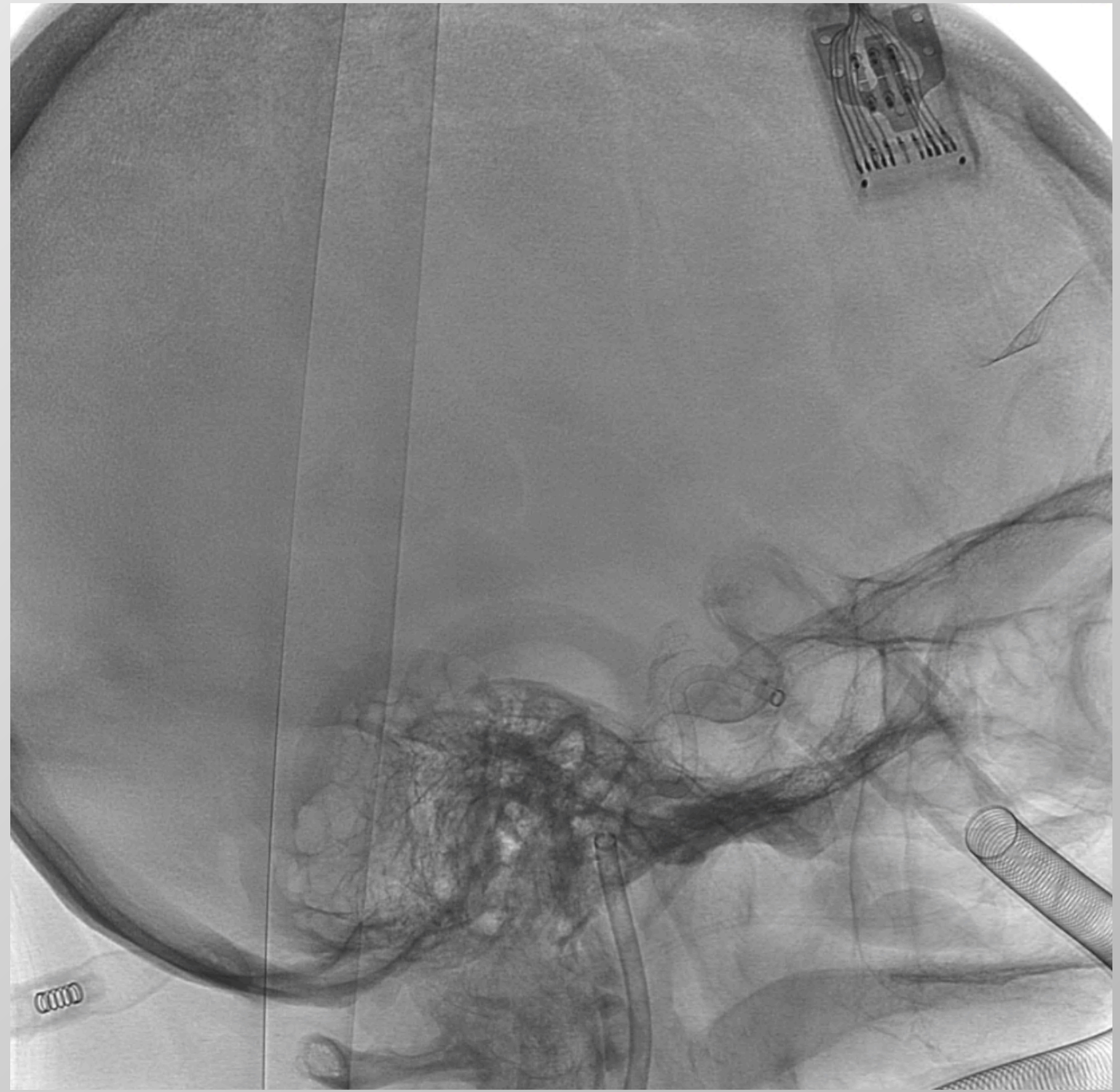

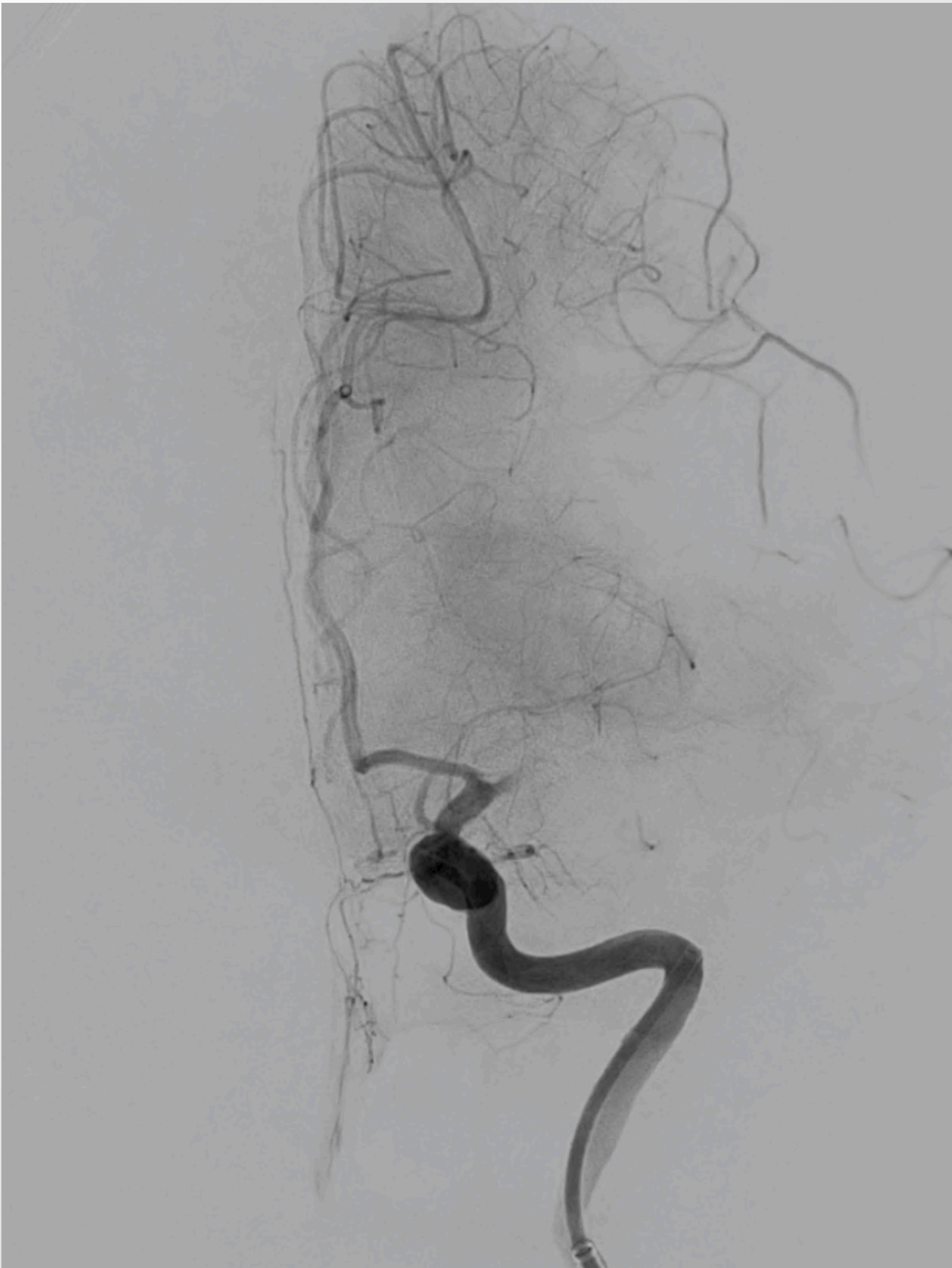
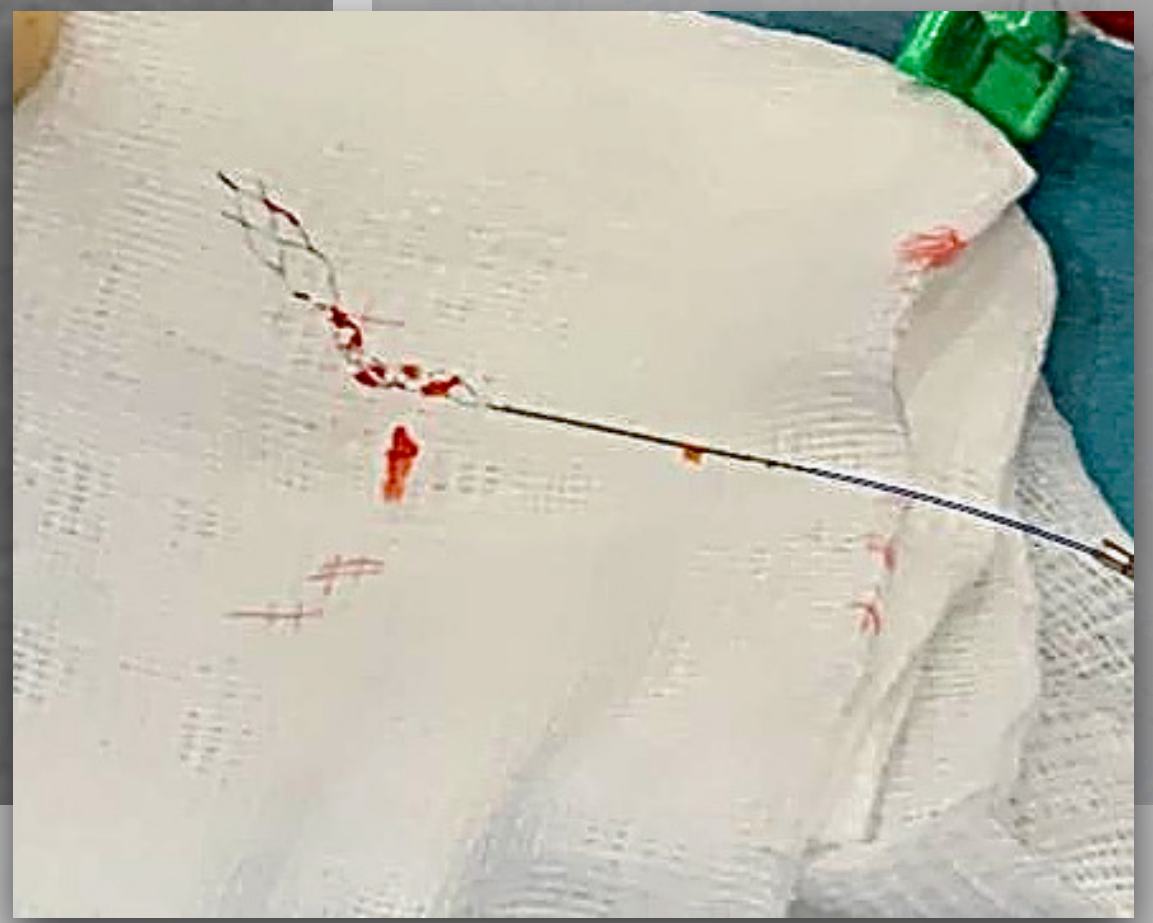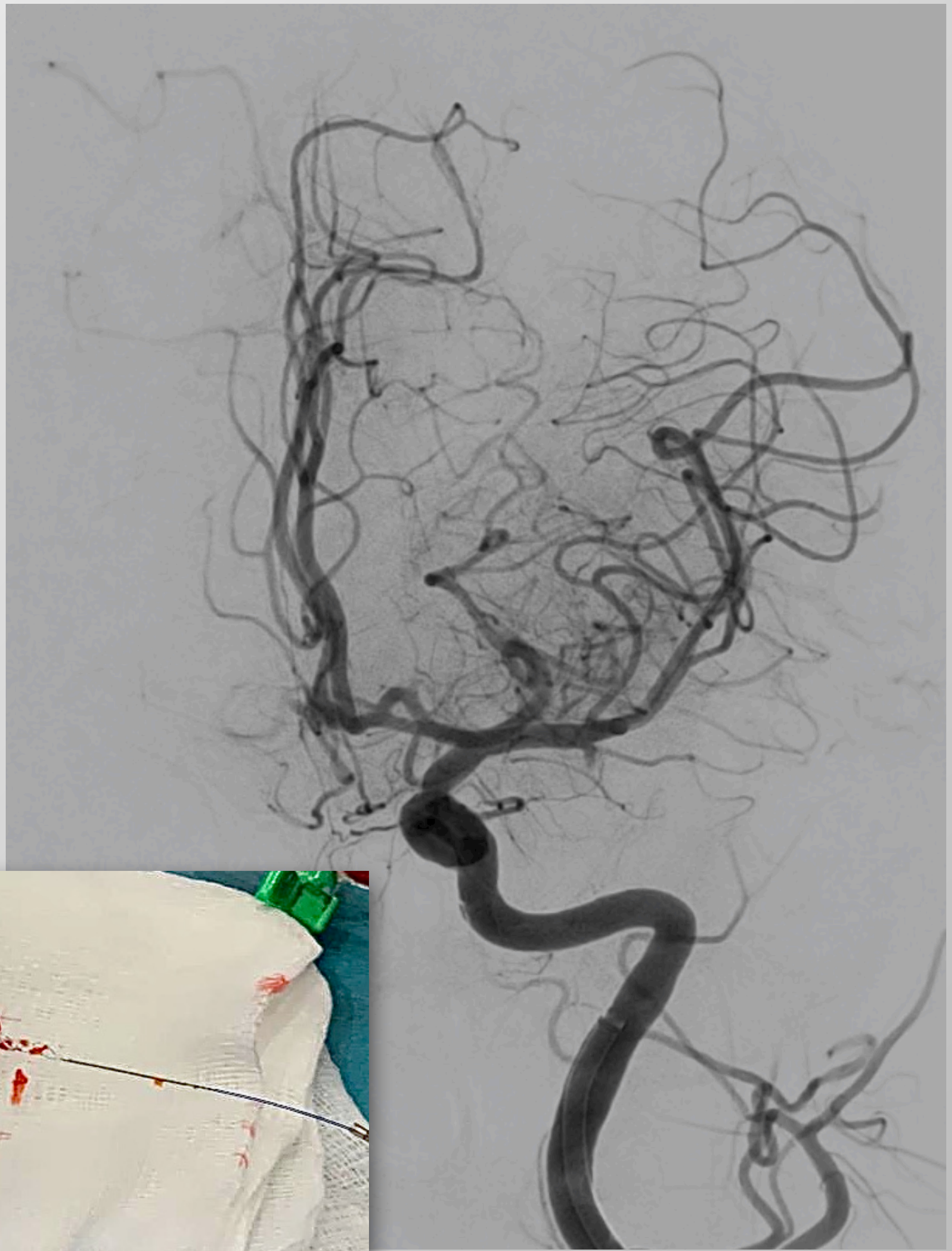
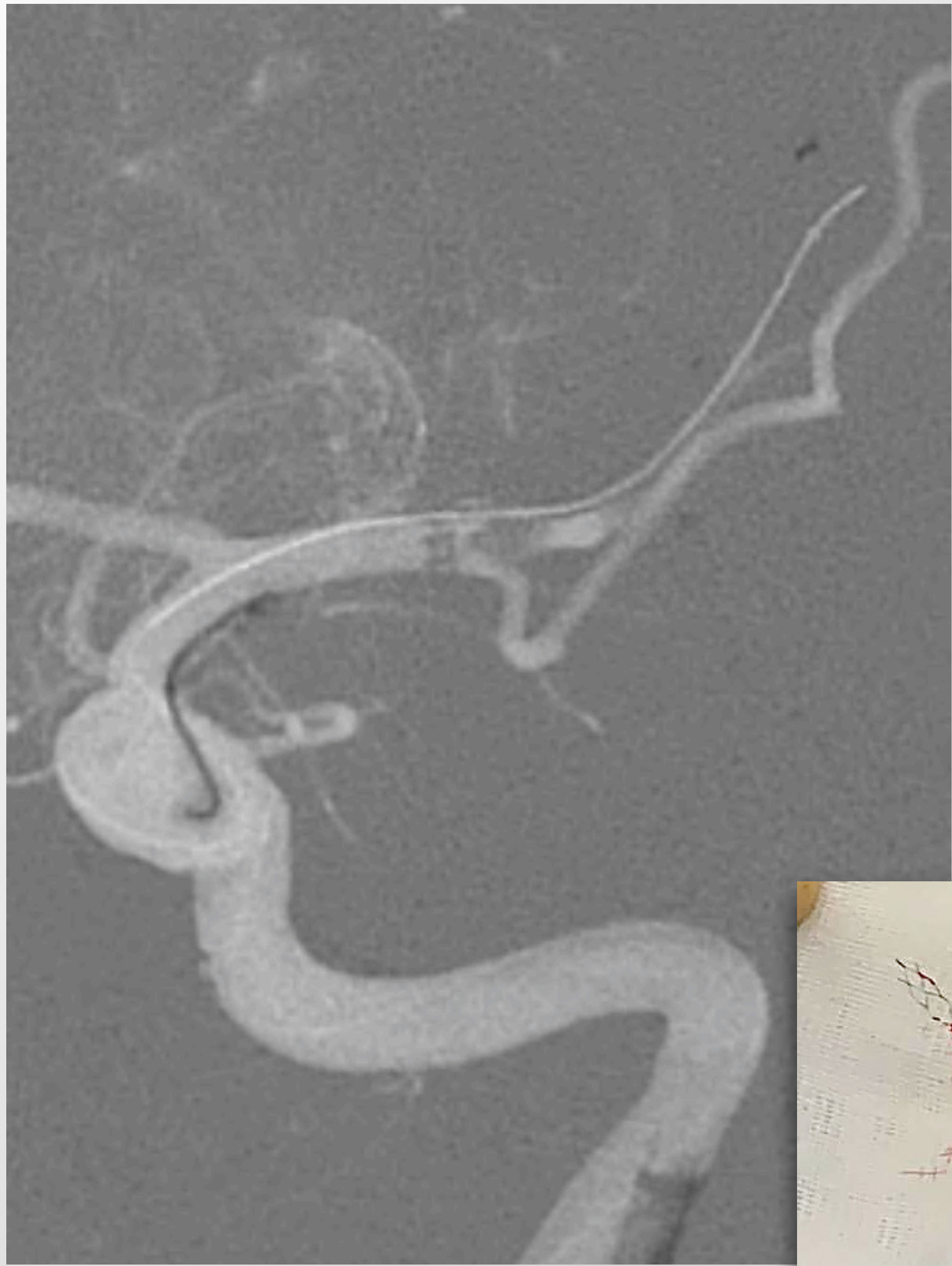NIHSS PRE 20

NIHSS 24h 3



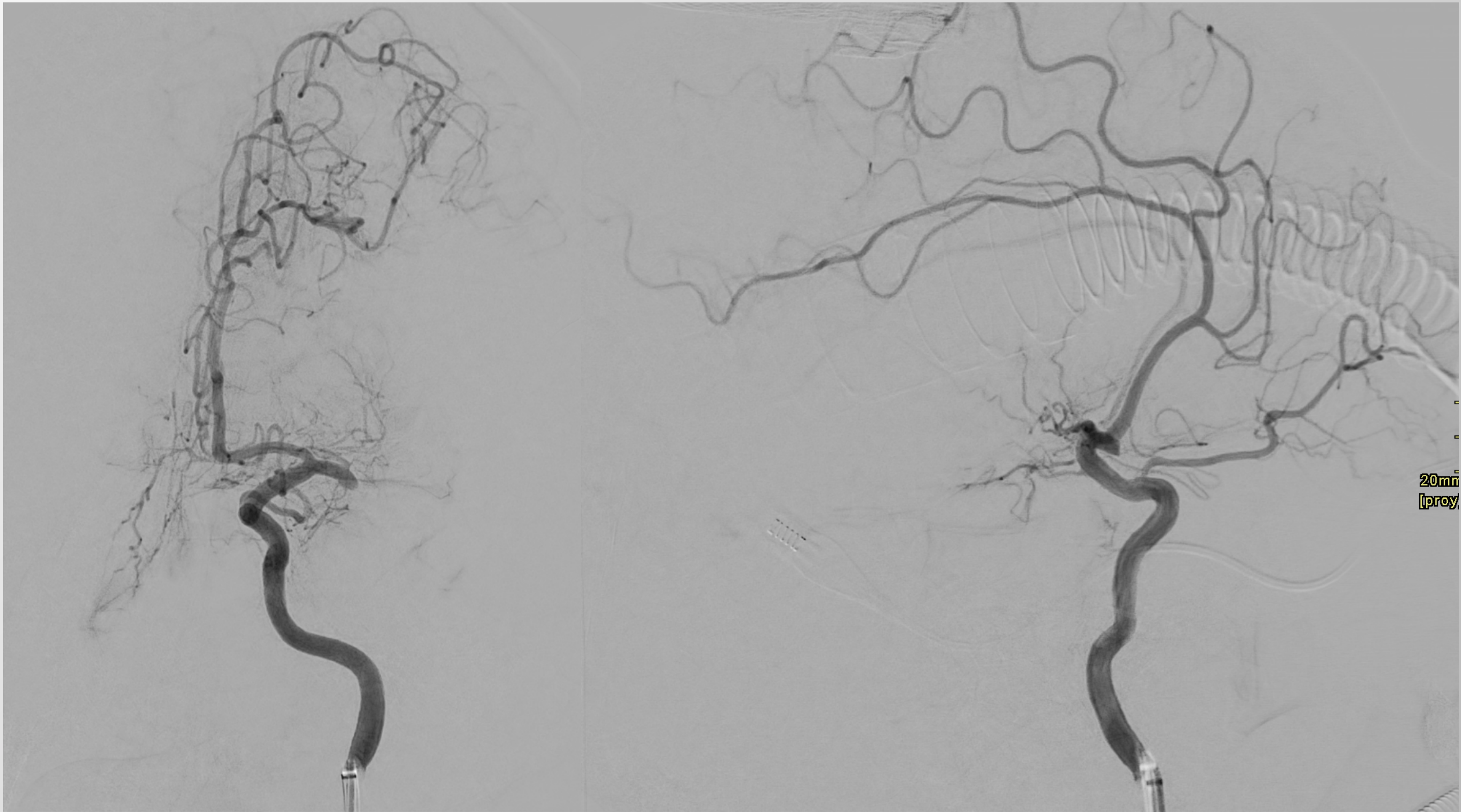




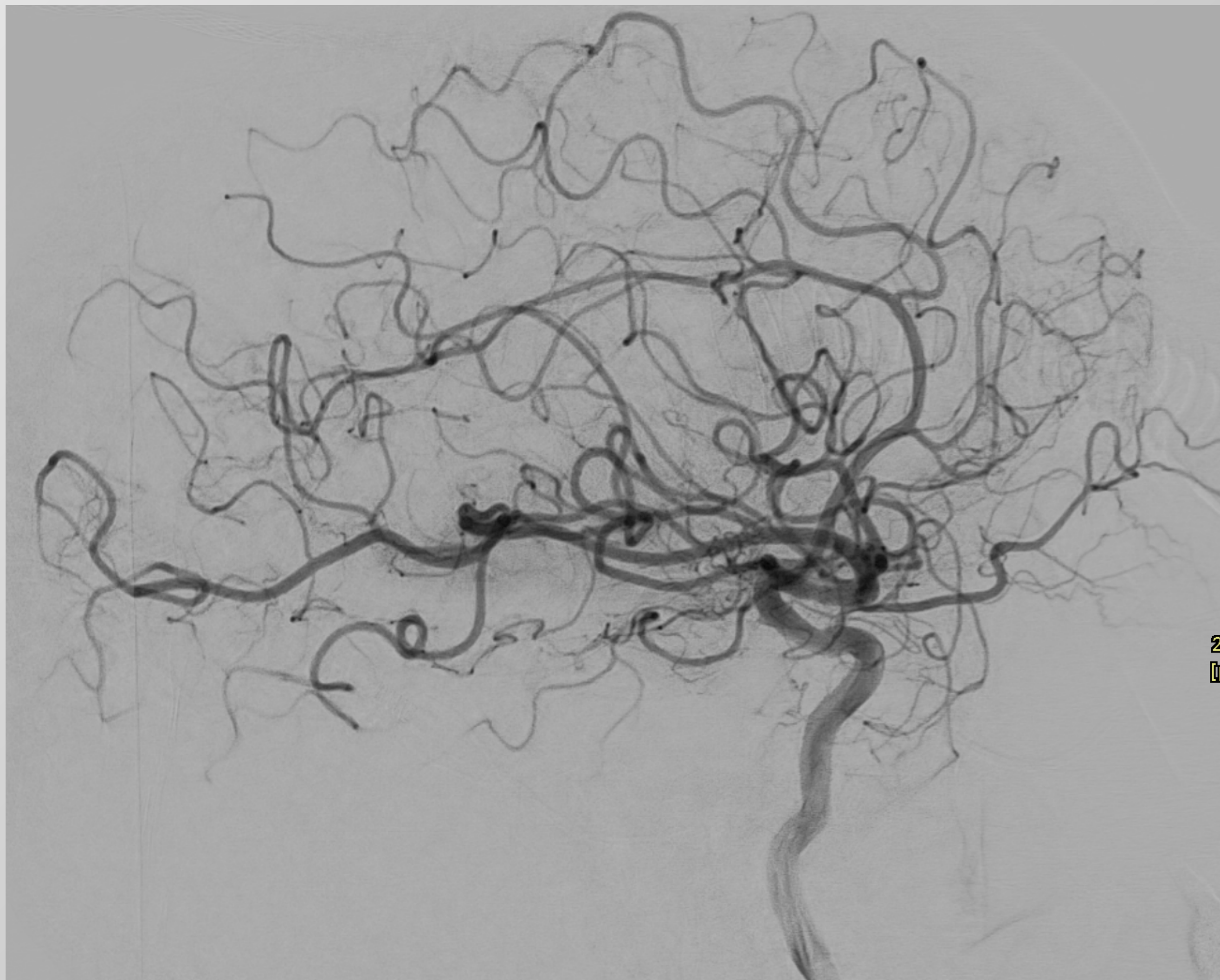
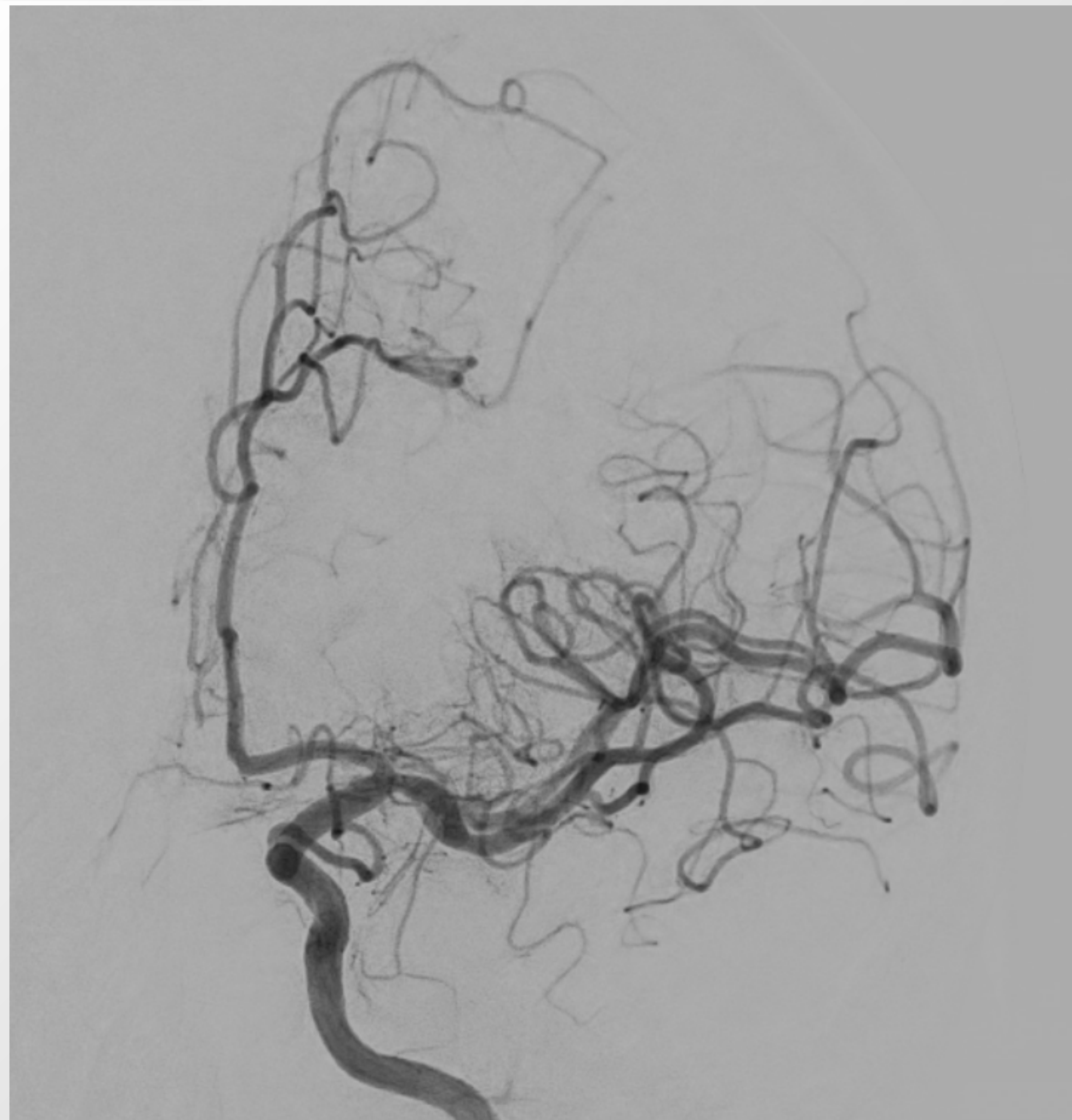


- 61 y/o
- NIHSS 20
- ASPECTS 10

Sept'20

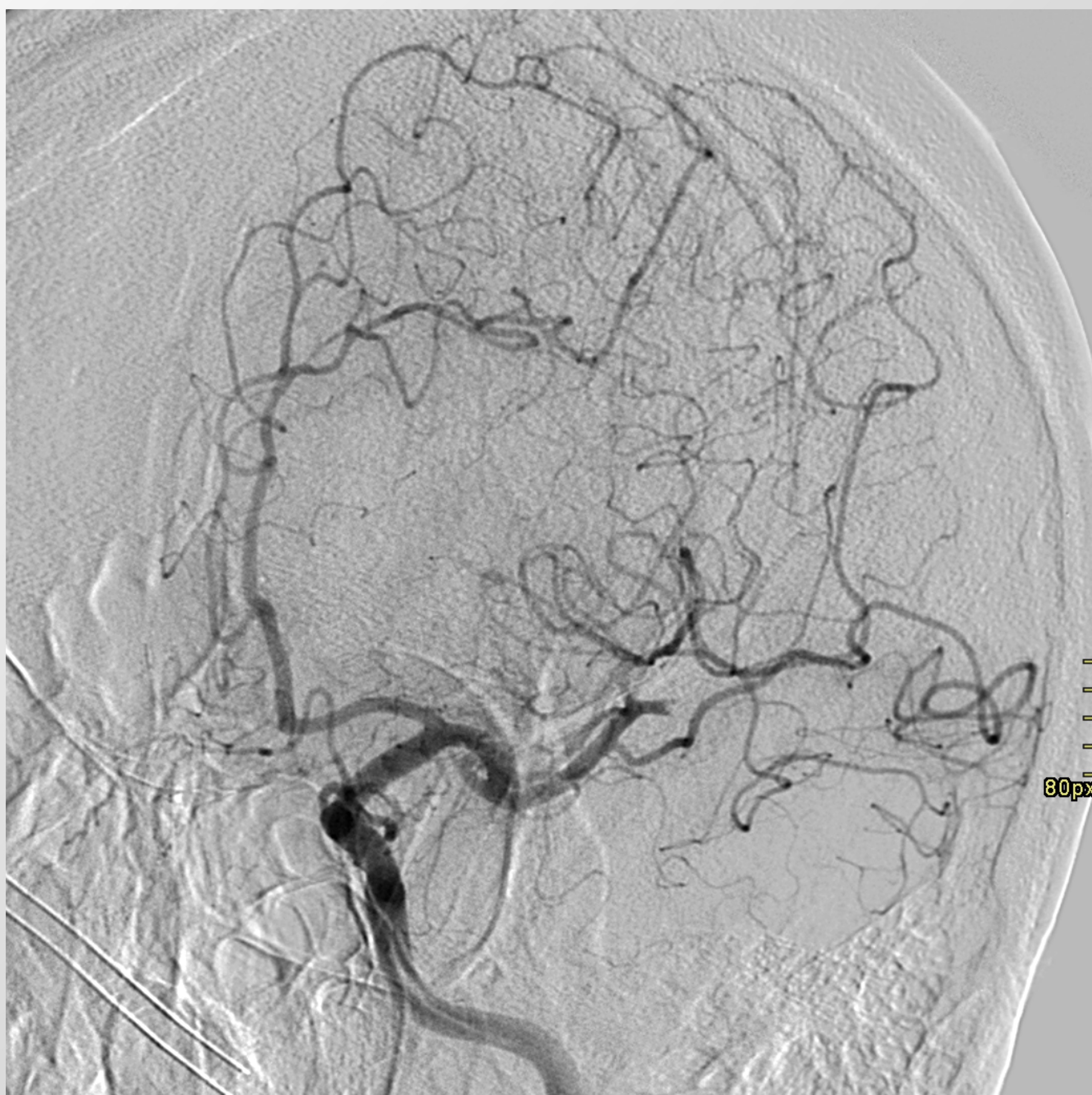

- P-R: 12min.
- NIHSS 24h: 6
- NIHSS alta: 0

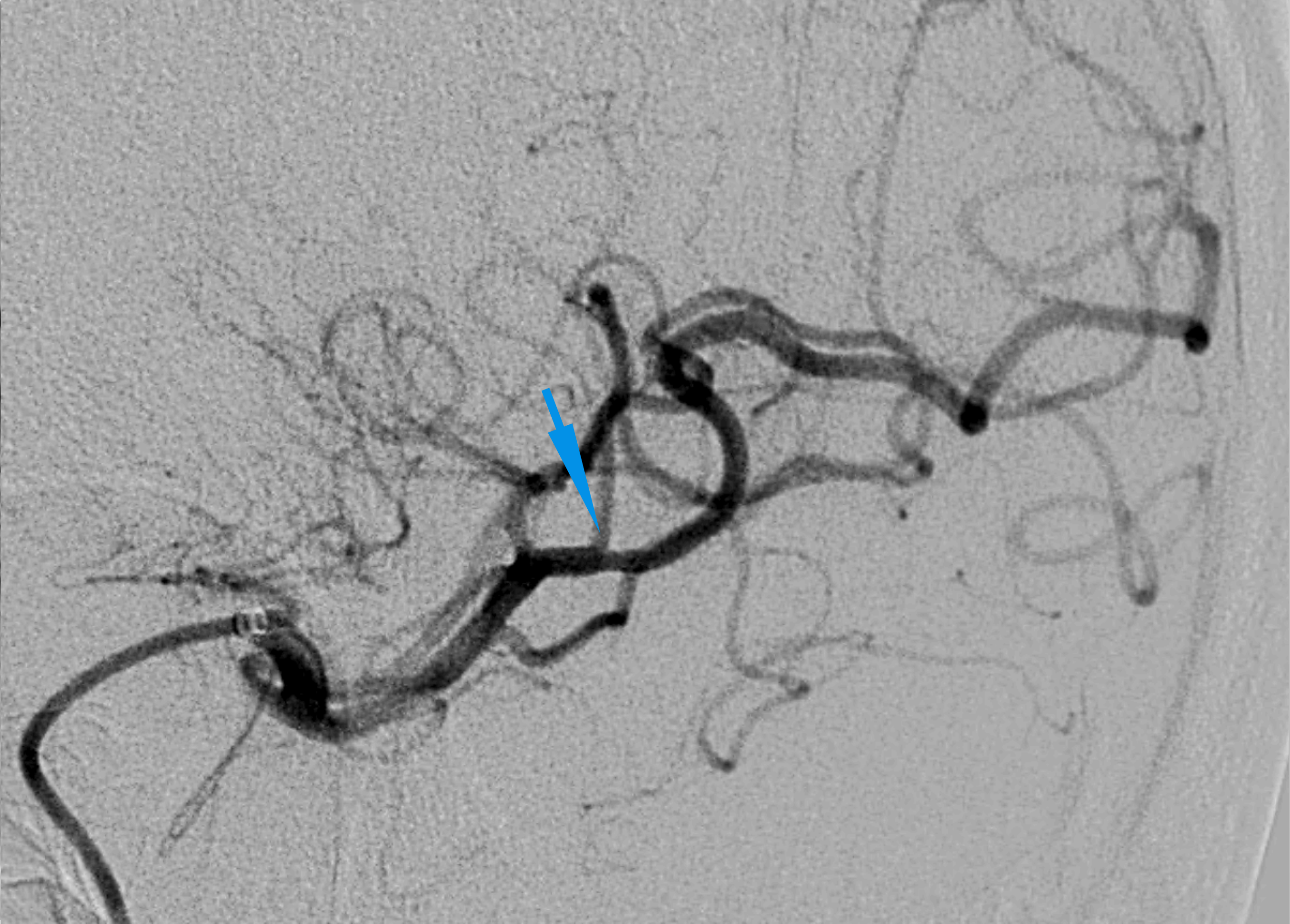
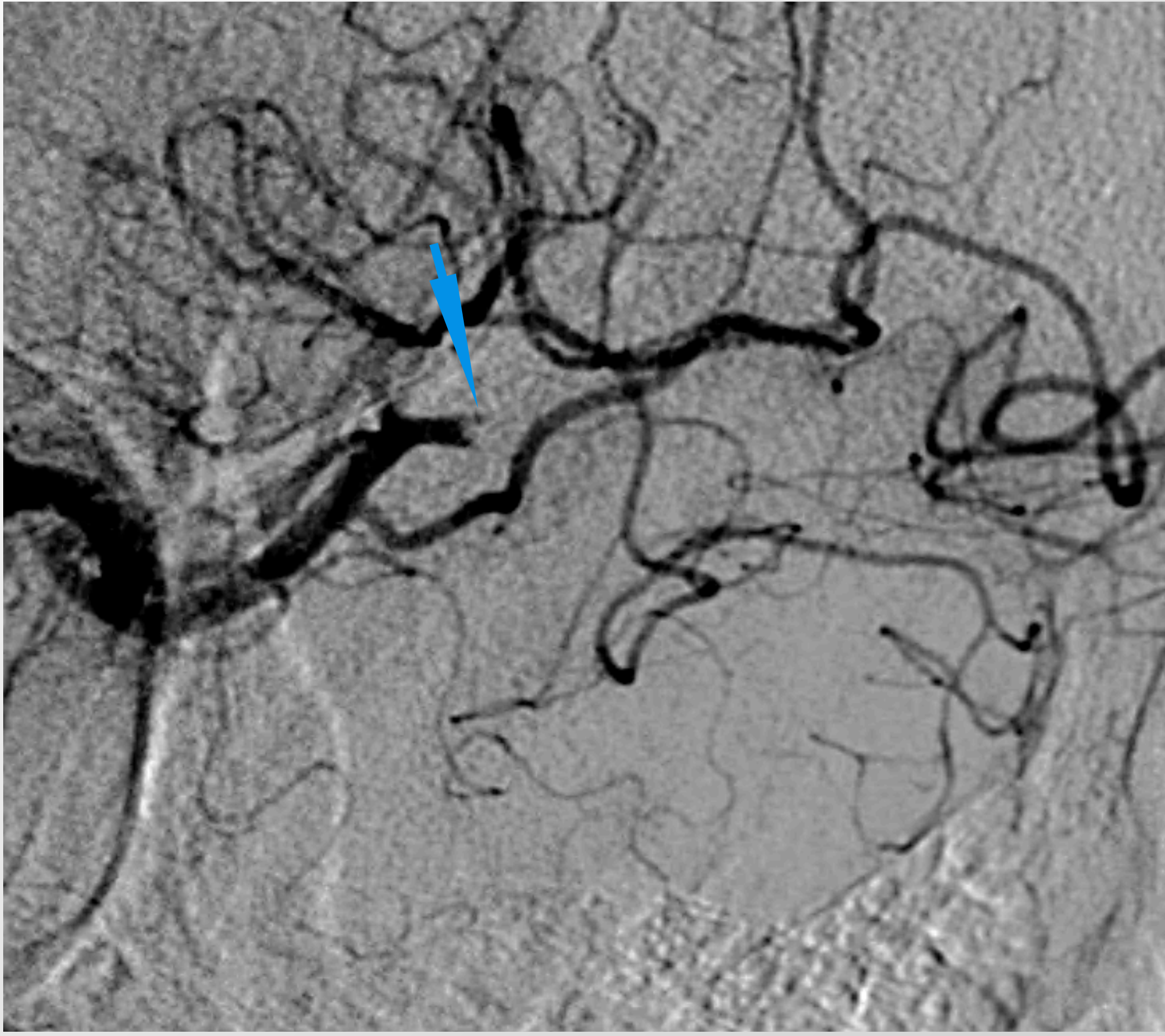

- 62 y/o
- NIHSS 3
- ASPECTS 10

Jun'21



- P-R: 27 min.
- NIHSS 24h: 1
- NIHSS alta: 0



Muchas gracias



pedro.navia@salud.madrid.org

